
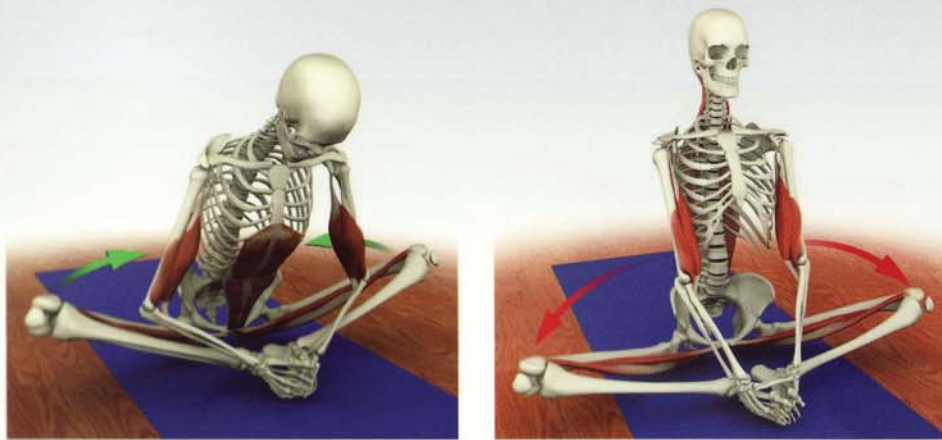


Scientific Keys Volume I

The Key Muscles of Hatha Yoga

Ray Long MD FRCSC

With Illustrator Chris Macivor



Patanjali, the patron saint of yoga, said that mastery combines a balance of science and art. Knowledge of science is like the colors on an artist's palette – the greater the knowledge, the more colors available. The body is the canvas and the asanas are the art we create.

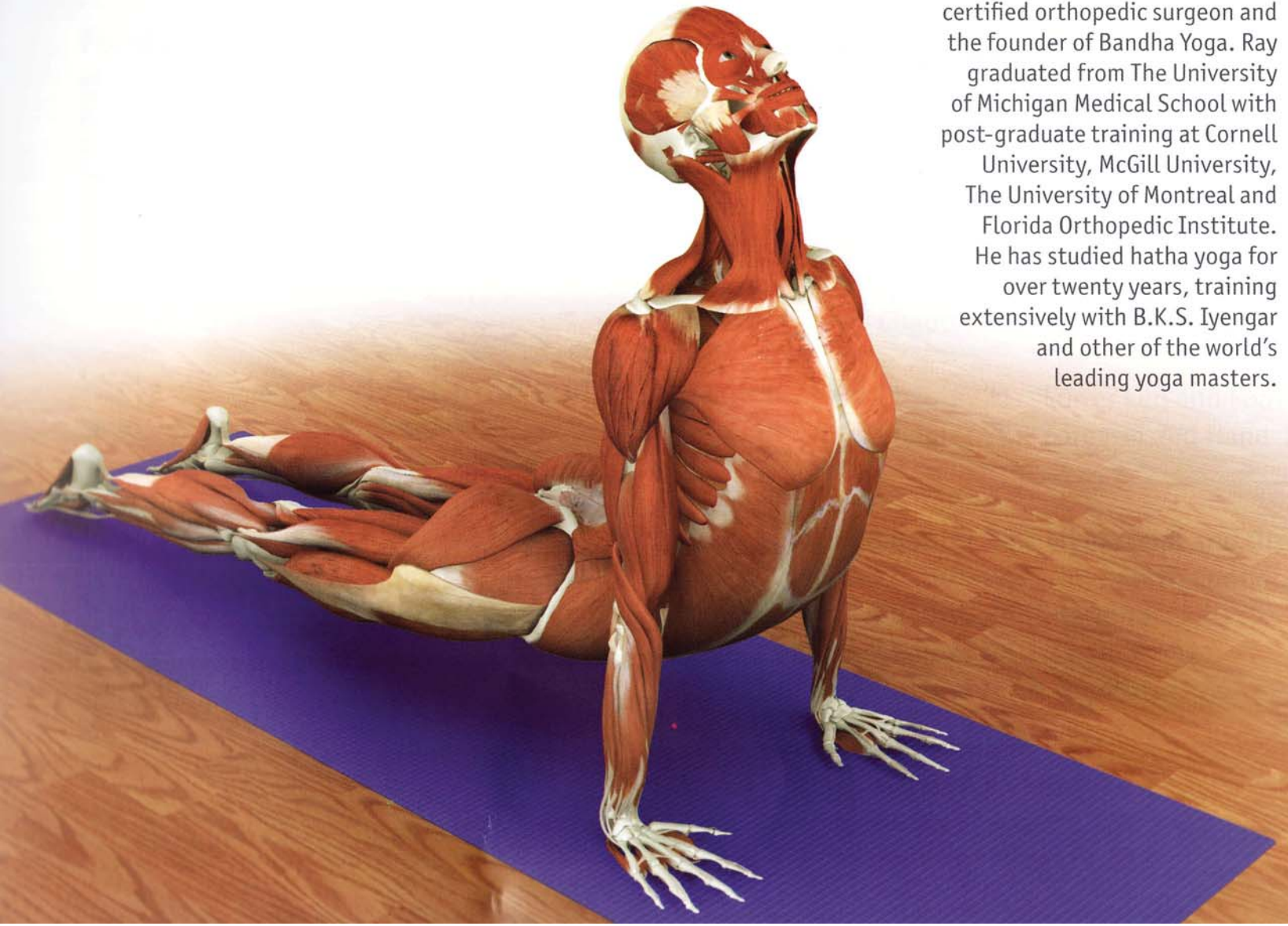
About the Author

Ray Long

Ray Long MD FRCSC is a board certified orthopedic surgeon and the founder of Bandha Yoga. Ray graduated from The University of Michigan Medical School with post-graduate training at Cornell University, McGill University, The University of Montreal and Florida Orthopedic Institute. He has studied hatha yoga for over twenty years, training extensively with B.K.S. Iyengar and other of the world's leading yoga masters.

Chris Macivor

Chris Macivor is a digital illustrator and the visual coordinator of Bandha Yoga. Chris is a graduate of Etobicoke School of The Arts, Sheridan College and Seneca College. His work has spanned many genres from TV and film to videogames and underwater videography.



Contents

Introduction 7

Fundamentals 8

Locations on the Body 8
Skeleton 10
Joints 22
Ligaments 26
Muscles and Tendons 35
Movement 44

Part One - The Pelvic Girdle and Thighs 49

Chapter 1: Iliopsoas 57
Chapter 2: Gluteus Maximus 64
Chapter 3: Gluteus Medius 69
Chapter 4: Tensor Fascia Lata 74
Chapter 5a: Pectineus 79
Chapter 5b: Adductor Magnus 84
Chapter 6: External Rotators 91
Chapter 7: Quadriceps 96
Chapter 8: Hamstrings 103

Part Two - The Trunk 113

Chapter 9: Abdominals 118
Chapter 10: Back Muscles 128
Chapter 11: Latissimus Dorsi 135
Chapter 12: Trapezius 139
Chapter 13: Pectoralis Major & Minor 144

Part Three - The Shoulder Girdle and Upper Arms 151

Chapter 14: Rhomboids 157
Chapter 15: Serratus Anterior 162
Chapter 16: Deltoids 167
Chapter 17: Rotator Cuff 174
Chapter 18: Biceps Brachii 185
Chapter 19: Triceps Brachii 190
Chapter 20: Sternocleidomastoid 197

Chapter 21: Lower Leg and Foot 202
Chapter 22: Forearm and Hand 206

Chapter 23: Myofascial and Organ Planes 210
Chapter 24: The Breath Connection 212
Chapter 25: Bandhas 220
Chapter 26: Chakras 222
Putting It All Together 224

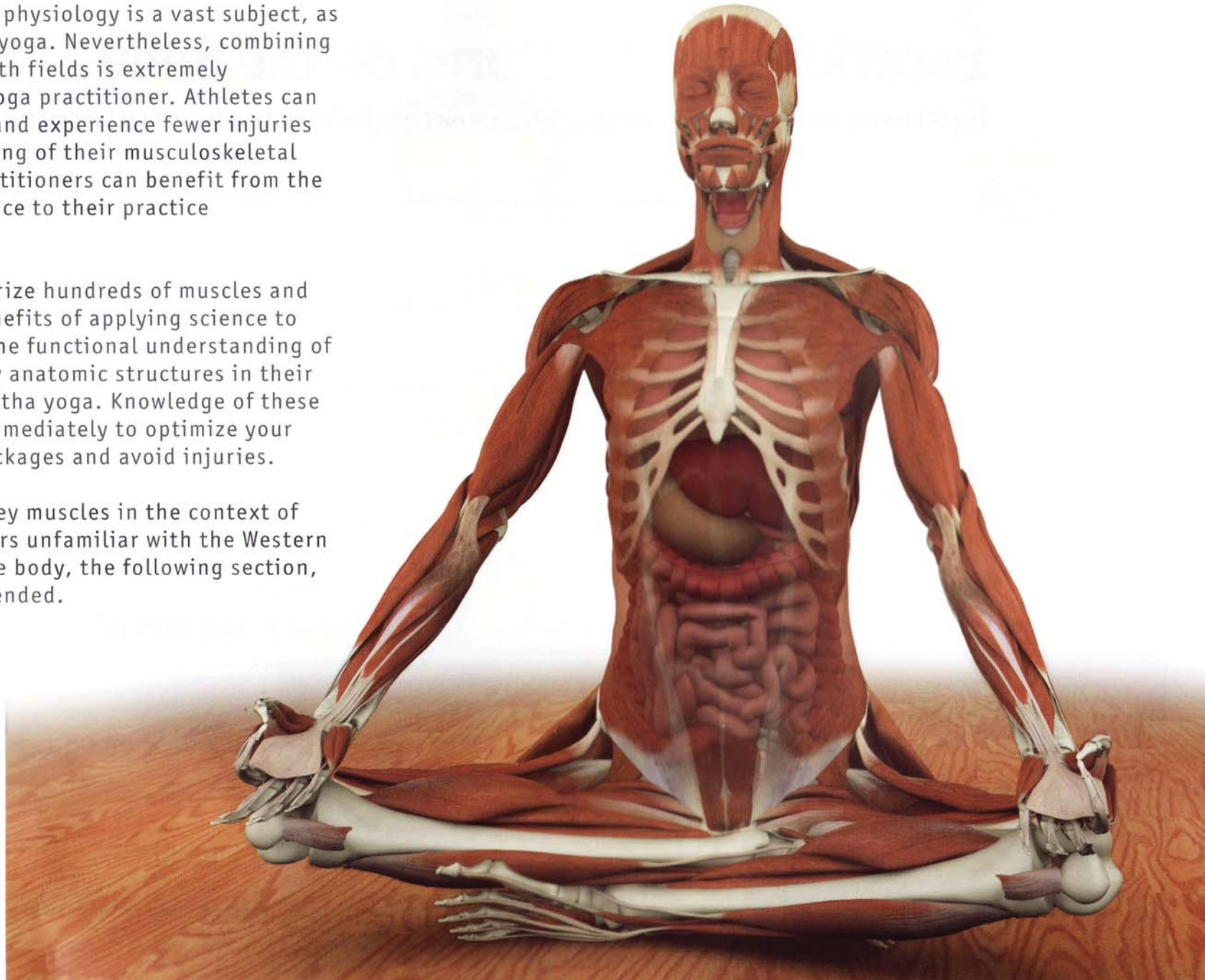
Appendix of Asanas 230
Index of Asanas 236
Index of Muscles 238

Introduction

Human anatomy and physiology is a vast subject, as is the art of hatha yoga. Nevertheless, combining knowledge from both fields is extremely beneficial to the yoga practitioner. Athletes can improve their performance and experience fewer injuries through a basic understanding of their musculoskeletal system. Similarly, yoga practitioners can benefit from the application of Western science to their practice development.

It is not necessary to memorize hundreds of muscles and bones to experience the benefits of applying science to yoga. What is necessary is the functional understanding of a manageable number of key anatomic structures in their settings as they relate to hatha yoga. Knowledge of these structures can be applied immediately to optimize your practice, break through blockages and avoid injuries.

This first volume presents key muscles in the context of hatha yoga. For practitioners unfamiliar with the Western scientific terminology of the body, the following section, "Fundamentals," is recommended.



Scientific Keys | Volume I

First Edition: Copyright 2005, Raymond A Long MD FRCS
Second Edition: Copyright 2006, Raymond A Long MD FRCS
Third Edition: Copyright 2006, Raymond A Long MD FRCS
Bandha Yoga Publications

All rights reserved

No part of this book may be reproduced, copied or transmitted in any form without the express written permission of the publisher.

Always consult your healthcare provider before practicing yoga or any other exercise program.
Yoga must always be practiced under the supervision of a qualified instructor.

The author assumes no responsibility for injuries that may occur as a result of the practice of yoga.

Design: Ingrid Patricia Sanchez

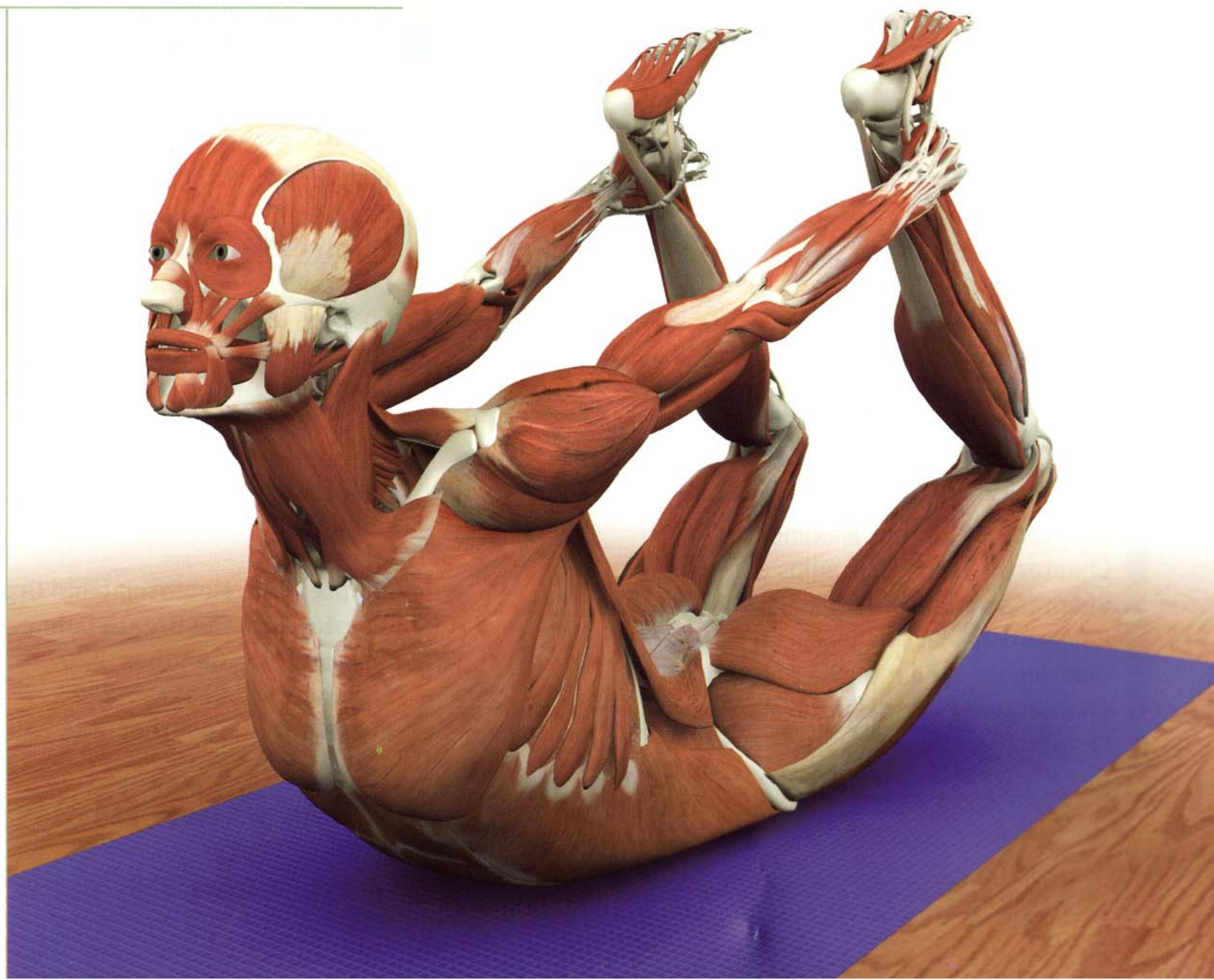
www.BandhaYoga.com

Scientific keys

How to Use This Book

The images in this book are the keys. We present each muscle in the context of its function as an agonist, antagonist or synergist. Note the interrelated views of the muscle in each of its various representations.

Relax and study one muscle at a time. Actively apply what you have learned by visualizing the muscles as you perform the asanas. Consciously contract and relax them, as detailed in the images. This will consolidate your knowledge. Review each studied muscle, first at twenty four hours and then again at one week. In this way you will master the muscles and integrate them into your yoga practice.



Fundamentals

Introduction

Locations of Structures on the Body

The following terms are used to describe where structures lie in relation to certain landmarks on the body.

Medial:
Closer to the midline of the body

Lateral:
Away from the midline

Proximal:
Closer to the trunk or midline

Distal:
Away from the trunk or midline

Superior:
Above or towards the head

Inferior:
Below or away from the head

Anterior:
Towards the front of the body

Posterior:
Towards the back of the body

Ventral:
On the front of the body

Dorsal:
On the back of the body

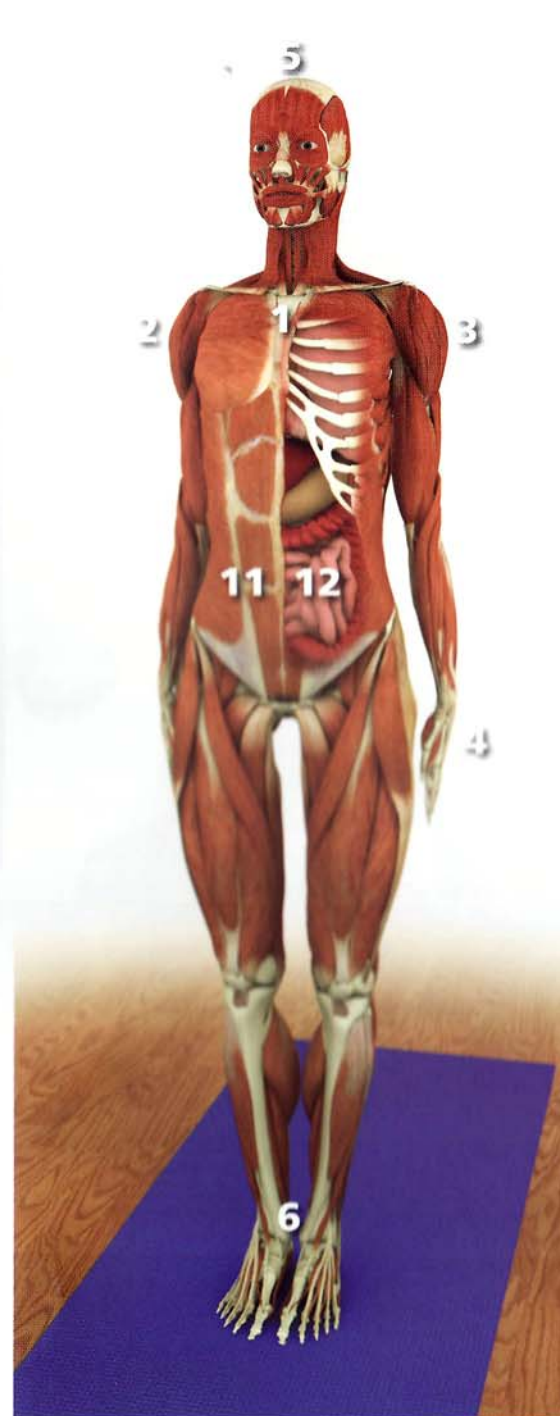Superficial:
Towards the skin

Deep:
Inside the body

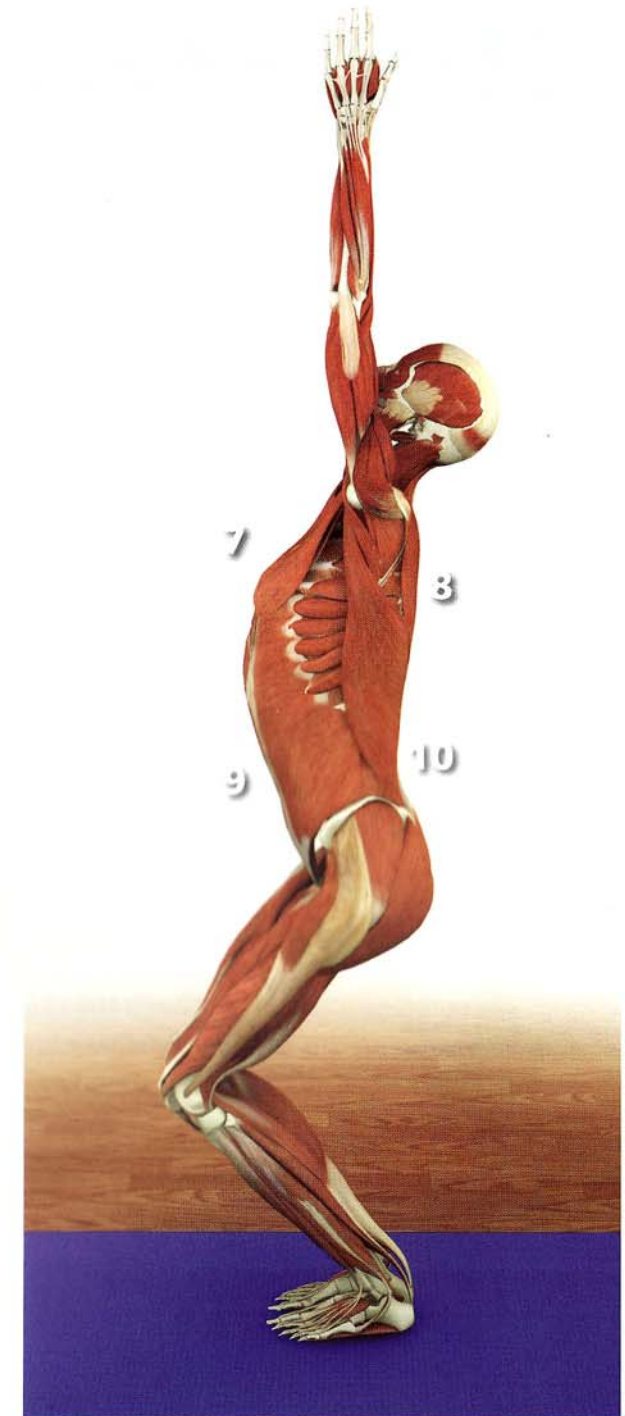
Locations on the Body

These images demonstrate the terminology for identifying body locations in yoga postures. Note that some of the terms are interchangeable. For example, an anterior structure (such as the chest) in *utkatasana* is also ventral.

- 1) The sternum is medial to the shoulder.
- 2) The shoulder is lateral to the sternum.
- 3) The shoulder is proximal.
- 4) The hand is distal.
- 5) The head is superior to the feet.
- 6) The feet are inferior to the head.
- 7) The chest is anterior to the back.
- 8) The back is posterior to the chest.
- 9) The abdomen is ventral.
- 10) The lumbar region is dorsal.
- 11) The abdominal muscles are superficial.
- 12) The abdominal organs are deep.



tadasana



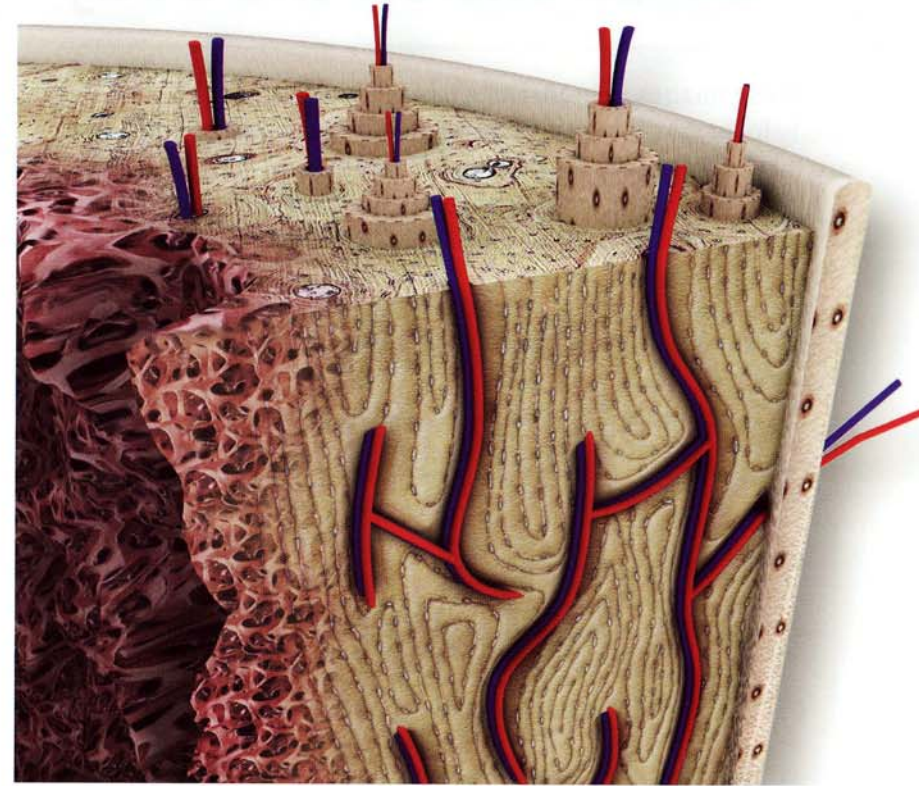
utkatasana

Skeleton

Bone is the dynamic living tissue that forms the body's structural framework. The bones mass is composed of organic and inorganic materials including calcium salts and connective tissue, as well as cells and blood vessels within a calcium matrix. This combination gives bone a tensile strength near that of steel, yet maintains a modicum of elasticity. By aligning the direction of the force of gravity along the major axis of the bones, we can access this strength in yoga postures.

Regular practice of yoga is beneficial for your bones because healthy stresses are applied in a variety of unusual directions. This strengthens bones, which remodel in response to stress by depositing layers of calcium into the bone matrix. Like a physiological yin/yang, lack of healthy stress on bones weakens them.

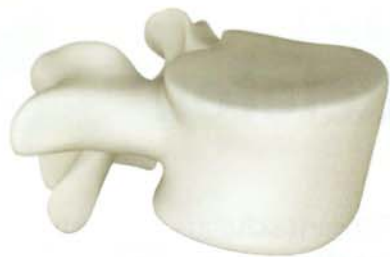Bones are also the body's reservoir for calcium, critical in a variety of physiological functions including muscle contraction. The concentration of calcium in the body is tightly regulated through a complex interplay between the skeletal, endocrine and excretory systems. This involves feedback loops between the parathyroid gland, the kidneys, the intestines, the skin, the liver and the bones.



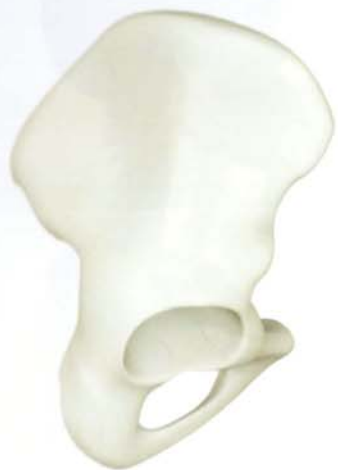living bone

Bone mass decreases in osteoporosis. This age related decrease is associated with the loss of estrogen in post-menopausal women. Studies have demonstrated that resistance type exercise maintains bone mass. Accordingly, it is reasonable to conclude that the various healthy stresses that yoga practice applies across the bones may aid preventing osteoporosis.

The bones of the skeleton link together at the joints and act as levers for the muscles that cross the joints. Consciously contracting and relaxing these skeletal muscles moves the body into the various yoga postures.



vertebral body



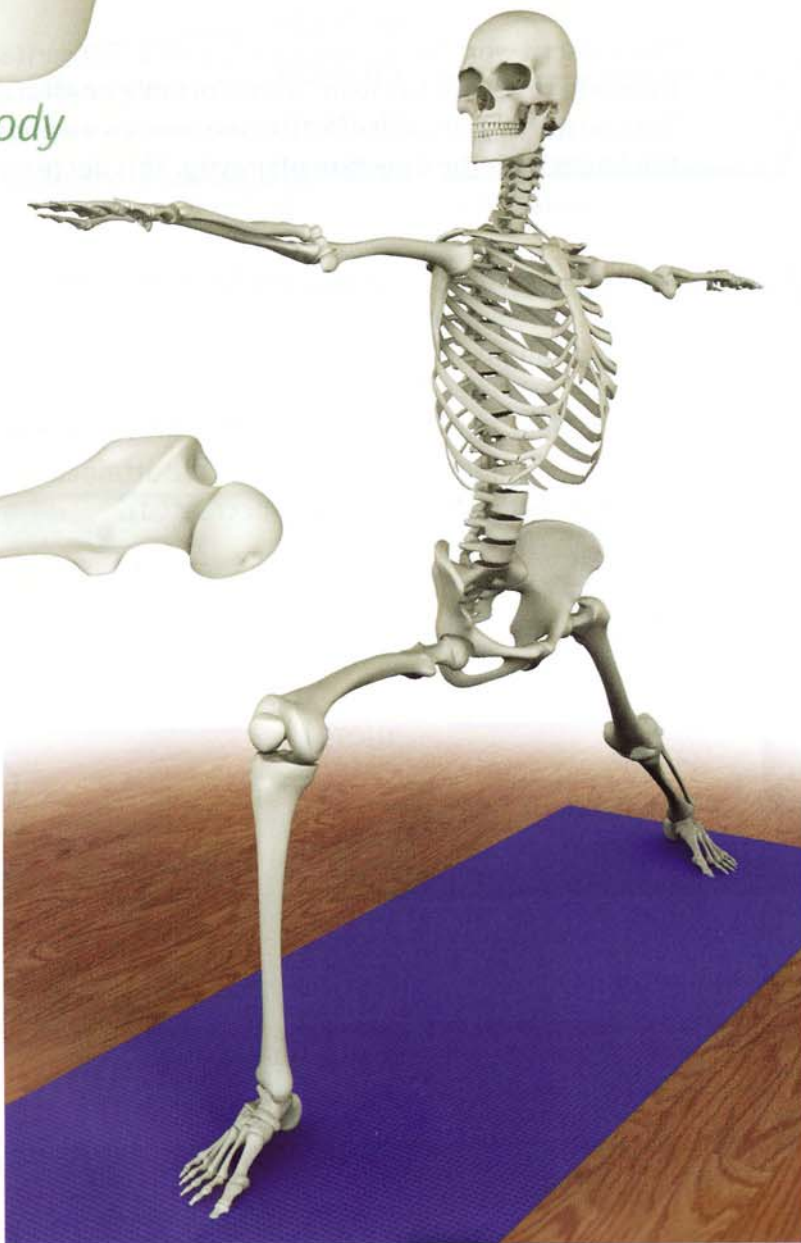
ilium



femur



calcaneus



virabhadrasana II

Shapes of bones

The form or shape of a bone reflects its function. Long bones provide leverage, flat bones provide protection and a place for broad muscles to attach, and short bones provide for weight bearing functions.

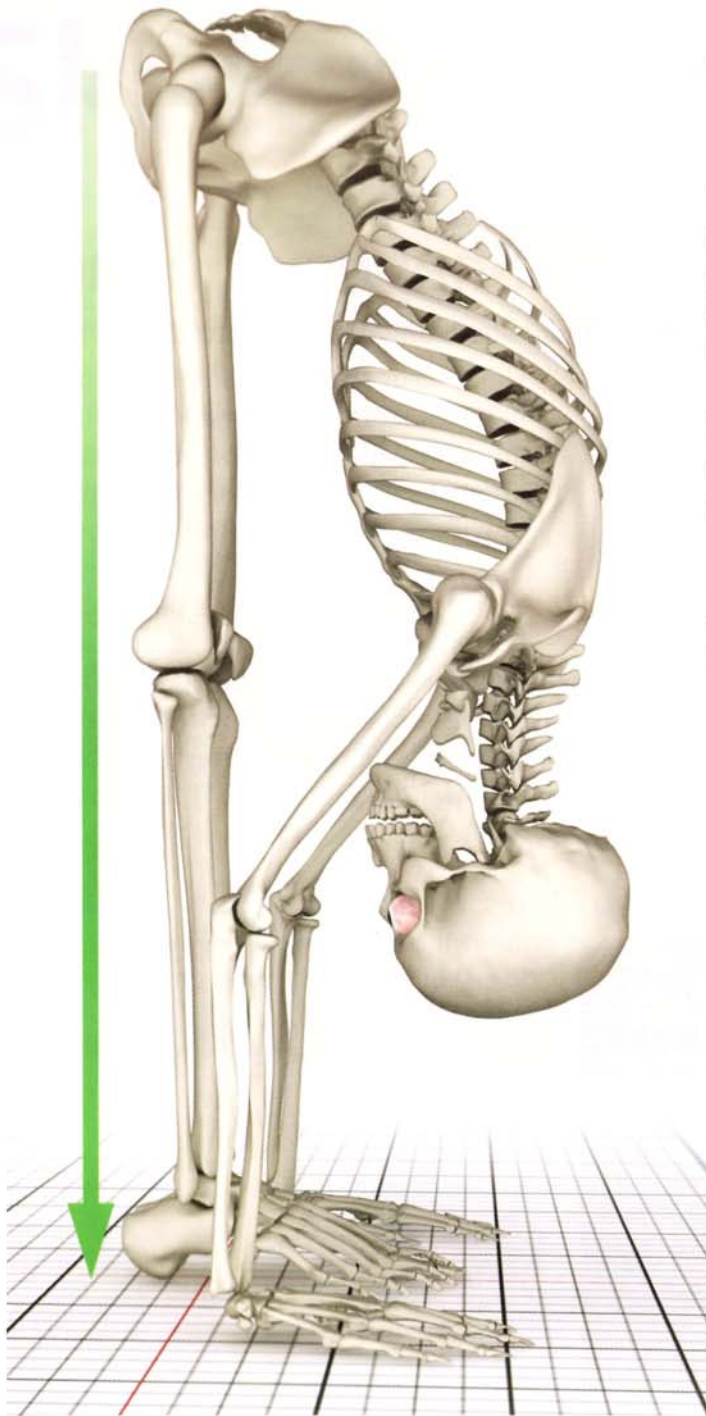
Yoga accesses each bone's particular potential, using long bones to leverage the body deeper into postures, the flat bones (and their accompanying core muscles) for stability, and the short vertebral bodies to bear weight. Examples of these bones are illustrated here.

Gravity and the Skeleton

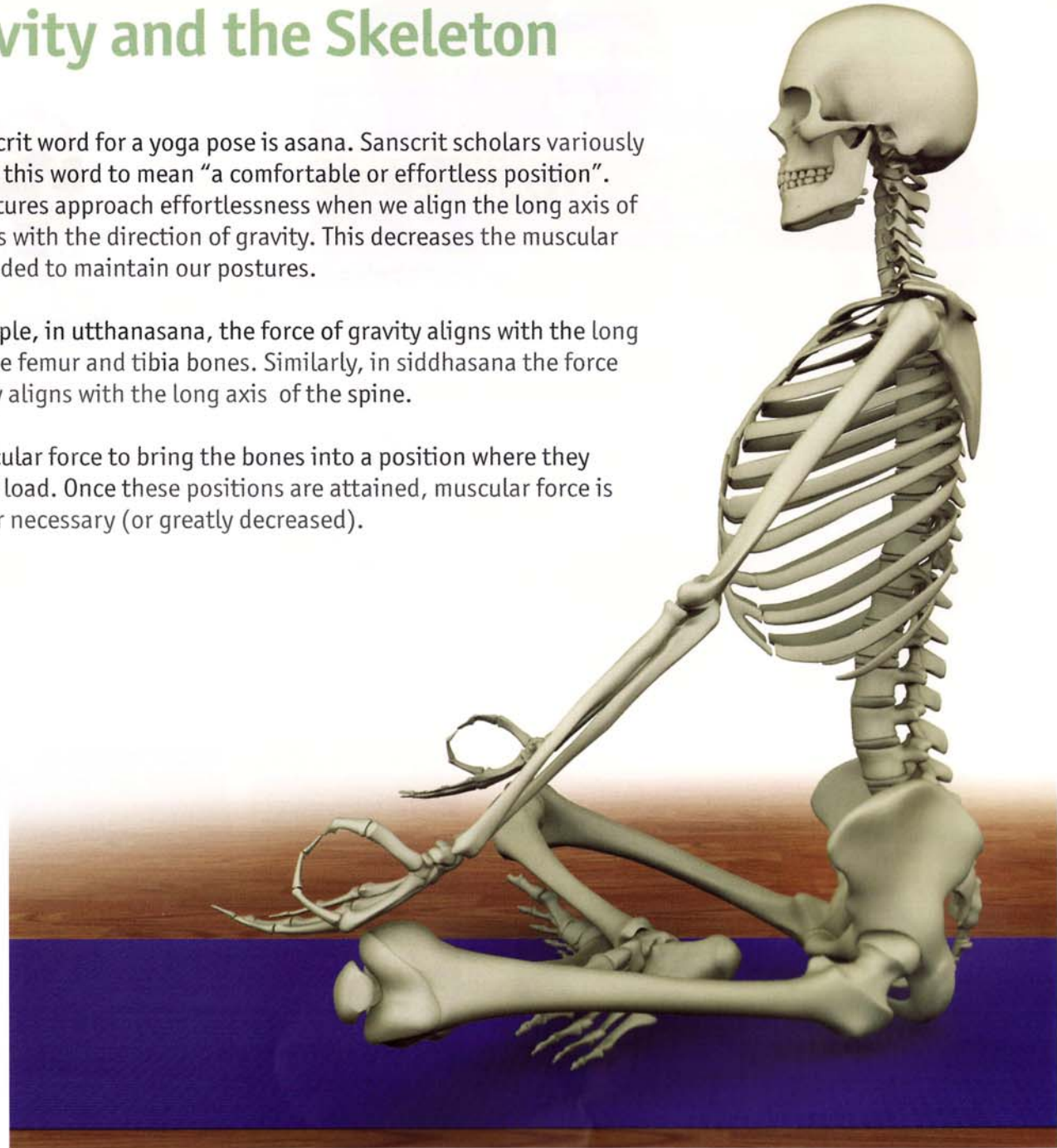
The Sanscrit word for a yoga pose is asana. Sanscrit scholars variously translate this word to mean “a comfortable or effortless position”. Yoga postures approach effortlessness when we align the long axis of the bones with the direction of gravity. This decreases the muscular force needed to maintain our postures.

For example, in *utthanasana*, the force of gravity aligns with the long axis of the femur and tibia bones. Similarly, in *siddhasana* the force of gravity aligns with the long axis of the spine.

Use muscular force to bring the bones into a position where they carry the load. Once these positions are attained, muscular force is no longer necessary (or greatly decreased).

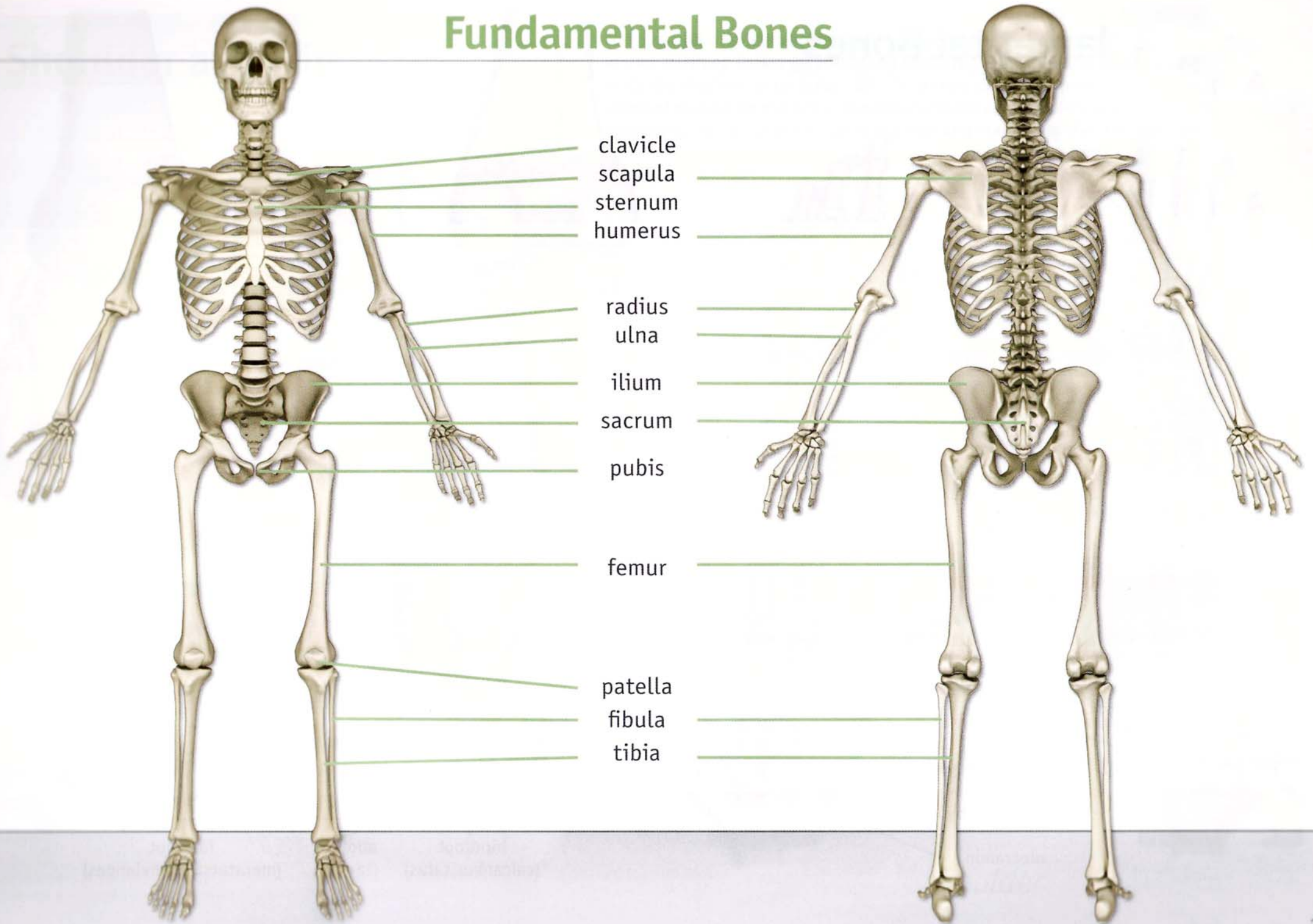


utthanasana

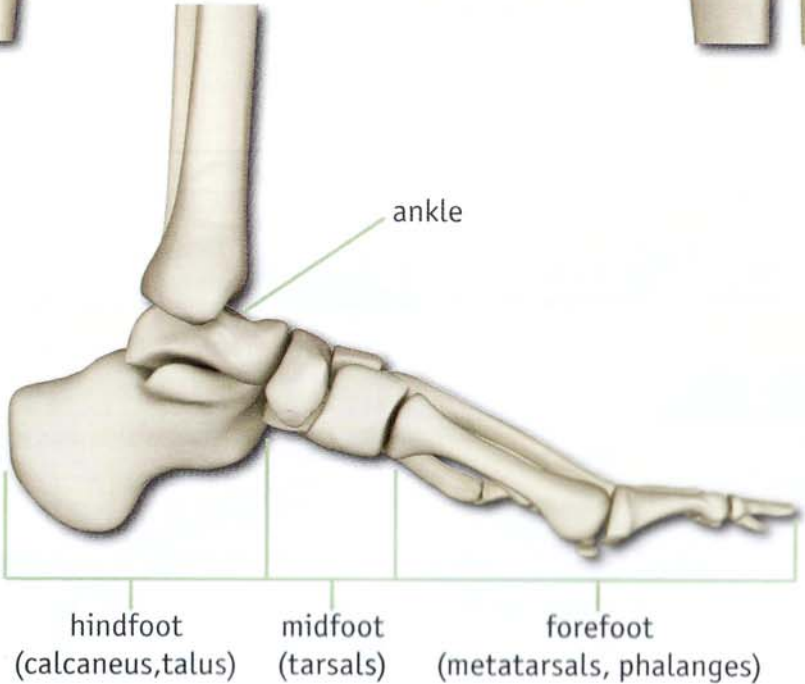
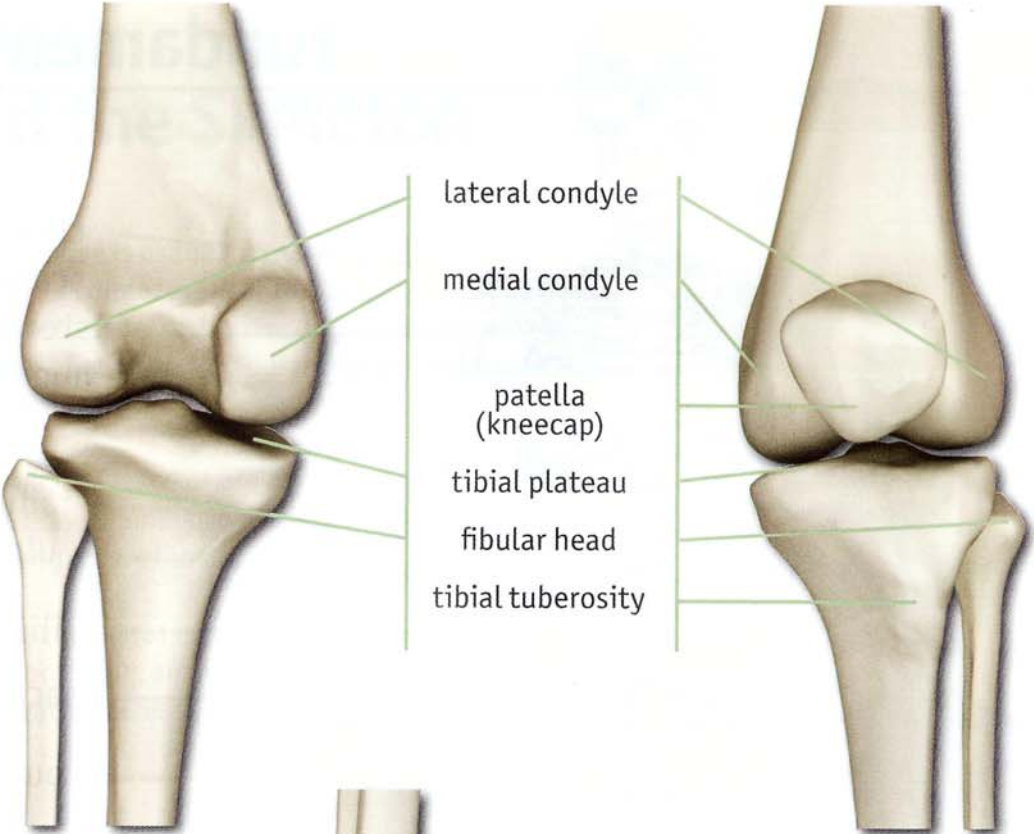
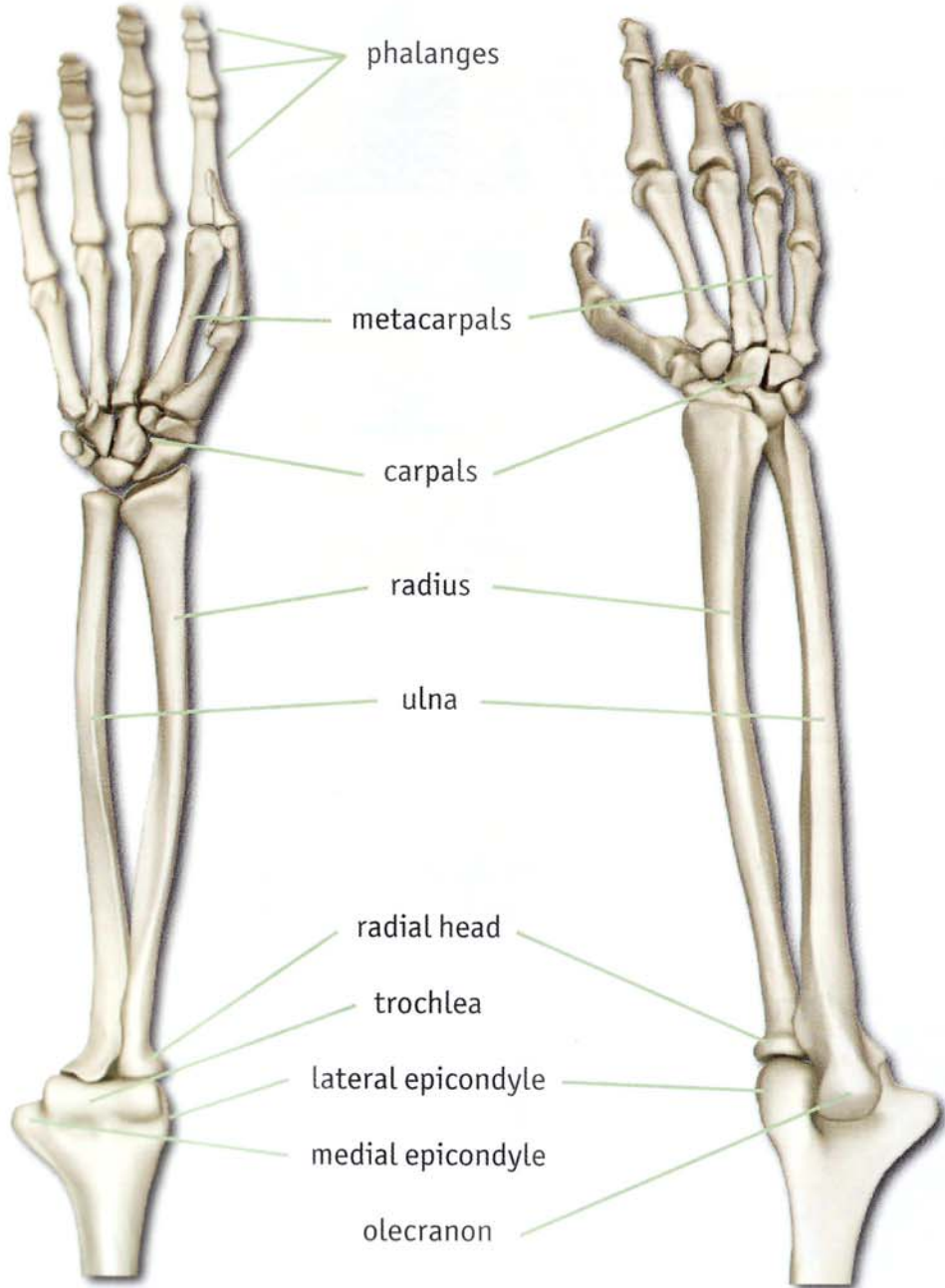


siddhasana

Fundamental Bones

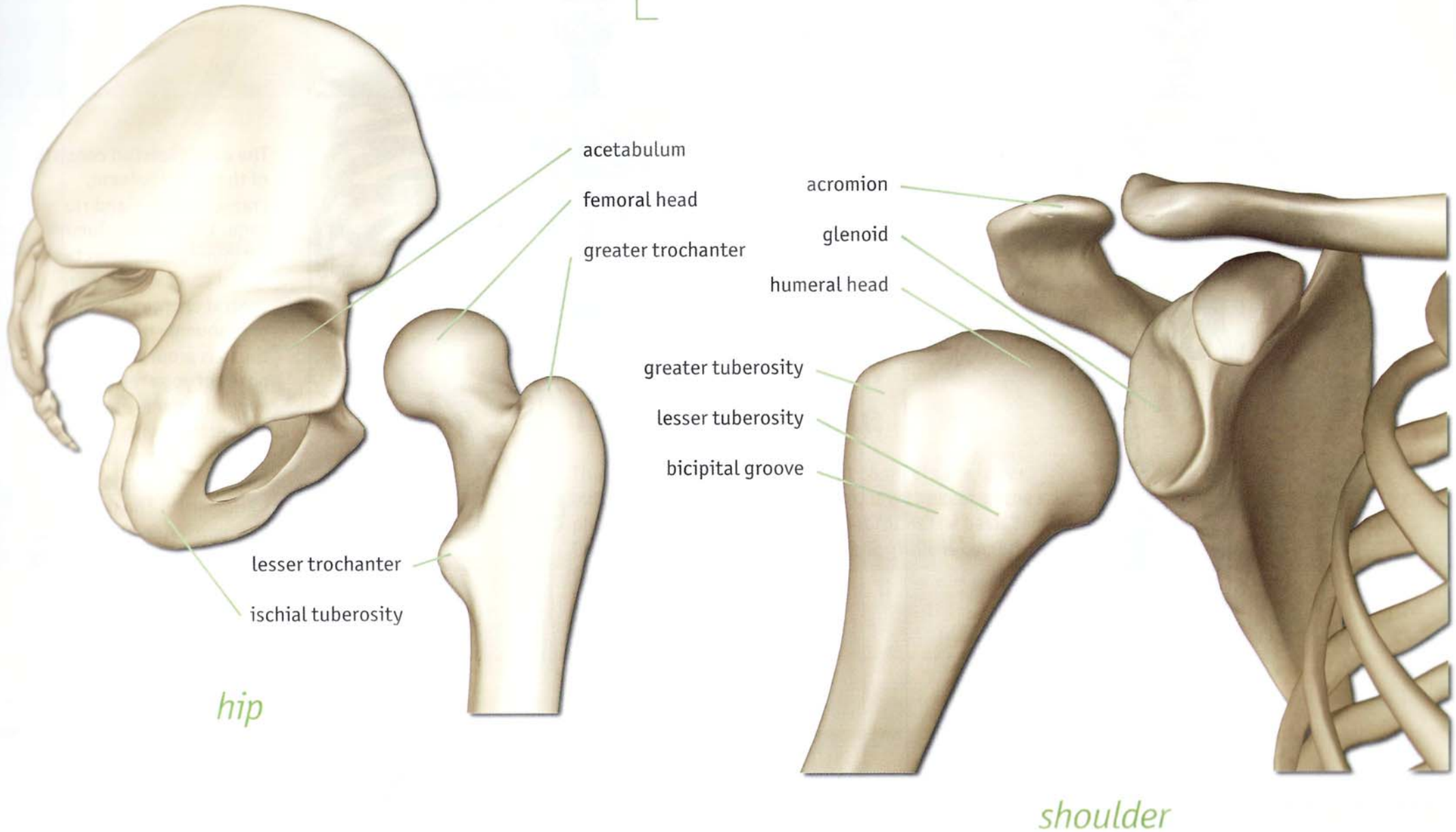


Fundamental Bones

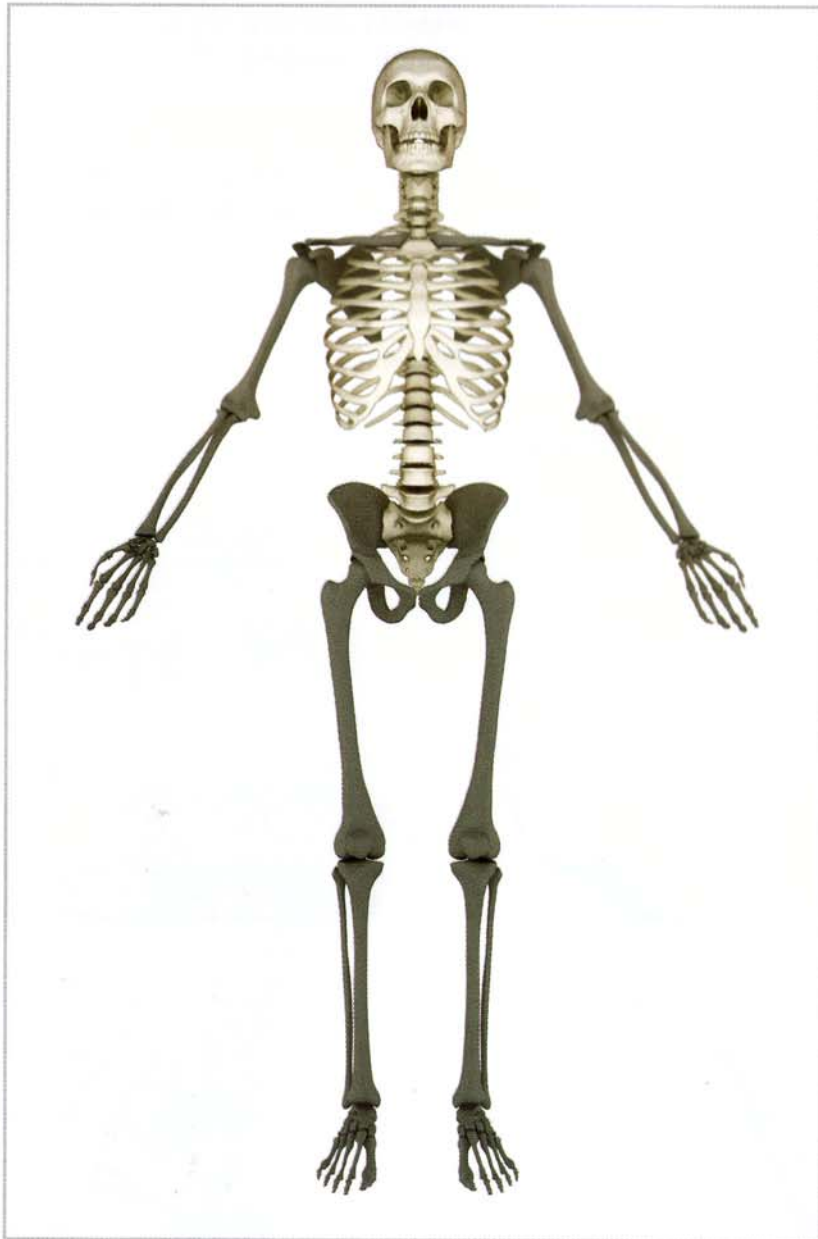

Shoulder and Hip

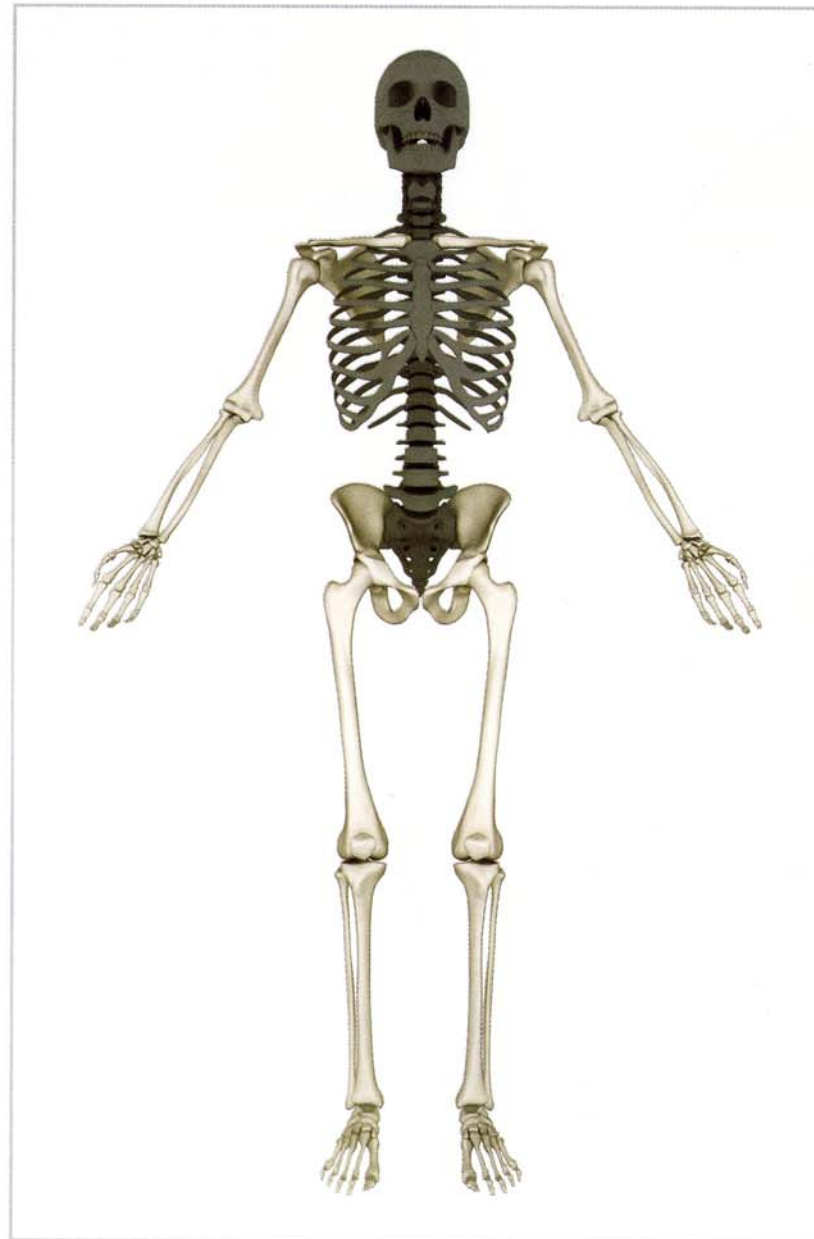The hips and shoulders are ball and socket joints. Their form reflects their function in that the deep socket (acetabulum) of the hip is designed to support weight while the shallow socket (glenoid) of the shoulder is designed to provide maximum range of motion for the arms. Yoga postures balance mobility and stability by increasing the range of motion of the hips and stabilizing the shoulder.



The Axial and Appendicular Skeleton

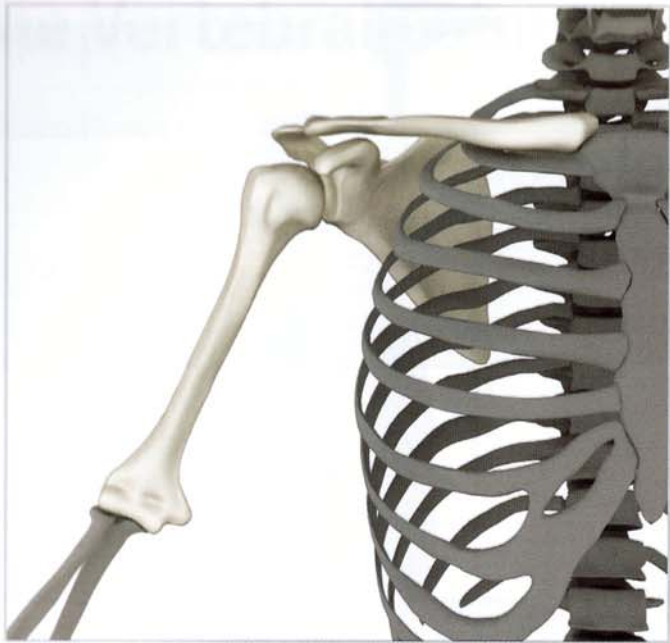

axial skeleton



appendicular skeleton

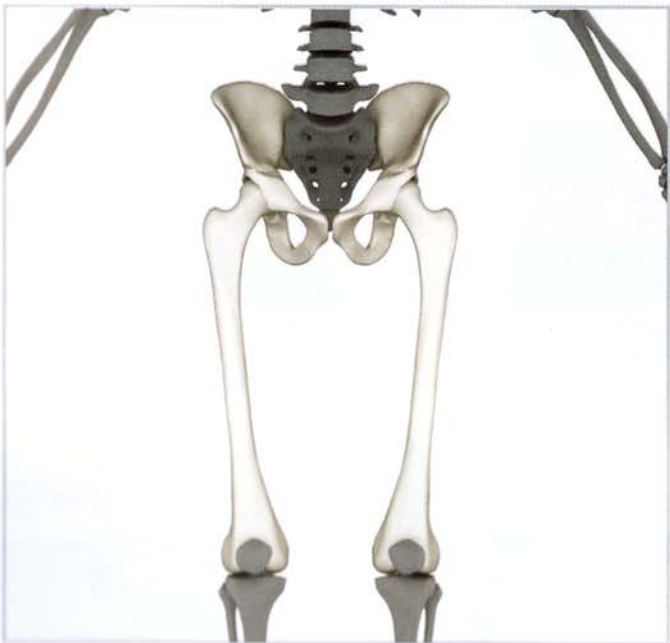The axial skeleton consists of the spinal column, cranium (skull), and rib cage. The spinal column surrounds and protects the spinal cord, which is the central energy channel, or sushumna nadi. It is the axis around which the poses of yoga revolve. The appendicular skeleton connects us with the world. The lower extremities form our connection to the earth. The upper extremities, in association with our senses, connect us with each other.



The Shoulder Girdle

The shoulder girdle is the yoke that connects the upper extremities with the axial skeleton. It is the seat of the brachial plexus, a collection of nerves that in association with the heart forms the basis for the fourth and fifth chakras. The shoulder girdle is comprised of the following structures:

- Scapula (shoulder blade)
- Scapulothoracic joint
- Clavicle
- Sternoclavicular and Acromioclavicular joints
- Humerus (upper-arm bone)
- Glenohumeral joint



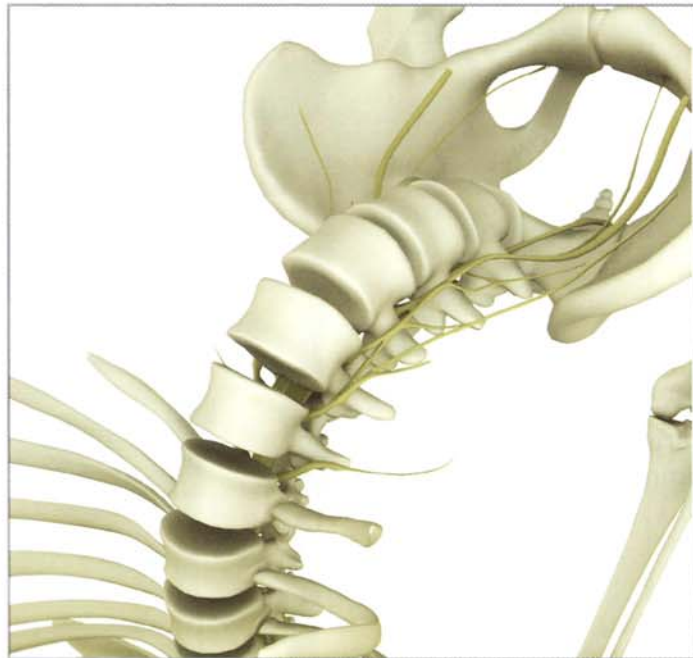
The Pelvic Girdle

The pelvic girdle is the yoke that connects the lower extremities to the axial skeleton. It is the seat of the sacral plexus, a collection of nerves that forms the basis for the first and second chakras. The pelvic girdle is comprised of the following structures:


- Iliac bones
- Sacroiliac joint
- Femur (thigh bone)
- Hip joint

Connecting the Appendicular and Axial Skeleton

Eka pada viparita dandasana demonstrates connecting the upper and lower appendicular skeletons to create movement in the axial skeleton. Note the inset image demonstrating stimulation of the spinal nerves in this back bend.

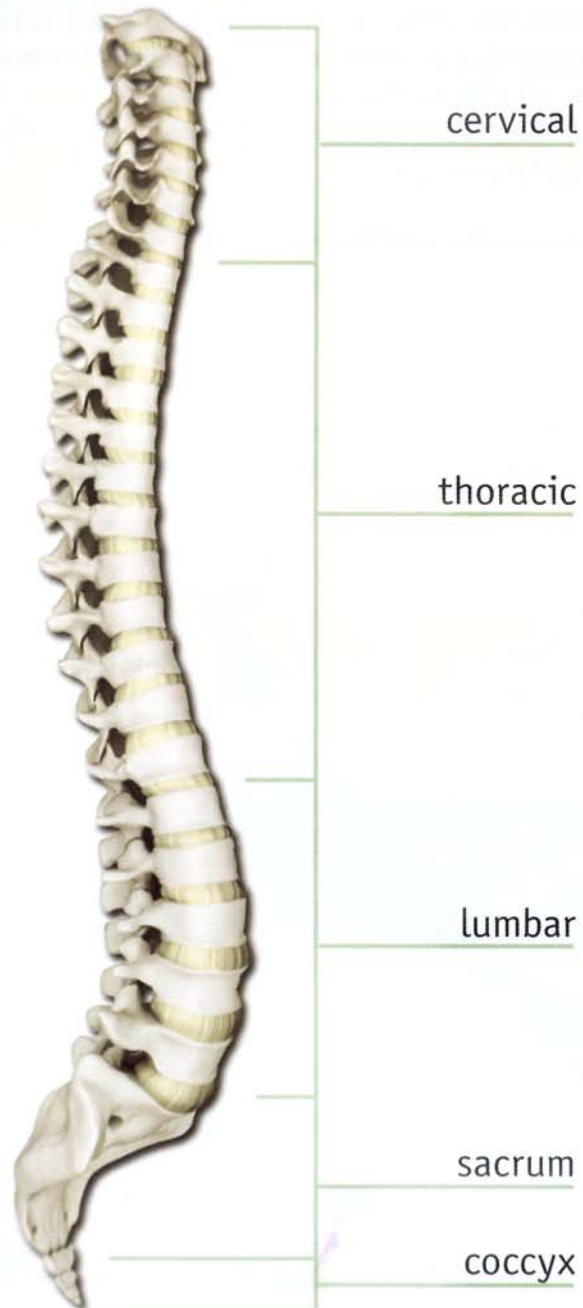


nerve roots in back bend



eka pada viparita dandasana

The Vertebral Column

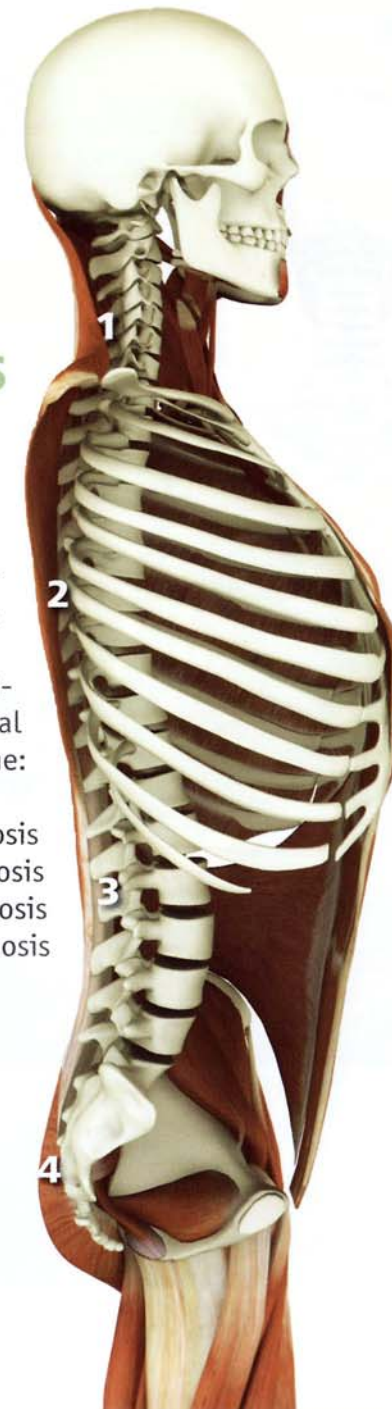


Spinal Curves

We determine the spinal curves by viewing them from the side. Kyphosis is a convex curve and lordosis is a concave curve.

This illustration demonstrates the four normal curves in the spine:

- 1) cervical lordosis
- 2) thoracic kyphosis
- 3) lumbar lordosis
- 4) sacral kyphosis



tadasana

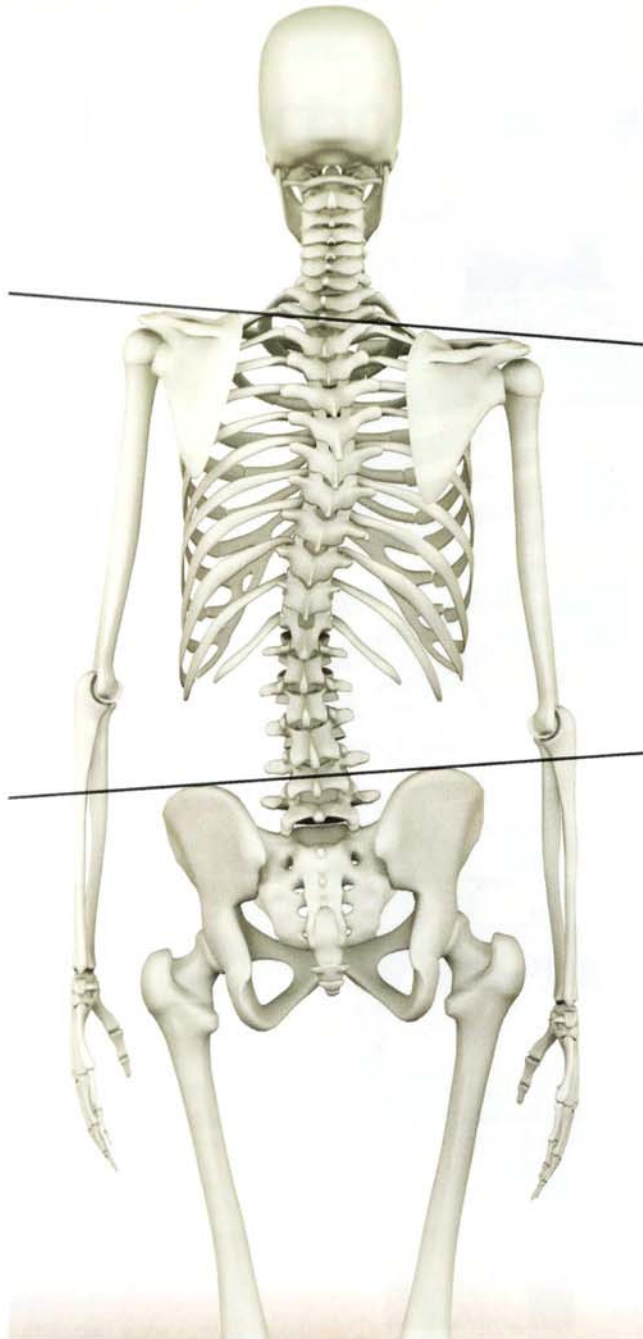
Scoliosis

Scoliosis is a lateral deviation and rotational deformity of the spine. The most common form of scoliosis is called “idiopathic”, meaning without an identifiable cause. Other forms include congenital and neuromuscular scoliosis. Studies have suggested that idiopathic scoliosis is related to hormonal factors including the level of melatonin produced. This form of scoliosis also has a hereditary component.

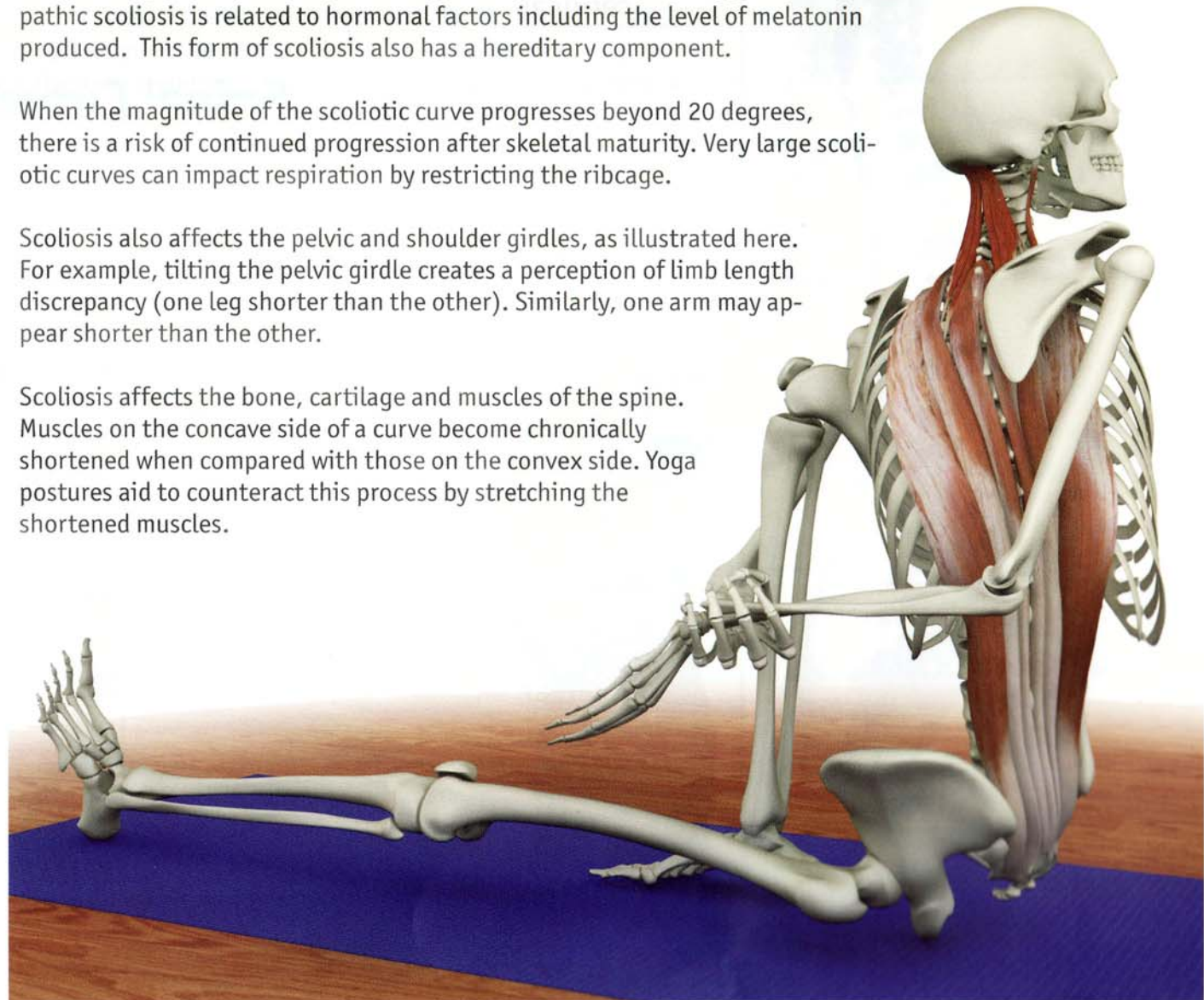
When the magnitude of the scoliotic curve progresses beyond 20 degrees, there is a risk of continued progression after skeletal maturity. Very large scoliotic curves can impact respiration by restricting the ribcage.

Scoliosis also affects the pelvic and shoulder girdles, as illustrated here. For example, tilting the pelvic girdle creates a perception of limb length discrepancy (one leg shorter than the other). Similarly, one arm may appear shorter than the other.

Scoliosis affects the bone, cartilage and muscles of the spine. Muscles on the concave side of a curve become chronically shortened when compared with those on the convex side. Yoga postures aid to counteract this process by stretching the shortened muscles.



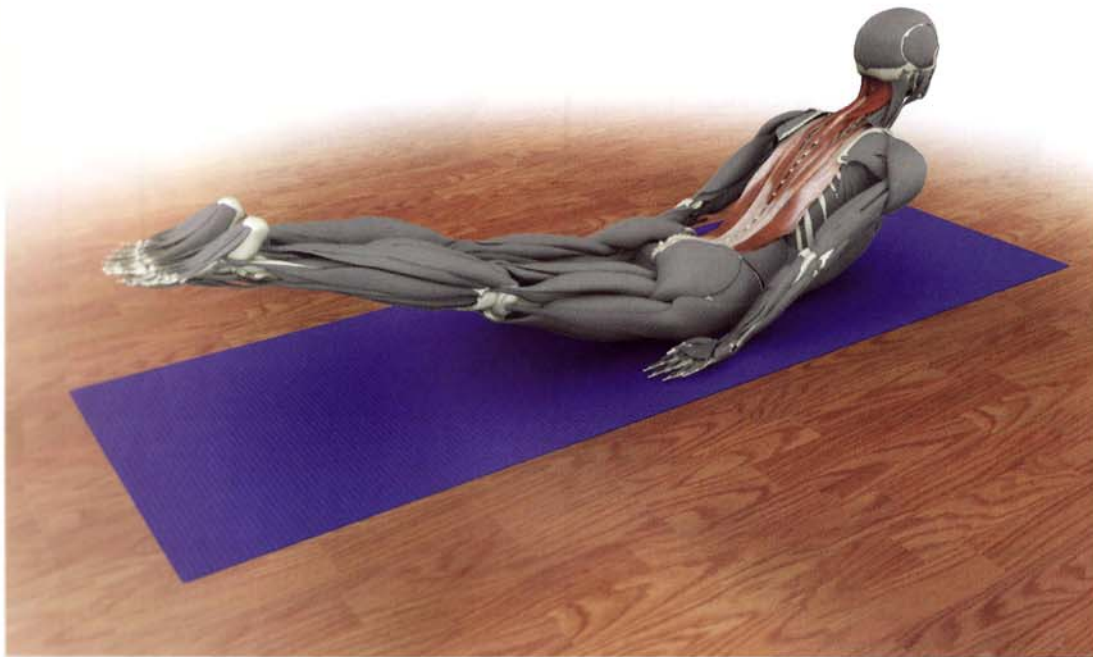
scoliosis



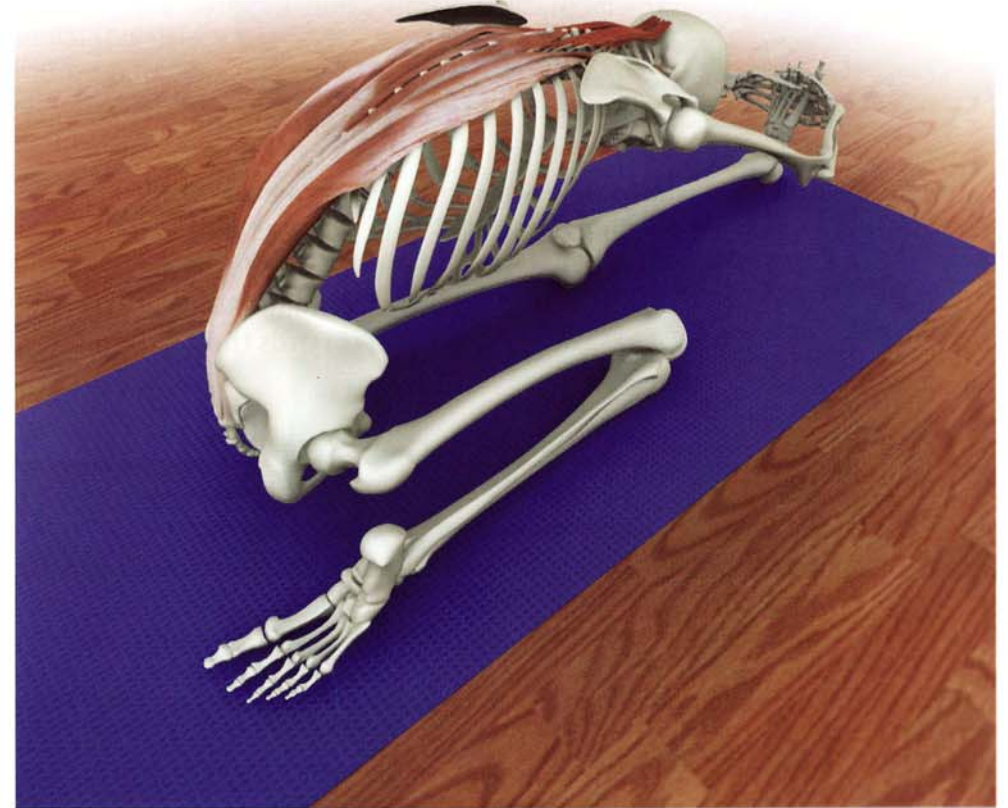
marichyasana

Yoga as therapy

These images of a twist, back bend and forward bend demonstrate how yoga postures contract and stretch the back muscles. This lengthens chronically shortened muscles on the concave side of the scoliotic curve while strengthening them on the convex side. This assists in **balancing** perceived discrepancies in limb length and may also improve nerve conduction.



salabhasana



triang mukhaikapada paschimottanasana

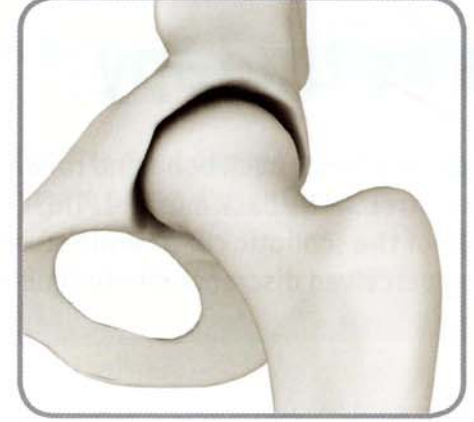Joints

As with the bones, the shape of the joints reflects their function (and their function reflects their shape). Joints come in a spectrum of shapes, depending on the mobility or stability they require. For example, the hip joint is a ball and socket while the knee joint is a hinge. A ball and socket type hip joint confers the greatest mobility in all planes and is useful for activities such as changing direction while walking and running (or reaching in various directions to grasp objects, as with the shoulder). A hinge type knee joint provides greater stability and is useful for propelling the body forward (or drawing an object towards the body, as with the elbow).


Other joints such as the intervertebral between the vertebrae allow for limited mobility between individual vertebrae but great stability to protect the spinal cord. Mobility of the spinal column comes from combining the limited movement of individual intervertebral joints as a whole.



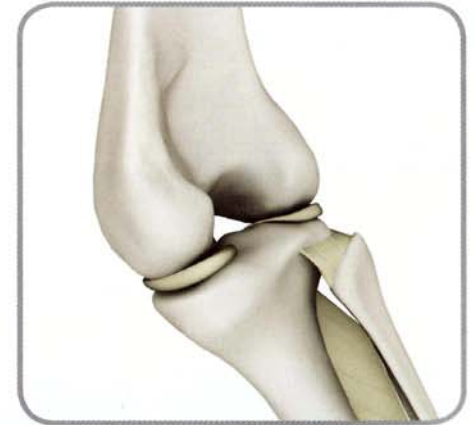ball and socket



hip



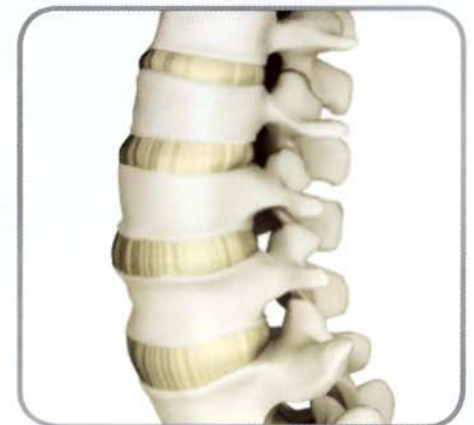hinge



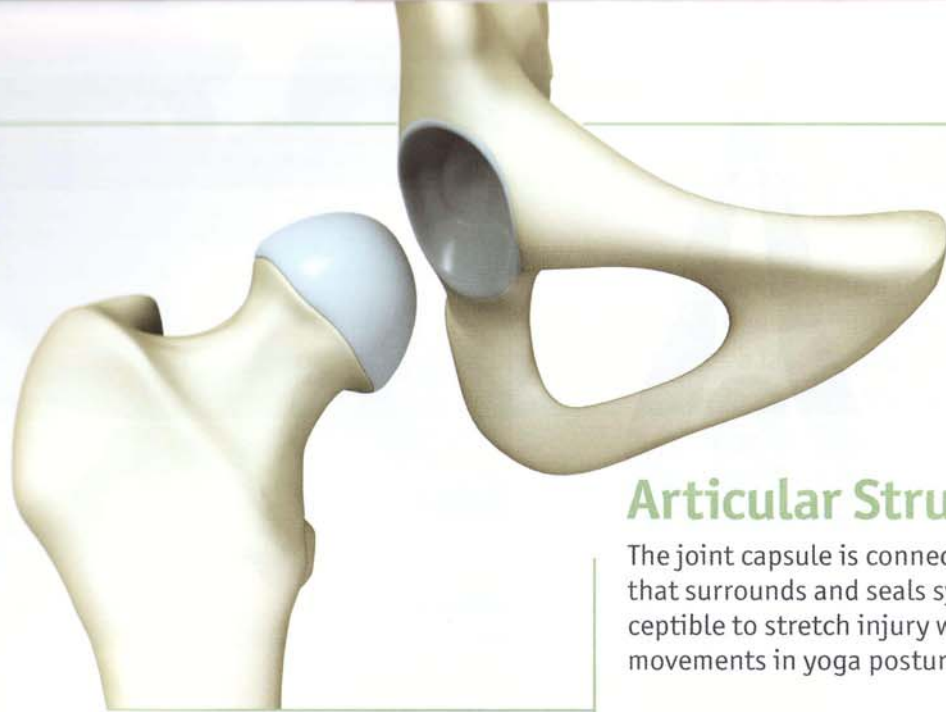
knee



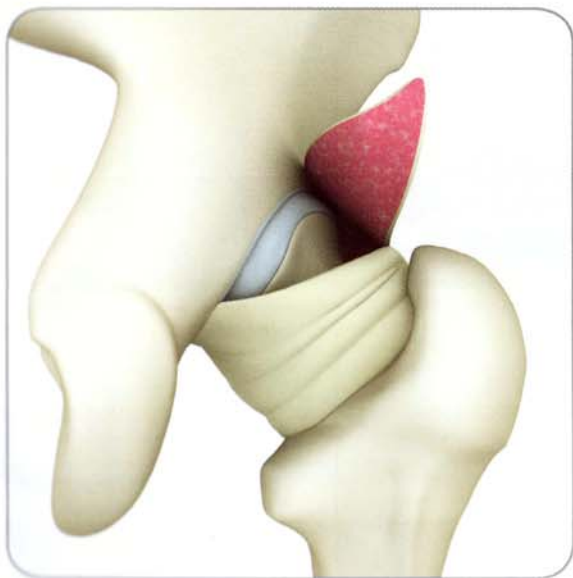compressive



lumbar spine



hip articular cartilage



hip joint capsule with synovium (posterior view)

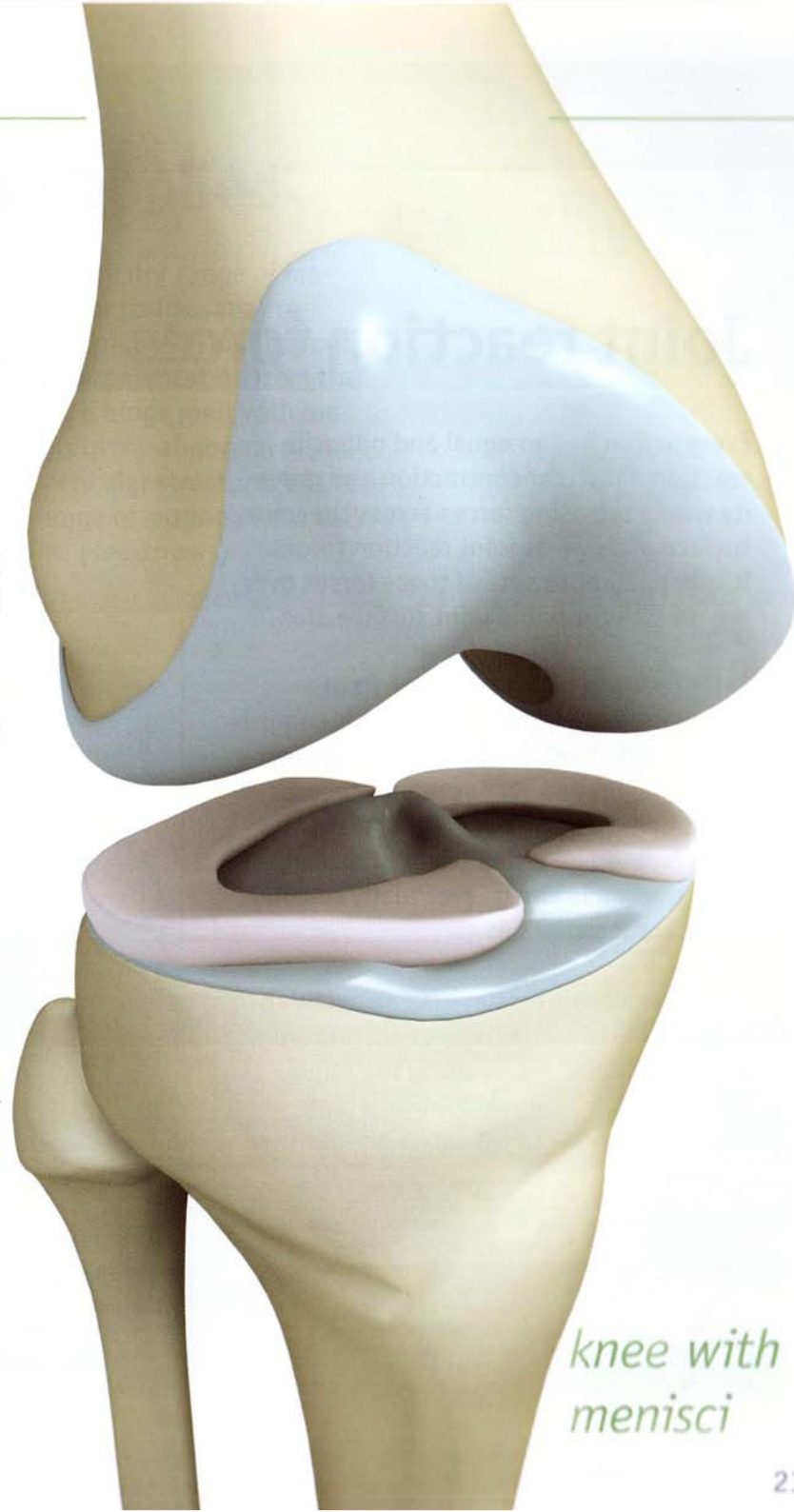
Articular Structure

The joint capsule is connective tissue sheathing that surrounds and seals synovial joints. It is susceptible to stretch injury when executing extreme movements in yoga postures.

Synovial tissue lines the inside of the joint capsule. This tissue produces synovial fluid, a viscous lubricant for the joint surface that decreases friction during joint movement. Synovial fluid circulates throughout the joint, transporting nutrients to the articular cartilage and removing debris from the joint space. The various contortions resulting from yoga postures aid flex and expand the joint capsule, stimulating circulation of synovial fluid.

Articular cartilage covers the joint surfaces, allowing smooth gliding of one bone over the other. In fact, articular cartilage is one of the smoothest surfaces known to man. Applying excessive pressure to this fragile cartilage can injure it, ultimately resulting in arthritis.

The meniscus deepens the articular surface and broadens the contact area of the joint. This aids to stabilize the joint and distributes the force of gravity and muscular contraction over a greater surface area. The meniscus is composed of fibrocartilage, giving it a flexible rubbery consistency.



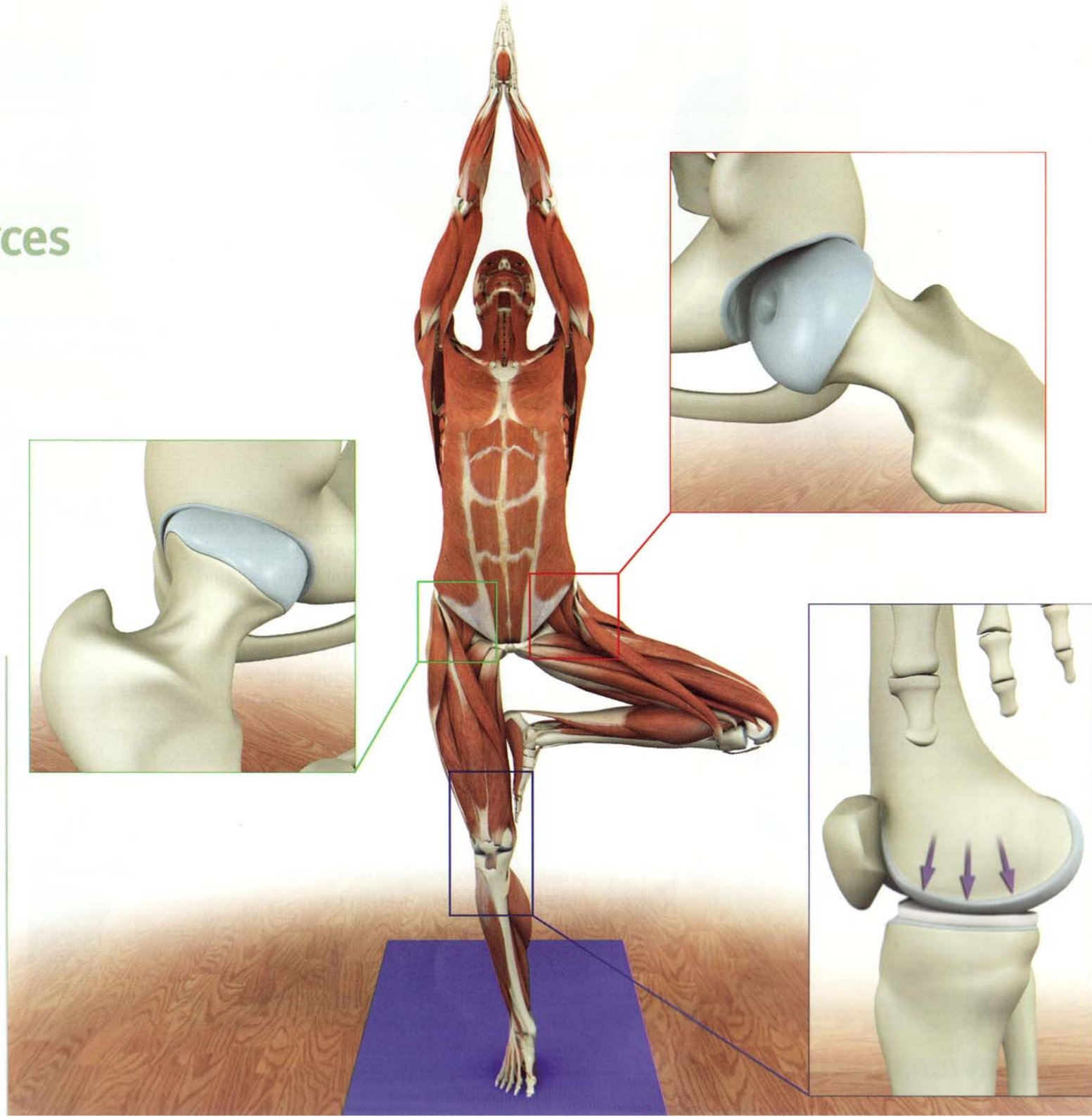
knee with menisci

Joint reaction forces

Every action has an equal and opposite reaction. Muscular contraction and gravity create opposing forces across the joint surfaces, known as joint reaction forces. It is important to spread these forces over the greatest possible joint surface area.

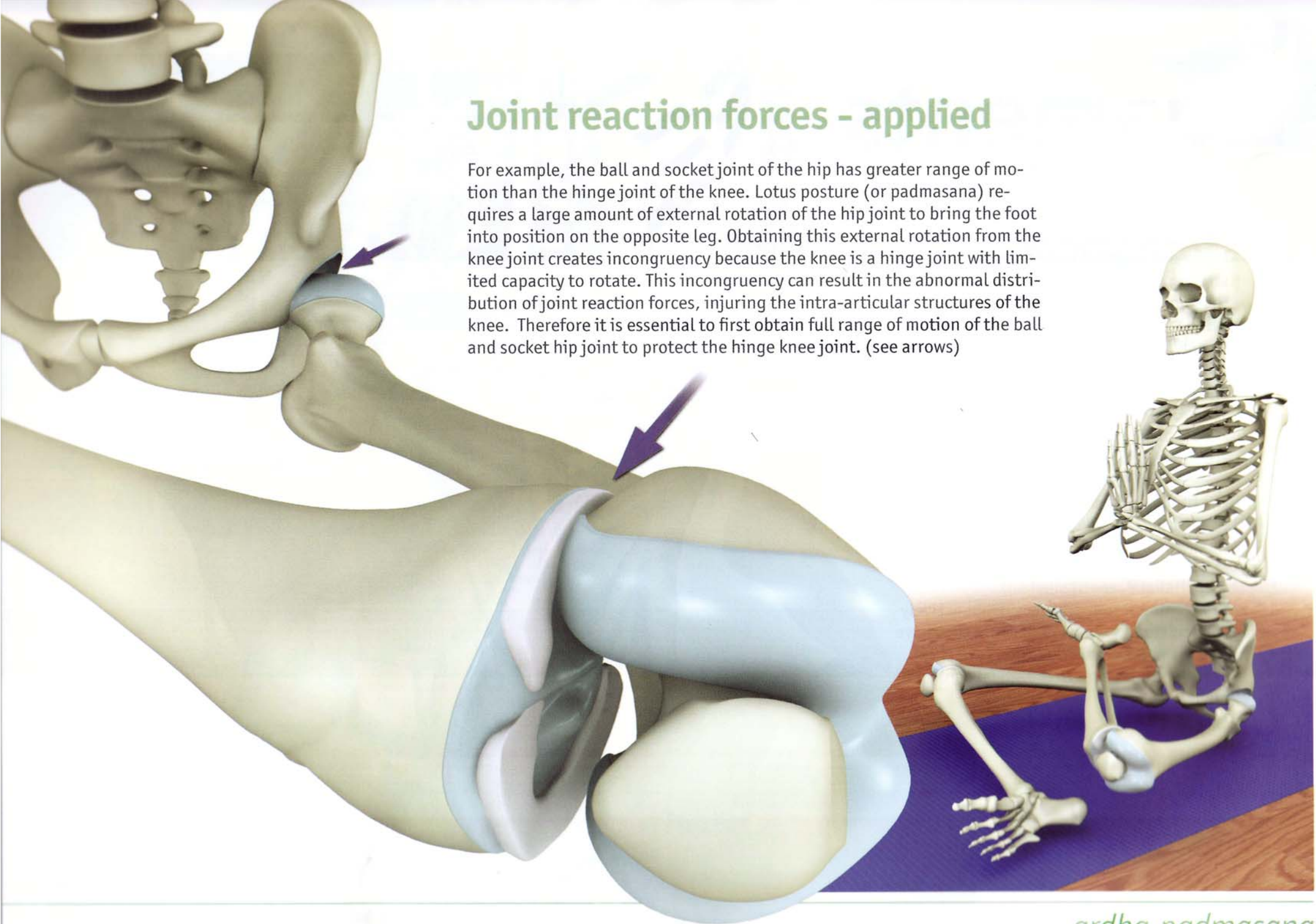
Joint congruency refers to the fit of a joint's articular surfaces. A joint is congruent when its surfaces fit together perfectly. Movement out of congruency focuses stress on a small surface area. A large force focused on a small area of articular cartilage can injure it, eventually causing degenerative changes.

Some yoga postures have the capacity to sublux or take a joint into an incongruent position. Avoid this by using the joints with a greater range of motion while protecting those joints with limited range of motion.



Joint reaction forces - applied

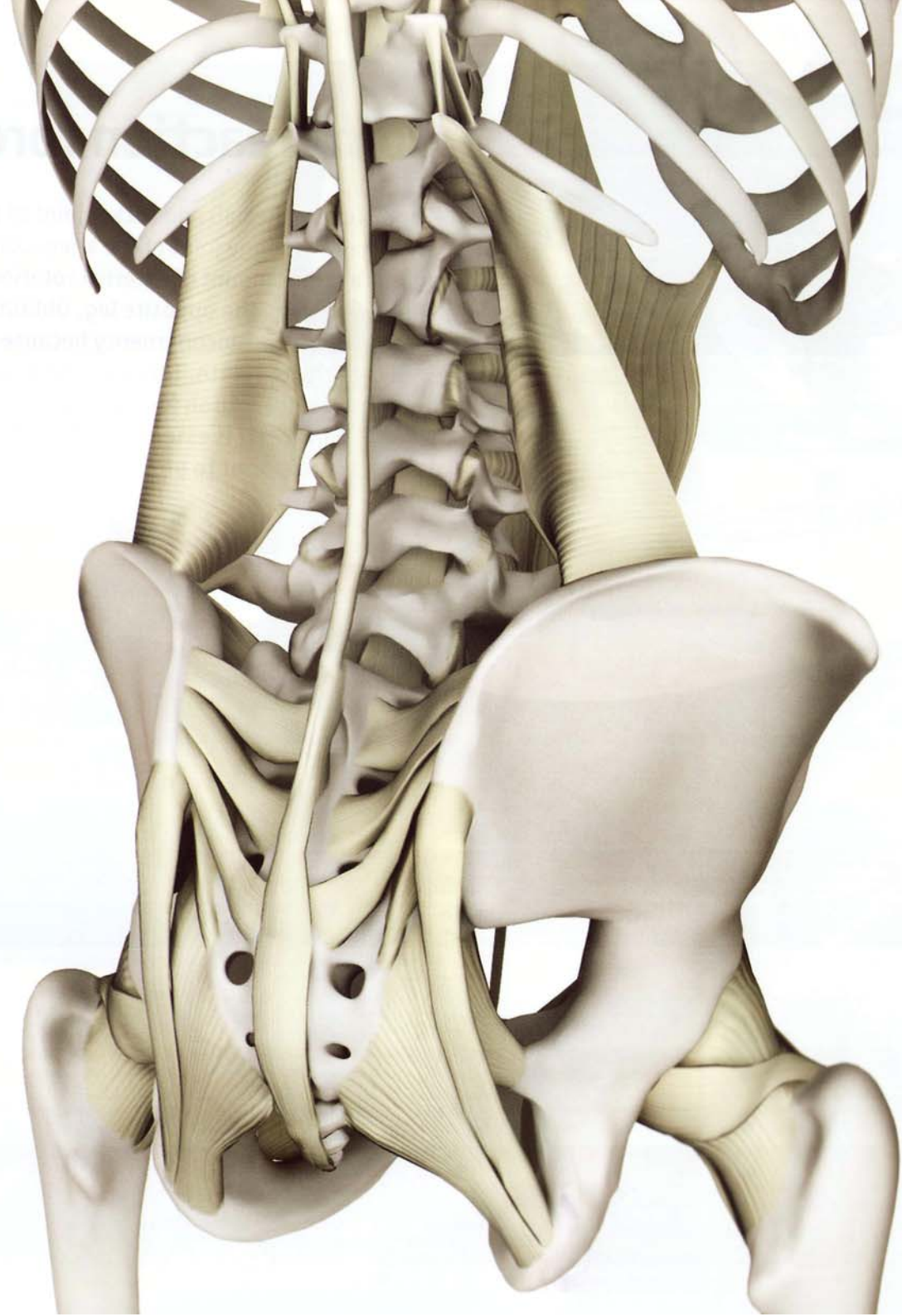
For example, the ball and socket joint of the hip has greater range of motion than the hinge joint of the knee. Lotus posture (or padmasana) requires a large amount of external rotation of the hip joint to bring the foot into position on the opposite leg. Obtaining this external rotation from the knee joint creates incongruity because the knee is a hinge joint with limited capacity to rotate. This incongruity can result in the abnormal distribution of joint reaction forces, injuring the intra-articular structures of the knee. Therefore it is essential to first obtain full range of motion of the ball and socket hip joint to protect the hinge knee joint. (see arrows)

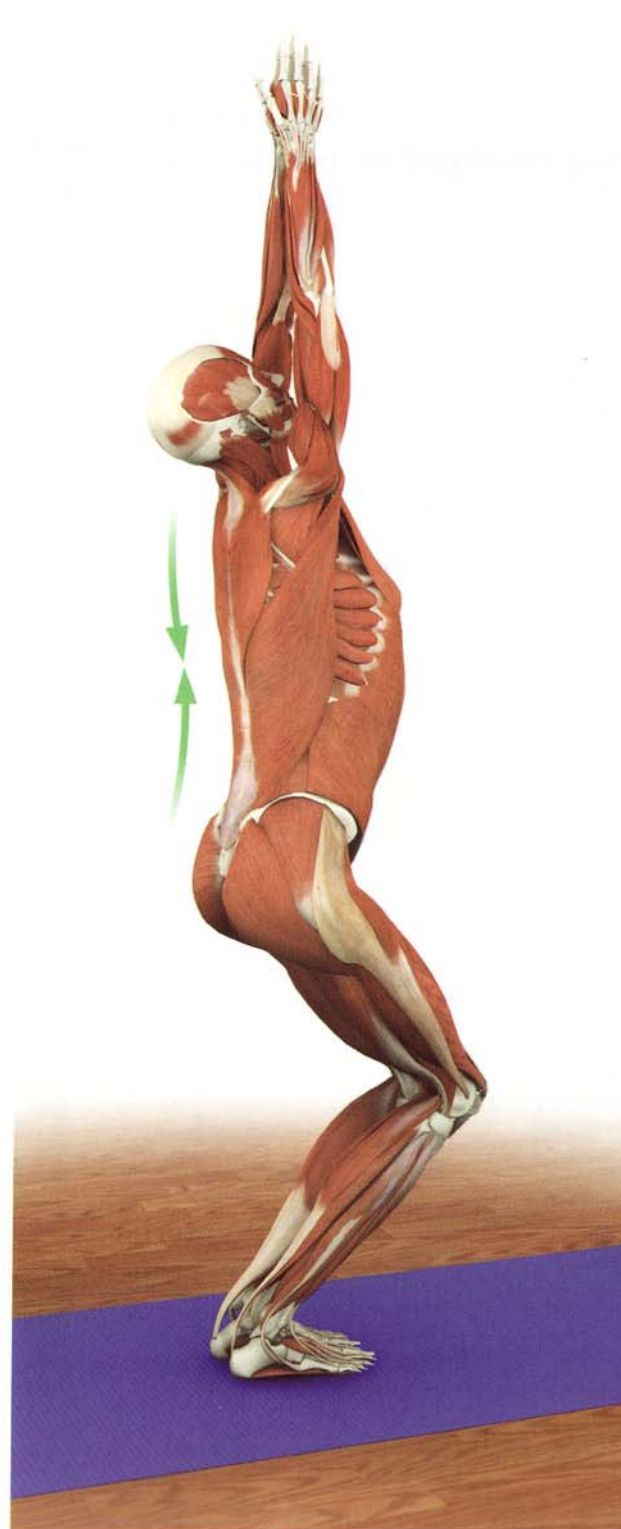
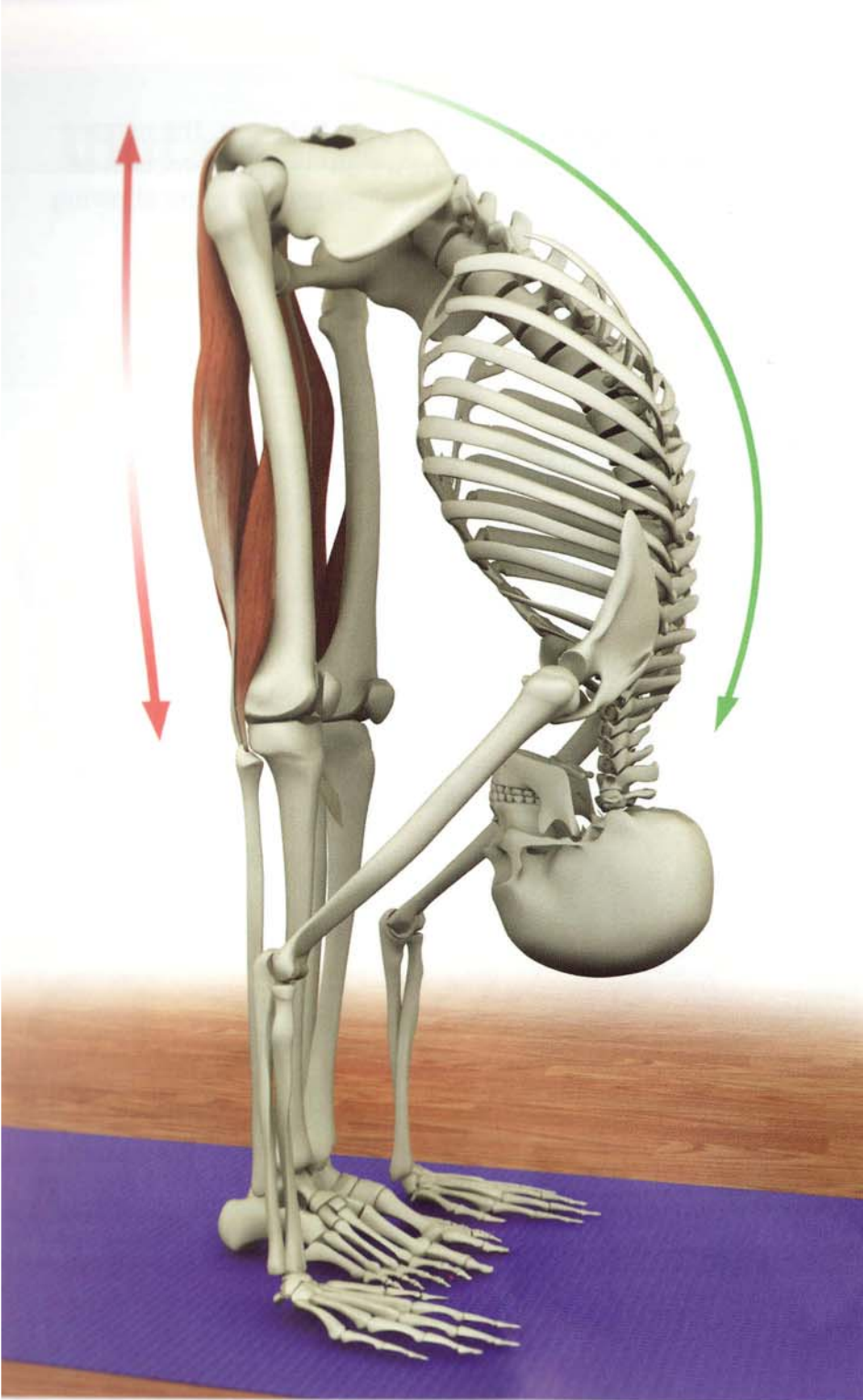


Ligaments

Ligaments are fibrous connective tissue structures that link one bone to another at the joint. They serve to stabilize the joint while at the same time allowing mobility. Ligaments vary in size and shape according to their function. For example, the cruciate ligaments of the knee are short, stout structures that assist in maintaining the knee as a hinge. The sacroiliac ligaments are dense, broad and thick structures that limit movement of the sacroiliac joint. The shoulder ligaments are thin band-like structures that are confluent with the shoulder capsule, allowing for great range of motion.

Ligaments are non-contractile but actively participate in movement because they have sensory nerves that transmit information about joint position to the spinal cord and brain.



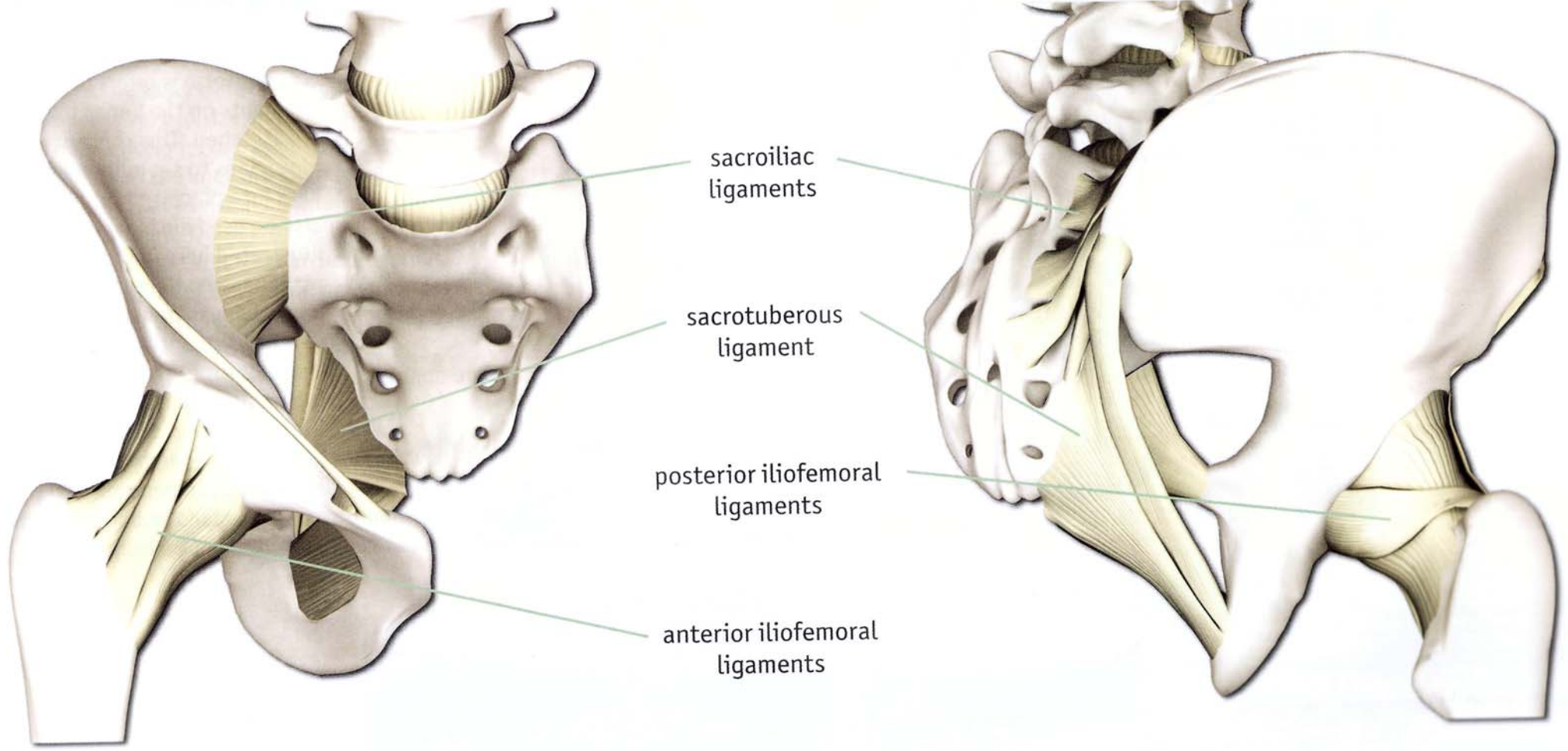


Ligamentotaxis

Ligamentotaxis refers to the pull of ligaments on the bones to which they are attached. This concept is used by physicians to set pull broken bones back into place and set them. It can also be used during yoga practice as illustrated here in the forward bend utthanasana. Here the weight of the upper body is transmitted to the pelvis via the ligaments of the back. This pulls the pelvis forward and lifts the ischial tuberosities, passively stretching the hamstrings. Similarly, ligaments have some capacity for elastic recoil. This recoil can be combined with the momentum of the body as it raises from postures such as back bend.

Pelvic and Hip Ligaments

The form of the pelvic and hip ligaments reflects their function. The pelvic ligaments are thick and strong in support of the weight bearing function of these joints. The hip ligaments are shaped to stabilize the hip while allowing movement for walking and running.

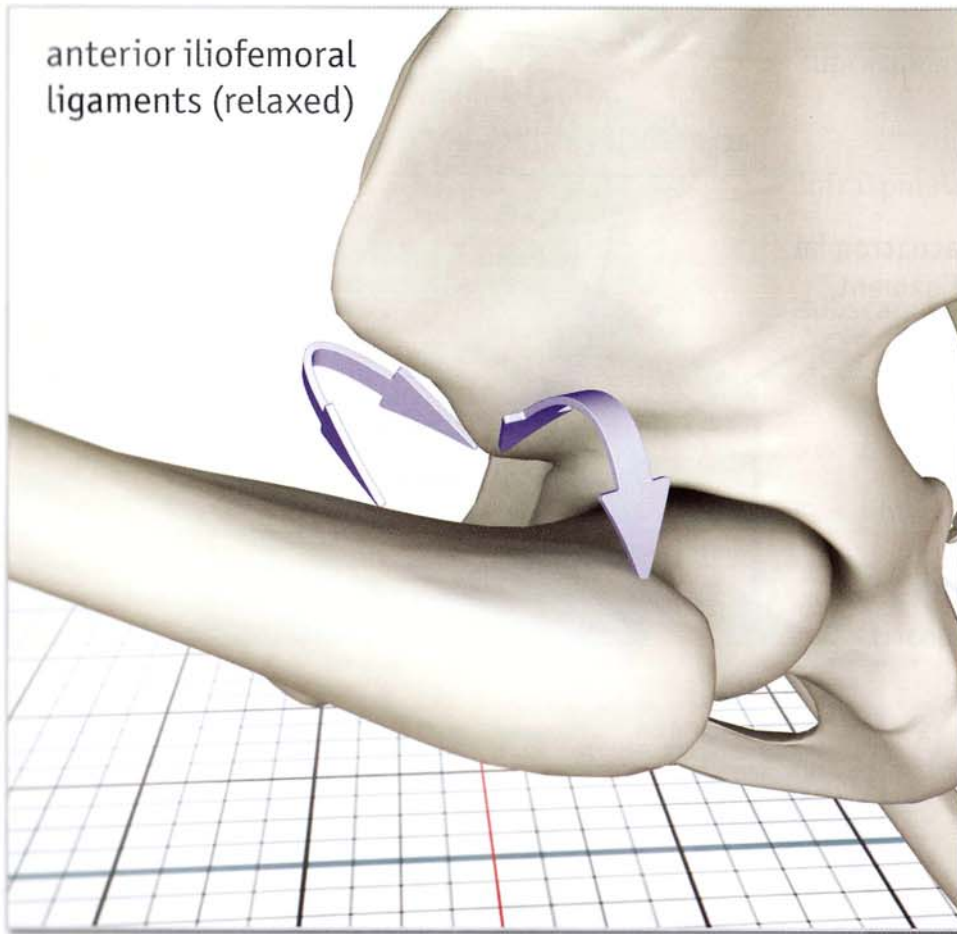


Pelvis and Hip (anterior)

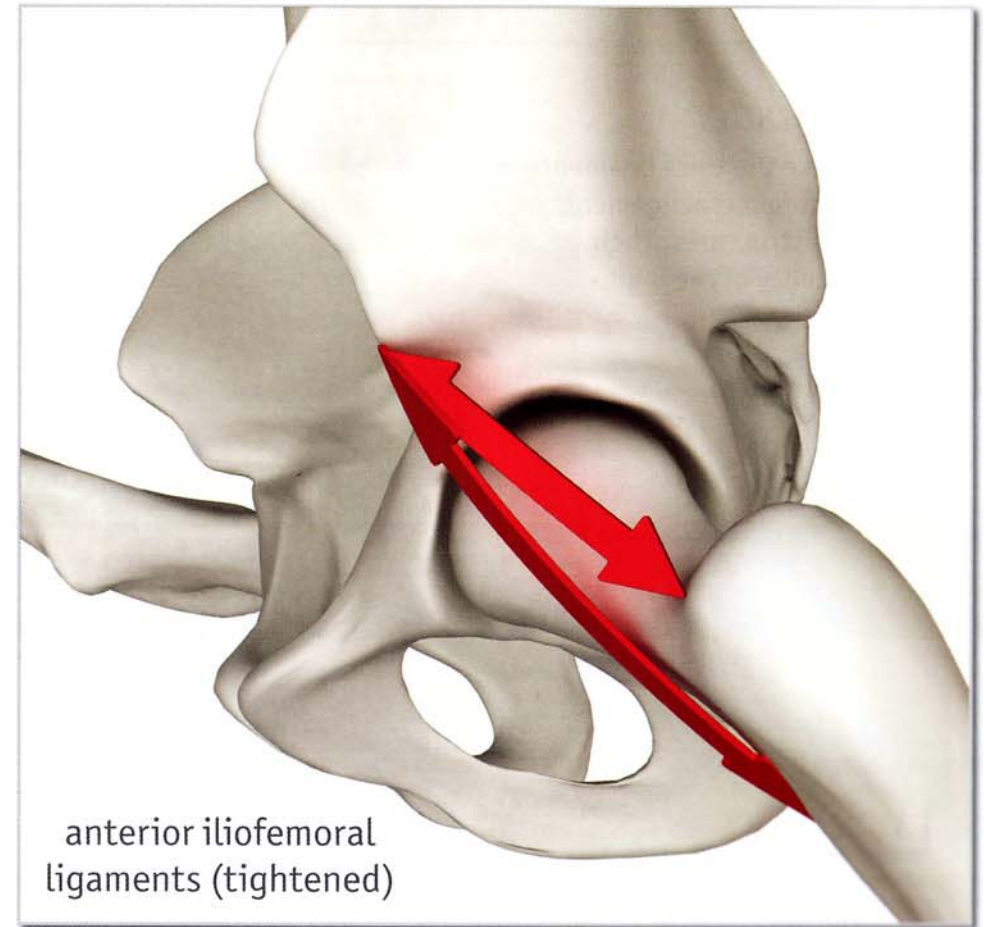
Pelvis and Hip (posterior)

Iliofemoral Ligaments

The anterior iliofemoral ligaments are part of the hip joint and stabilize it. These ligaments become taut when the femur extends and externally rotates. They relax when the femur flexes and internally rotates. Tightness in these ligaments limits extension of the hip in lunging poses and forward splits. This limitation is overcome by tilting the pelvis forward and internally rotating the femur.



Hip joint (flexed, internally rotated)

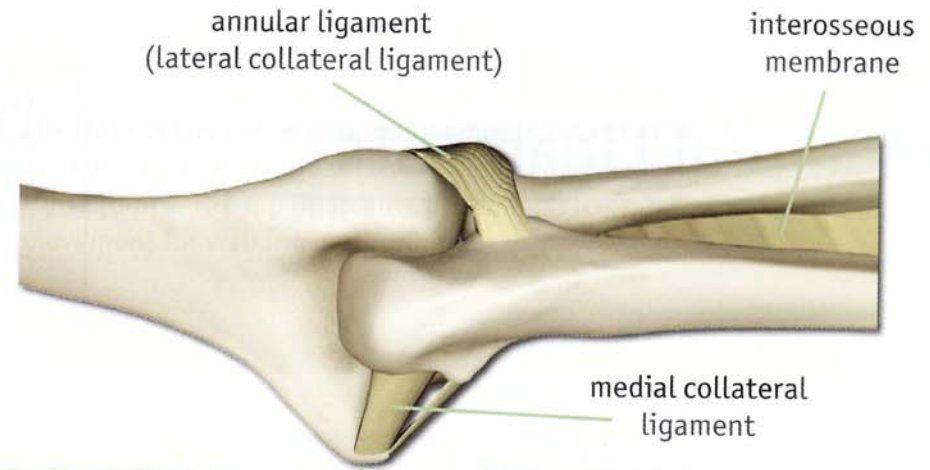


Hip joint (extended, externally rotated)

Shoulder and Elbow Ligaments

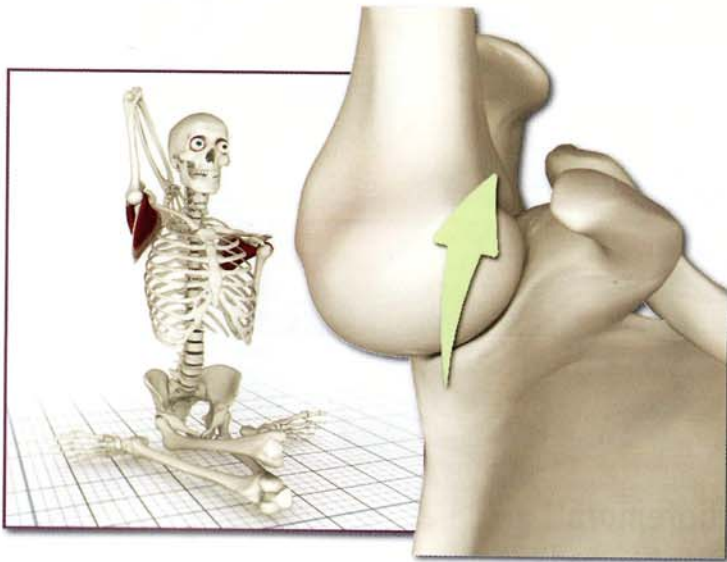
Elbow (posterior)

The collateral ligaments of the elbow limit side to side motion and maintain the joint as a hinge. The interosseous membrane stabilizes the bones of the forearm.

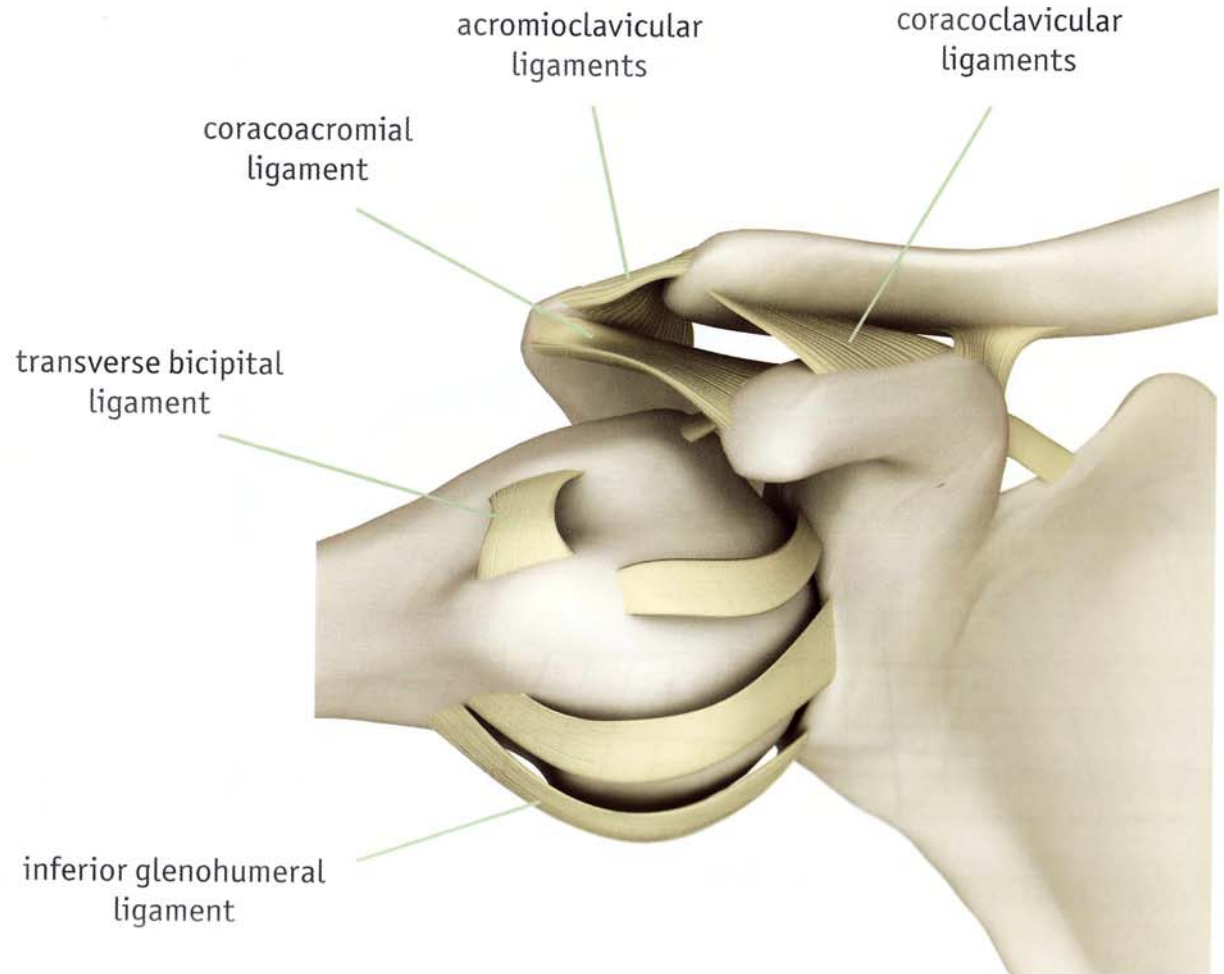


Shoulder

Unlike the thick ligaments of the hip, the glenohumeral ligaments of the shoulder are thin structures. Their design allows greater mobility of the joint.

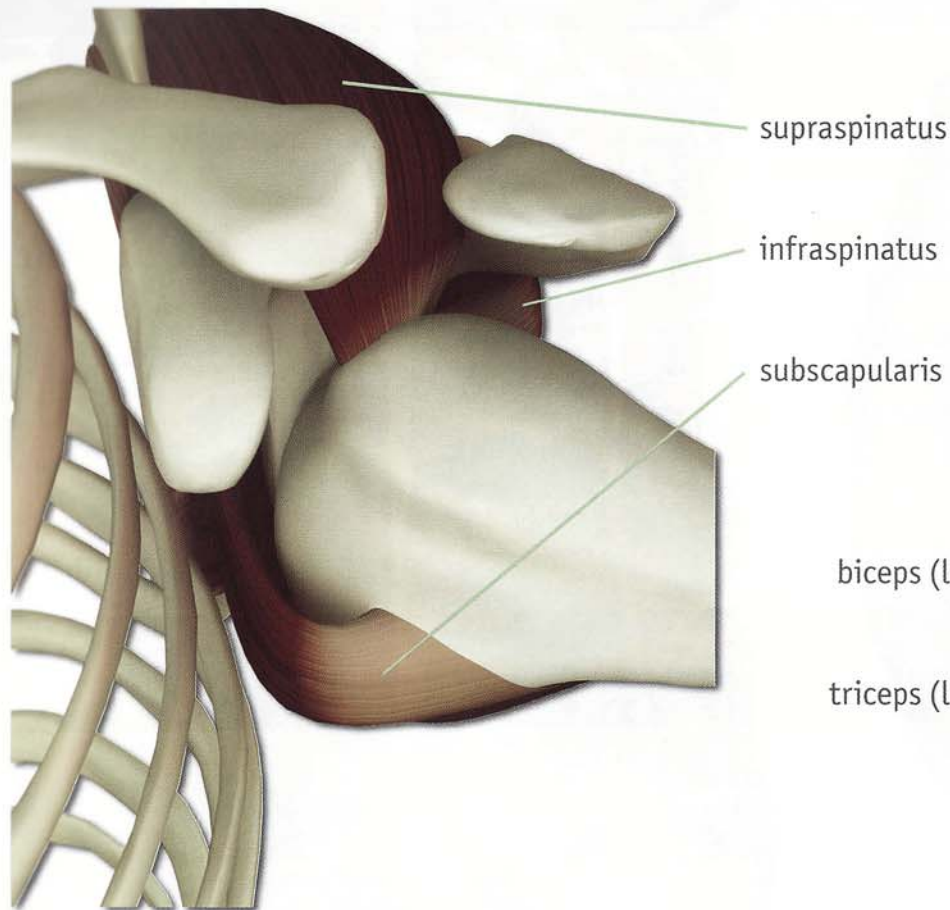


The inferior glenohumeral ligament is the most important of the three glenohumeral ligaments. This ligament tightens when the humerus abducts and externally rotates.

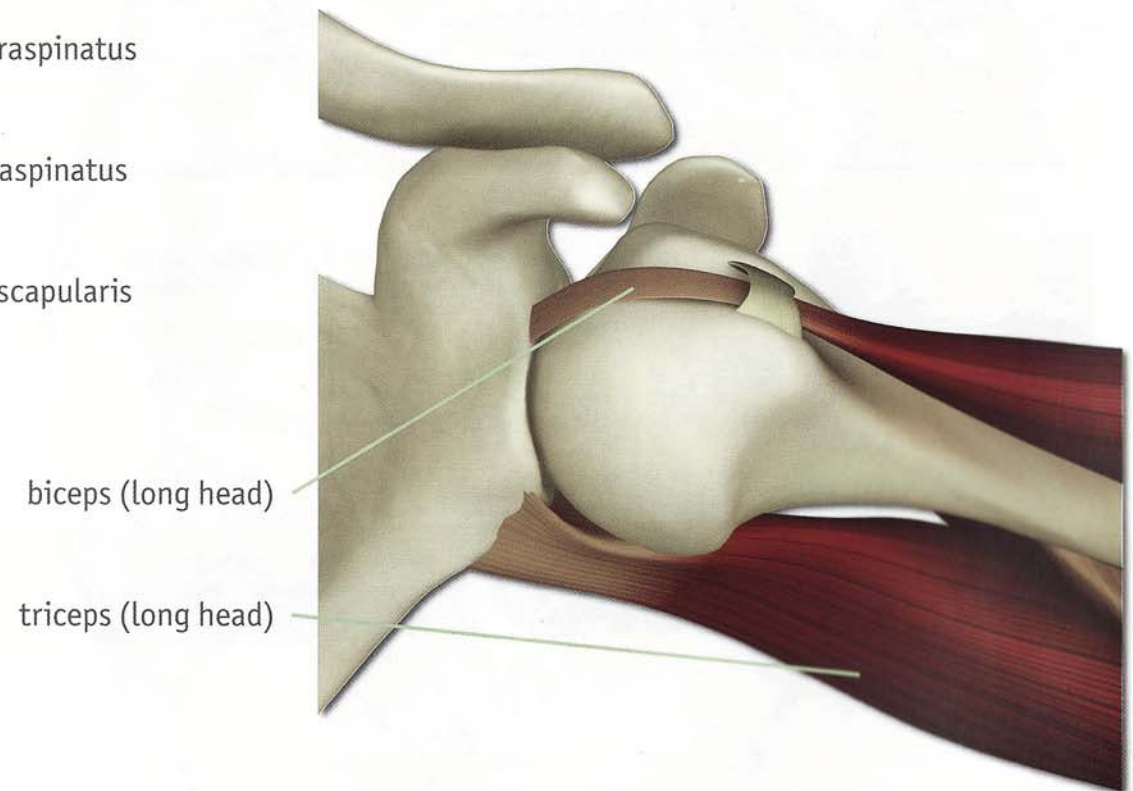


The Muscular Stabilizers of the Shoulder

The shape of the bones and thick ligaments stabilize the hip. Muscles stabilize the shoulder. The primary shoulder stabilizer is the rotator cuff, the secondary stabilizers are the triceps and biceps. Yoga postures such as arm balances and inversions strengthen these muscles, balancing stability and mobility in the joint.



*Rotator Cuff
(stabilizing shoulder joint)*



*Biceps and Triceps
(stabilizing shoulder joint)*

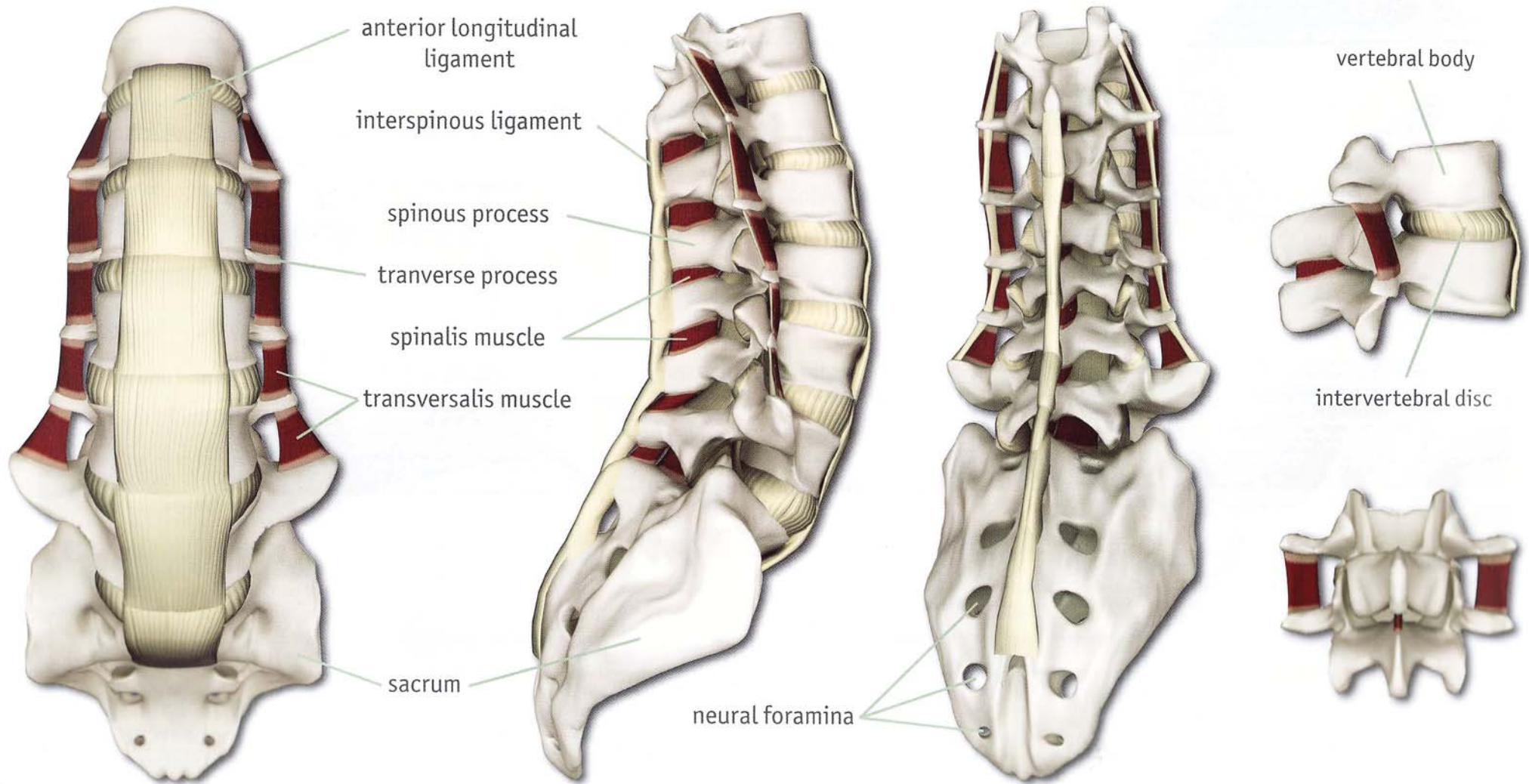
Shoulder and Elbow Ligaments

Spine Ligaments

VERTEBRAL UNIT

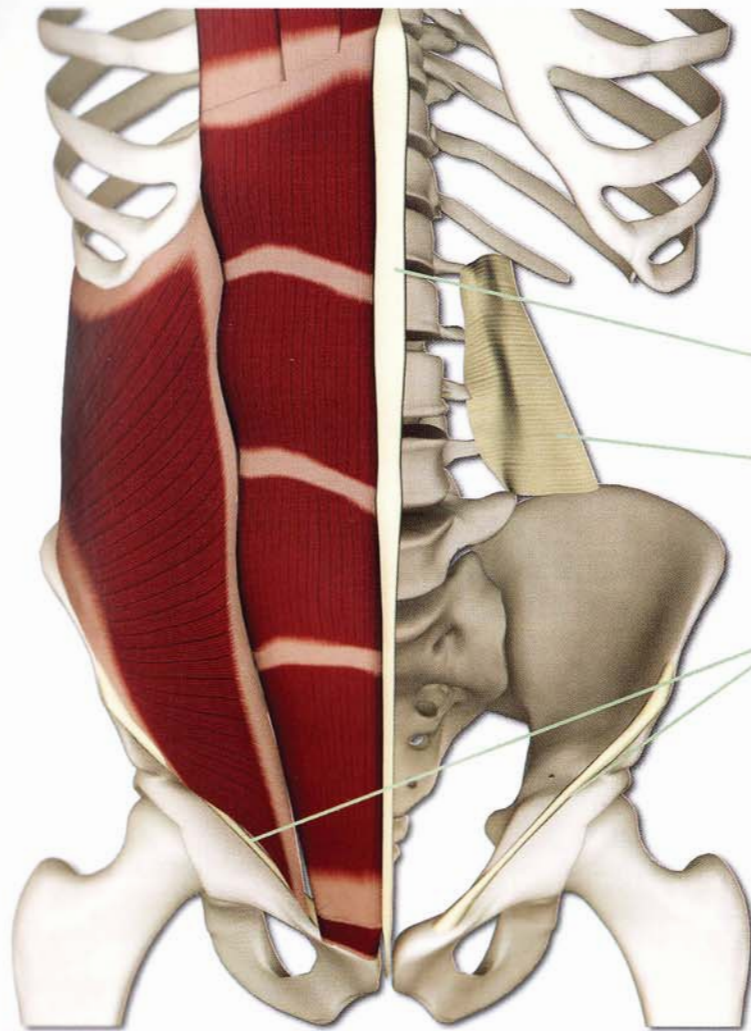
The vertebral unit is comprised of two adjacent vertebral bodies and the intervertebral disc. Movement between the vertebrae is possible in several planes (including small amounts of rotation, flexion and extension). The combination of motion across multiple vertebral units culminates in spinal movement.

LUMBOSACRAL SPINE

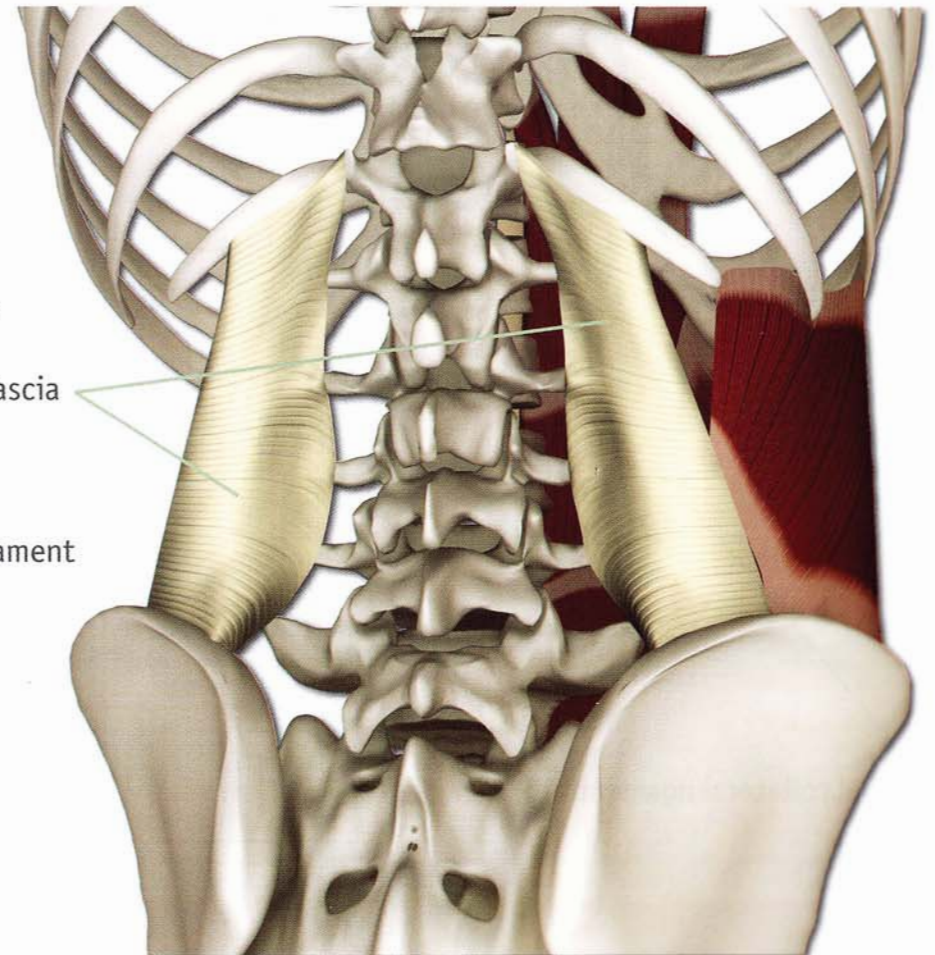


Trunk Ligaments

Ligaments attach bone to bone and also serve as attachments for certain muscles. Below are three such ligaments that connect the upper body and trunk with the lower body.



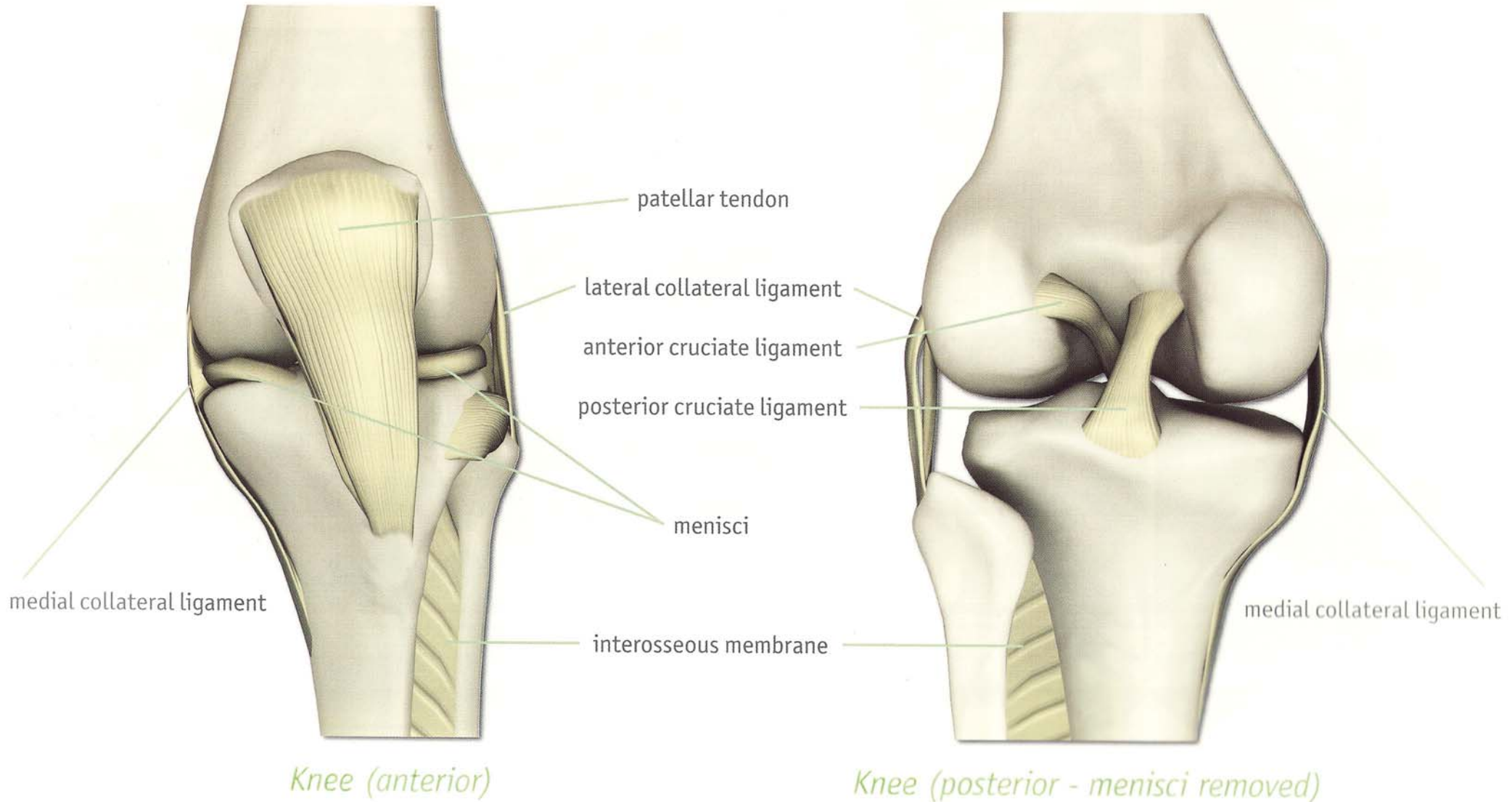
Trunk (anterior)



Trunk (posterior)

Knee Ligaments

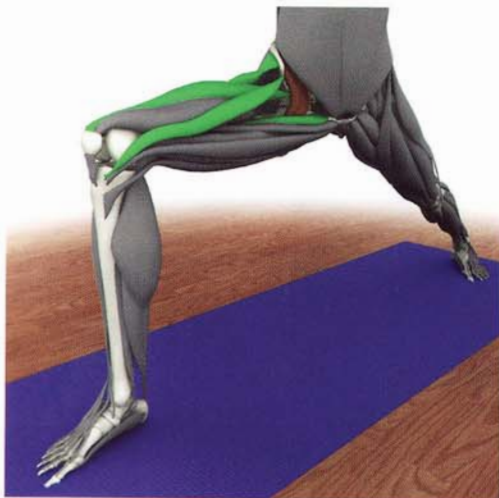The patellar tendon connects the quadriceps muscle to the tibia for extension of the knee. The collateral ligaments limit side to side motion of the knee and maintain its function as a hinge joint. The anterior and posterior cruciate ligaments limit anterior and posterior translation of the tibia on the femur (respectively). The menisci deepen and stabilize the knee joint. The interosseous membrane stabilizes the bones of the lower leg.



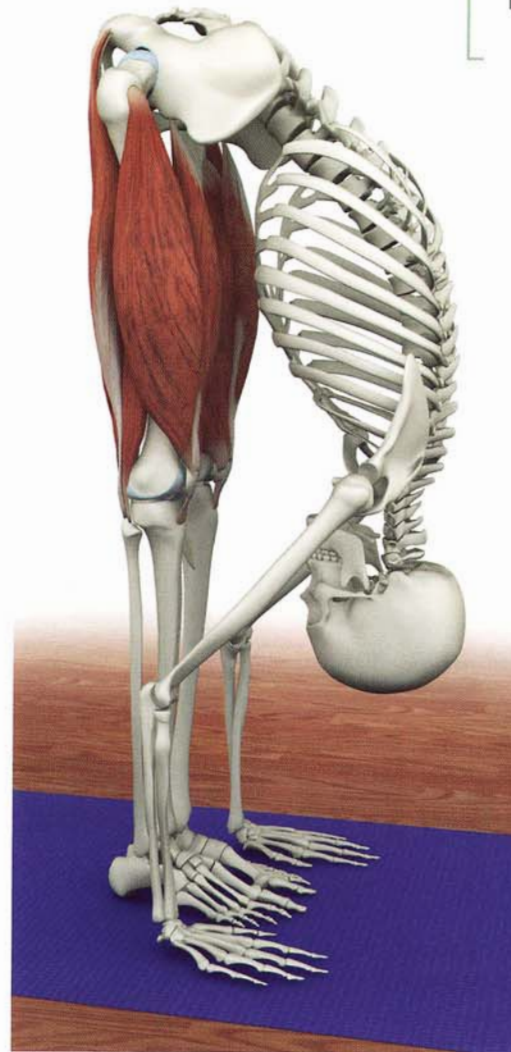
Muscles and Tendons

Muscles

Movements are determined by the varying forces acting across the joints. These forces are produced by the muscles, and their effects on body position are determined by the muscles' shape, origin (the attachment of the muscle to a bone at the more fixed or proximal end), and insertion (the attachment of the muscle to a bone at the end toward the part to be moved, or the more distal end).



The synergists of psoas assist in flexing the hip.



The quadriceps are the agonists that contract to extend the knees. The hamstrings are the antagonists stretched by this action.

Origin

Proximal attachment of the muscle to a bone.

Insertion

Distal attachment of the muscle to a bone.

Agonist, or prime mover

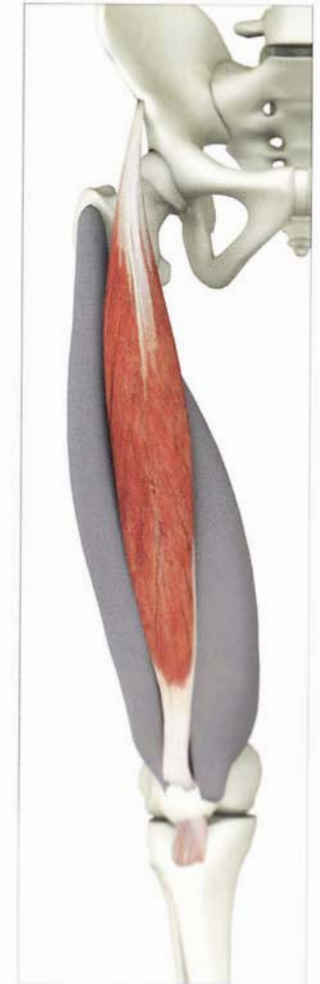The muscle that contracts to produce a certain action about a joint. For example, the hamstrings are agonists when you flex your knee.

Antagonist

A muscle that relaxes while the agonist contracts. The antagonist produces the opposite action about a joint. For example, the quadriceps (at the front of the thigh) is the antagonist to the hamstrings when you flex your knee. When you extend your knee, the quadriceps is the agonist and the hamstrings the antagonists.

Synergist


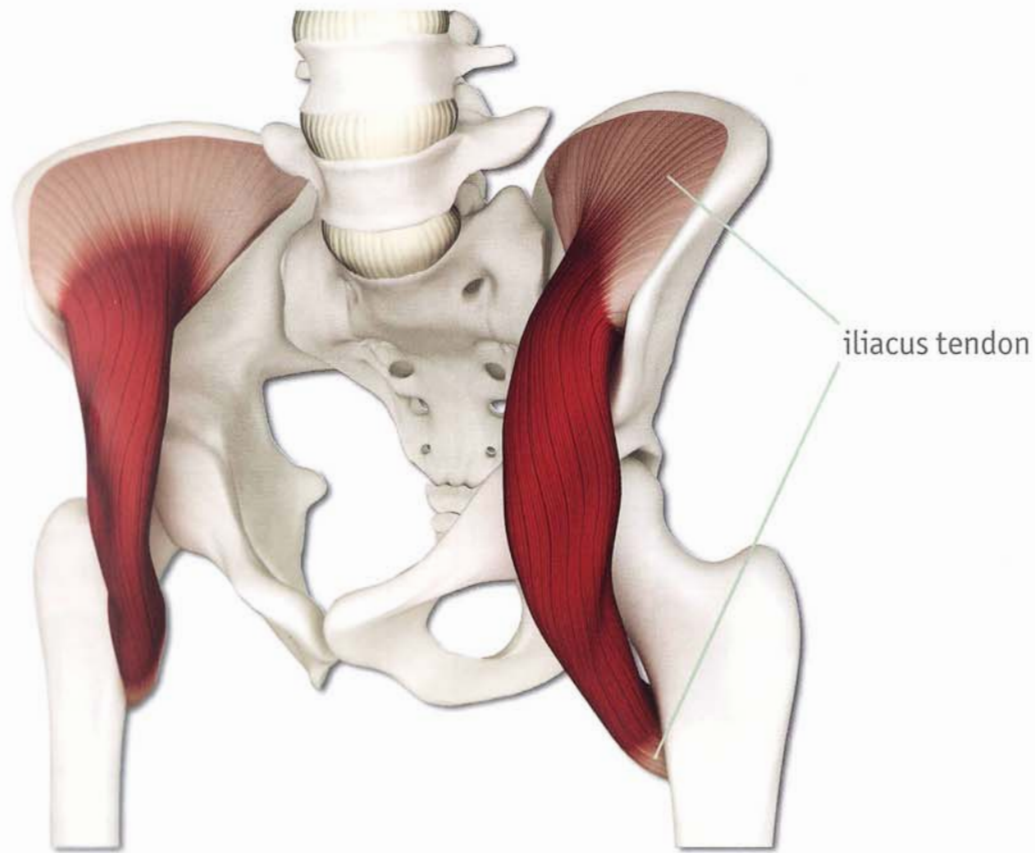
A muscle that assists and fine-tunes the action of the agonist and can be used to produce the same action, although generally not as efficiently.



The origin of the rectus femoris is the anterior superior iliac spine. The insertion is the patella.

Muscles and Tendons


Tendons attach muscles to bones, transmitting the forces produced by the muscles, moving joints. Tendons also have sensory nerves that communicate information about muscle tension and joint position to the brain. Tendons and ligaments have limited capacity to stretch and do not contract. Practicing yoga improves tendon and ligament flexibility, especially when performed in a heated room. Practitioners should not stretch tendons or ligaments beyond their normal length as this can cause injury.



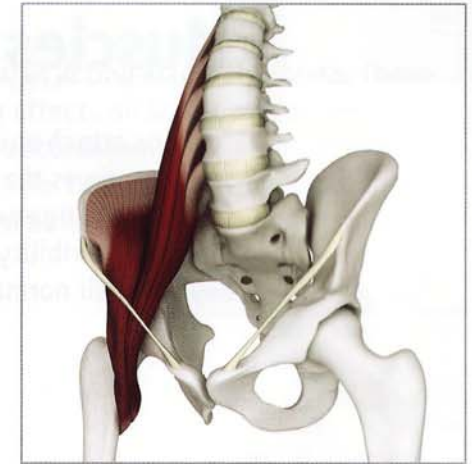
Muscles

Muscle Shapes

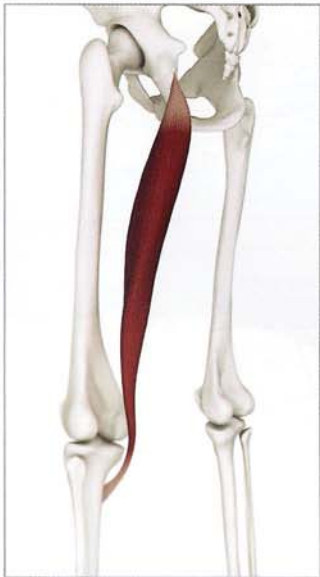Muscles come in a variety of shapes, reflecting their specific function. These different shapes provide for maximal mechanical efficiency during movement of the skeleton. Similarly, muscles may curve over the bones to provide a "half-pulley" effect which multiplies the force of contraction. Some of the various muscle shapes include the following:



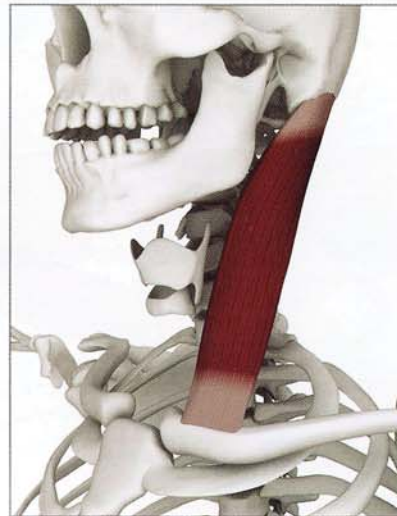biceps brachialis
two headed fusiform



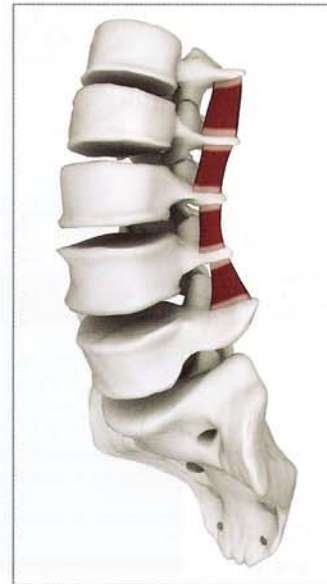iliopsoas
multiheaded convergent
(with half pulley)



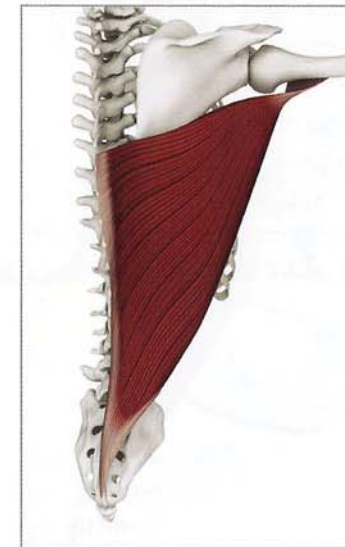
semitendinosus
one headed fusiform



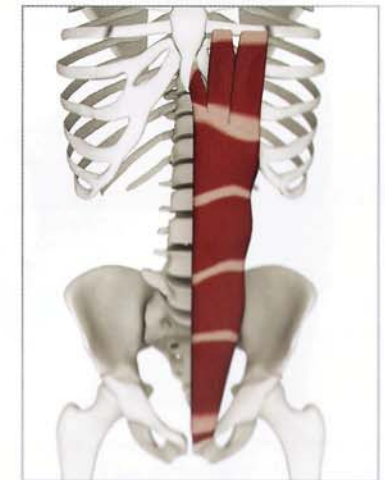sternocleidomastoid
strap



transversalis
short square



latissimus dorsi
triangular convergent



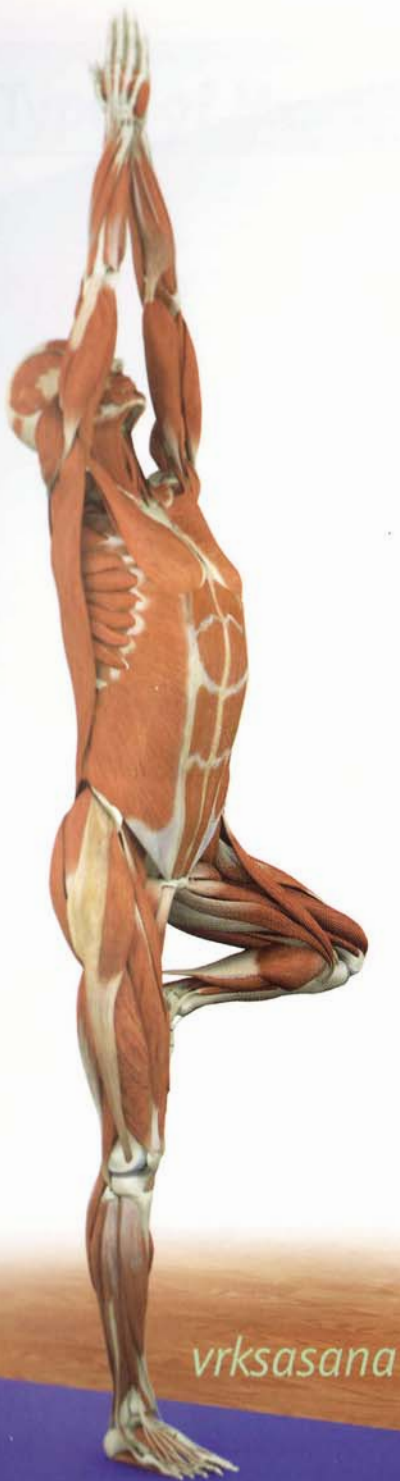rectus abdominus
flat aponeurotic

Mono-articular and Poly-articular Muscles

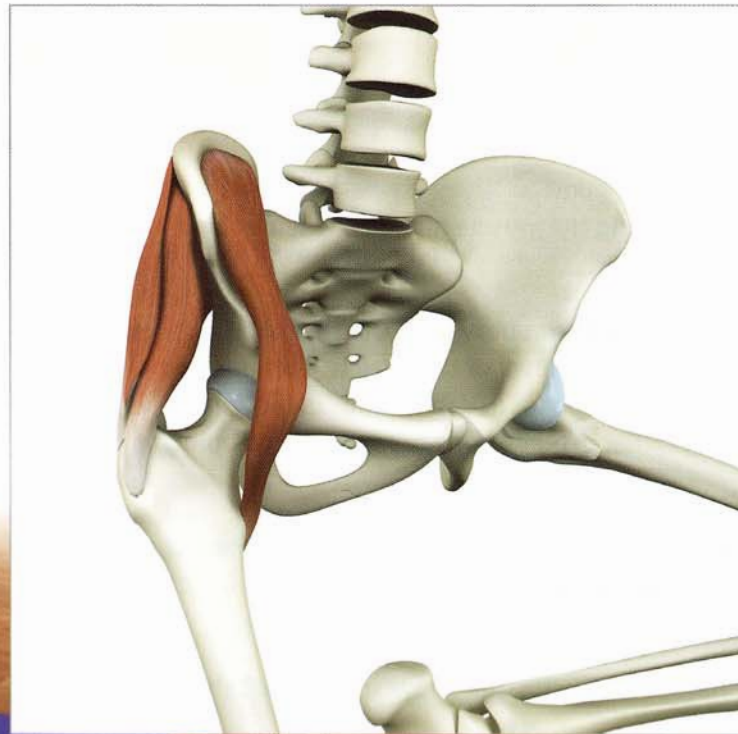Muscles are also defined by the number of joints that they cross from their origin to their insertion. Monoarticular muscles cross only one joint while polyarticular muscles cross more than one joint.

When monoarticular muscles contract they primarily move only one joint. When polyarticular muscles contract they can move multiple joints.

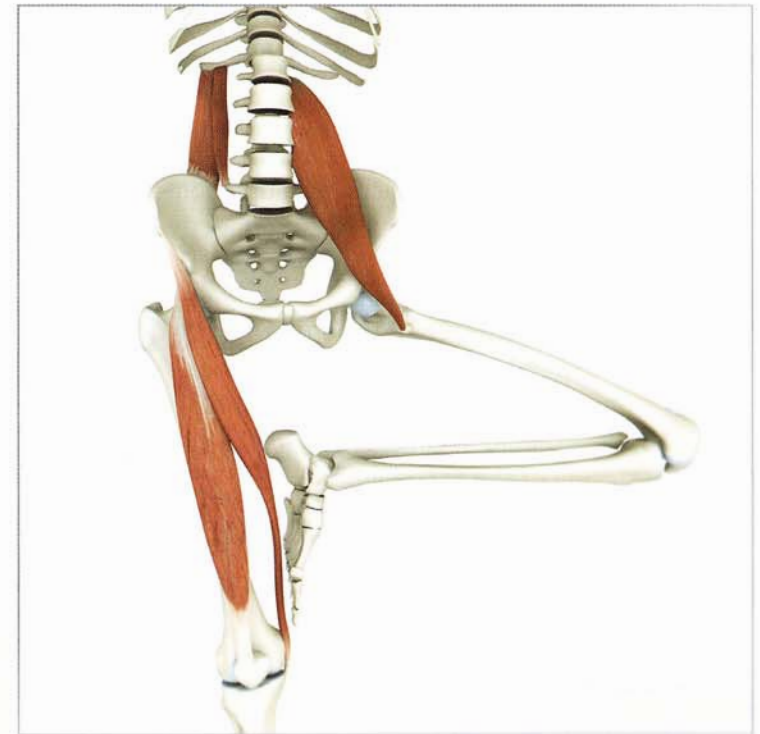For example, in the one-legged vrksasana the iliacus and gluteus medius represent monoarticular muscles because they originate on the ilium and attach to the proximal femur, crossing (and moving) only the hip joint. Here the iliacus and gluteus medius serve to stabilize the hip joint in the standing leg. The quadratus lumborum, psoas, rectus femoris and sartorius represent polyarticular muscles because they all cross (and move) multiple joints. Here these muscles contribute to flexing, abducting and externally rotating the non-standing leg.



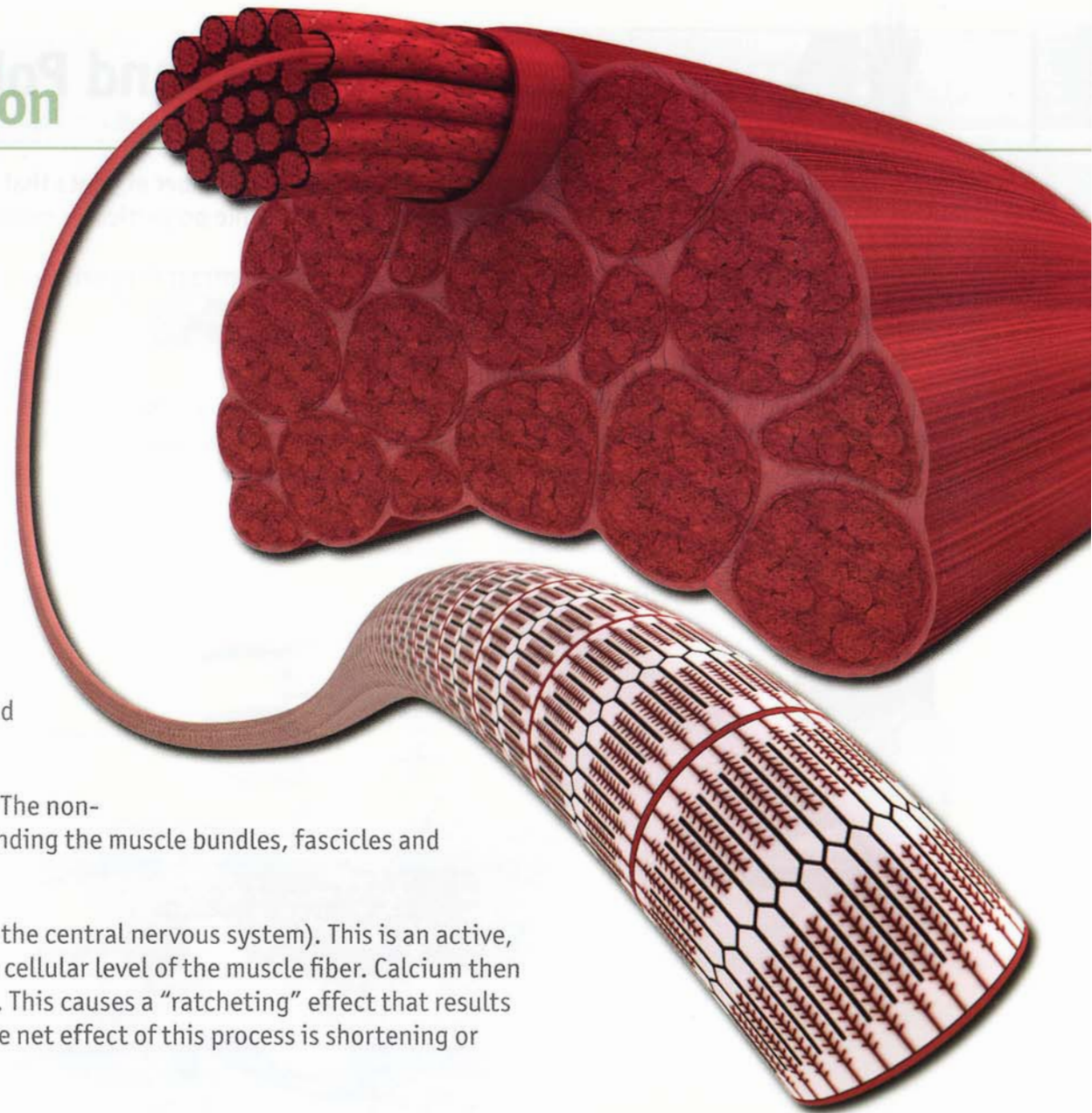
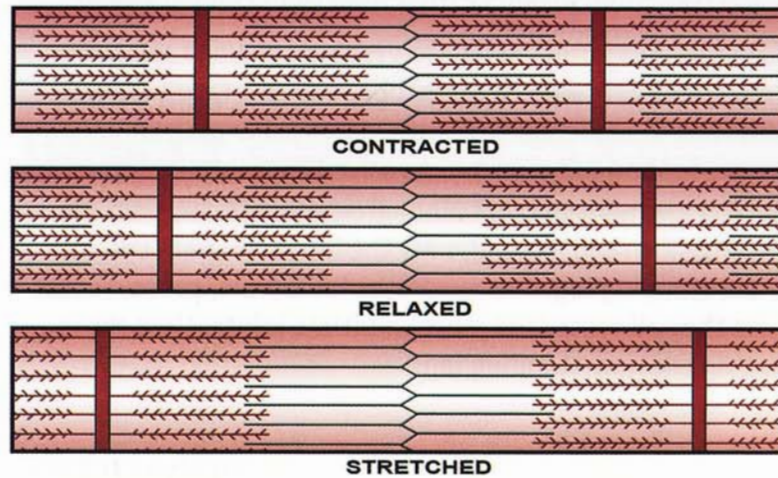
mono-articular



poly-articular



Muscle Structure and Function



Muscle fibers are the functional contractile units of each skeletal muscle. Fibers are grouped into fascicles which in turn are grouped into bundles, thus forming the individual skeletal muscles.

Skeletal muscles are also composed of non-contractile elements. The non-contractile elements include the connective tissue sheath surrounding the muscle bundles, fascicles and individual fibers, as well as the myotendon junction.

Muscle fibers contract in response to afferent nerve stimuli (from the central nervous system). This is an active, energy-dependent process involving the release of calcium at the cellular level of the muscle fiber. Calcium then forms cross bridging between the myofilaments (of the myofibril). This causes a "ratcheting" effect that results in the shortening or contraction of the individual muscle fiber. The net effect of this process is shortening or contraction of the entire muscle.

The force of this contraction is transmitted to the non-contractile fascial elements surrounding the muscle. These fascial elements then transmit this force to the myotendon junction and on to the bones, moving the joint.

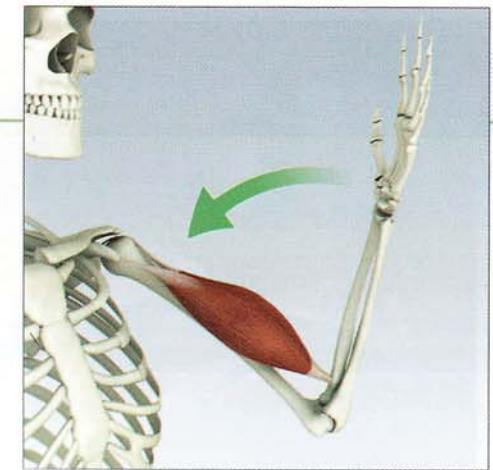
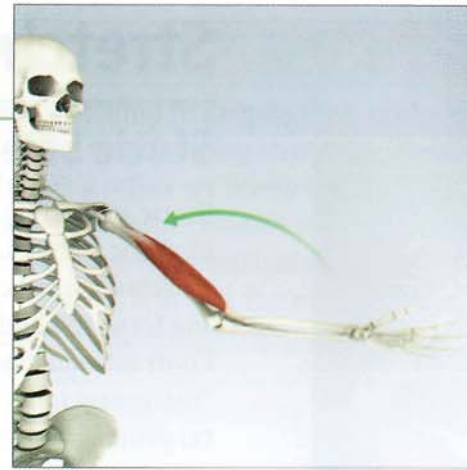
Muscles exist in either a contracted, relaxed or stretched state. This is illustrated above in the inset showing the cross bridging of myofilaments.

Types of Muscle Contraction

There are three types of muscle contraction:

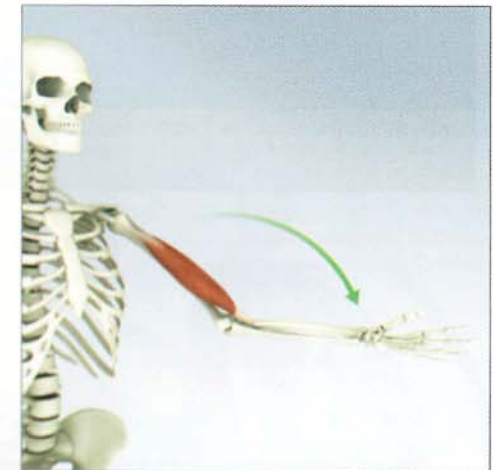
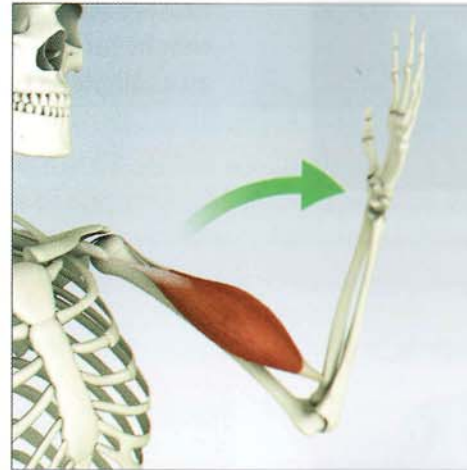
Concentric (isotonic) contraction:

The muscle shortens while maintaining constant tension through a range of motion.



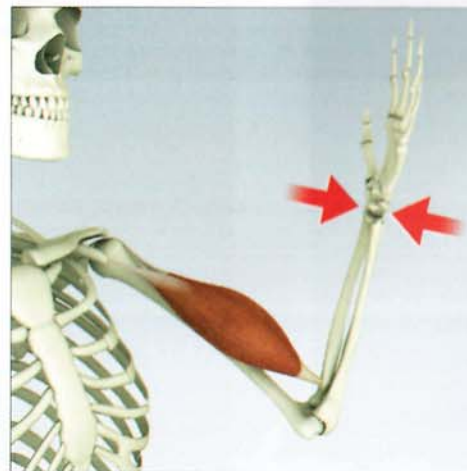
Eccentric contraction

The muscle contracts while lengthening.



Isometric contraction

The muscle generates tension but does not shorten, and the bones do not move.

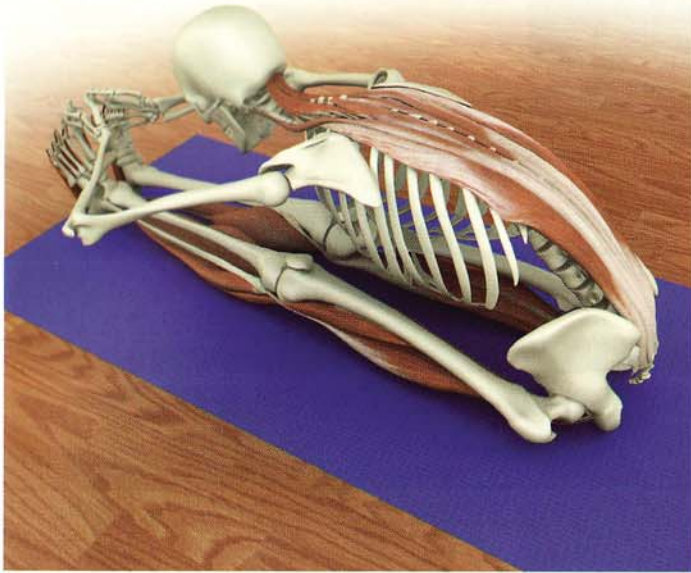


Stretching Muscles

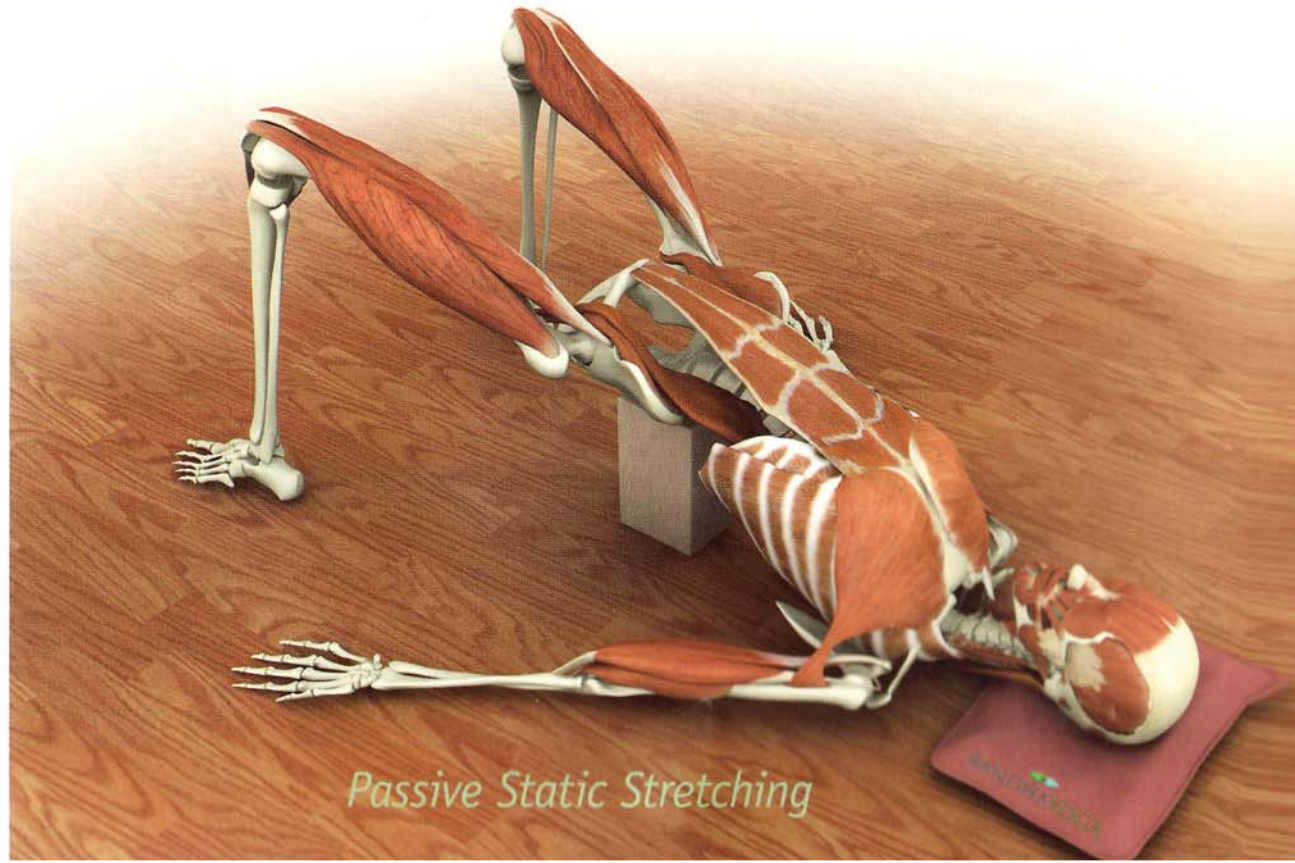
Static Stretching

Static stretching is the most common technique used in hatha yoga. There are two categories of static stretching. The first is active static stretching. This involves contracting antagonist muscles to stretch a target muscle. Contracting the quadriceps, iliopsoas and biceps during the forward bend paschimottasana is a form of active static stretching of the hamstrings. Contracting antagonist muscles in active static stretching results in a phenomenon called "reciprocal inhibition." During reciprocal inhibition, the central nervous system signals the target muscle to relax.

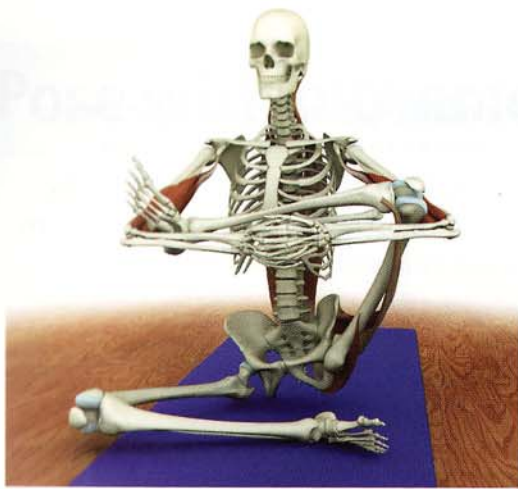Passive static stretching occurs when we relax into a stretch, using only the force of body weight (or an externally applied weight) to stretch muscles. The restorative pose setubandha is an example of passive static stretching of the iliopsoas muscle.



Active Static Stretching

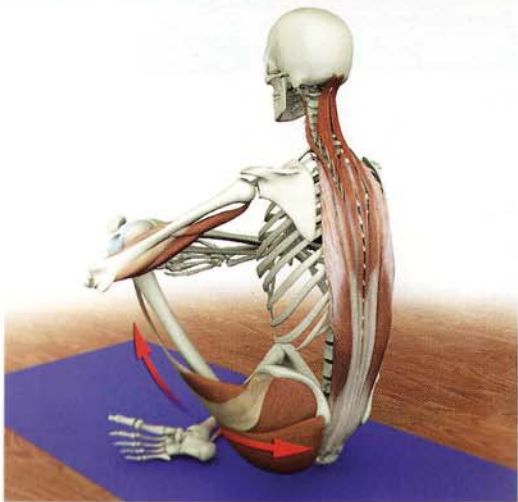
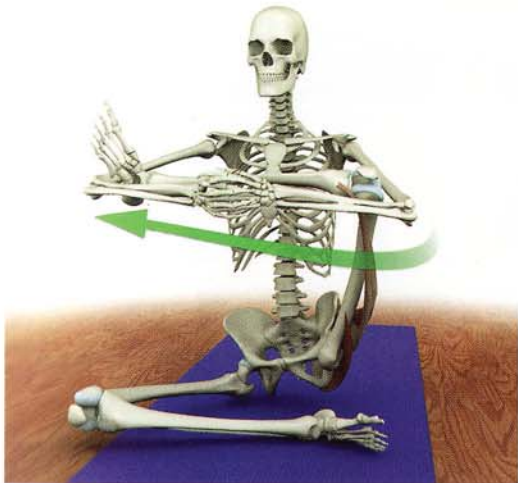

Passive Static Stretching



Facilitated Stretching

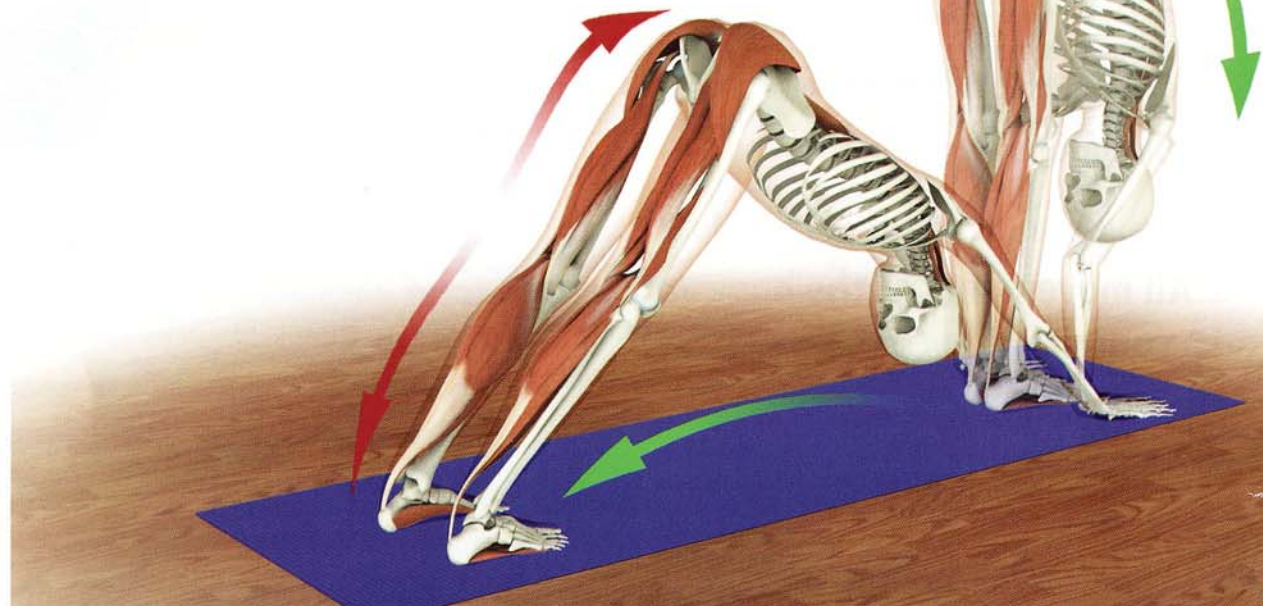
Yoga practitioners use facilitated stretching to deepen their postures. This type of stretching involves contracting the muscle being stretched during an active static stretching. This action triggers a reflex arc involving the Golgi tendon organ, resulting in a profound relaxation of the target muscle when the contraction period ends. This is also known as proprioceptive neuromuscular facilitation (PNF). It is extremely important to consider the joint reaction forces when using facilitated stretches, since the force the muscle generates is transmitted to the joints. As a general rule, gently contract the stretched muscle to avoid excessive joint reaction forces. These images demonstrate facilitated stretching of the gluteus medius, maximus and tensor fascia lata.



Dynamic Stretching

Yoga practitioners use dynamic stretching during the vinyasa type practice. This type of stretching involves repetitive movement of the body into increasingly deeper stretches. Performing dynamic stretching in the morning “resets” the resting muscle length for the day.

(Scientific Keys, Volume II covers the physiology of stretching in detail).



Movement

Movement Definitions

Motion of the musculoskeletal system necessarily involves multiple joints, forces applied in many directions, and movement in many planes. A convention exists to describe the basic movements of the musculoskeletal system that can be useful in analyzing the form and function of the asanas.


The six basic movements of the body take place in three planes.

Coronal plane: Divides the body into front and back. Movements along this plane are called adduction and abduction. Adduction moves the extremity towards the midline, abduction moves the extremity away from the midline.

Sagittal plane: Divides the body into right and left. Movements along this plane are called flexion and extension. Flexion usually moves the extremity forward except at the knee where it moves backward. Extension moves the extremity backward.

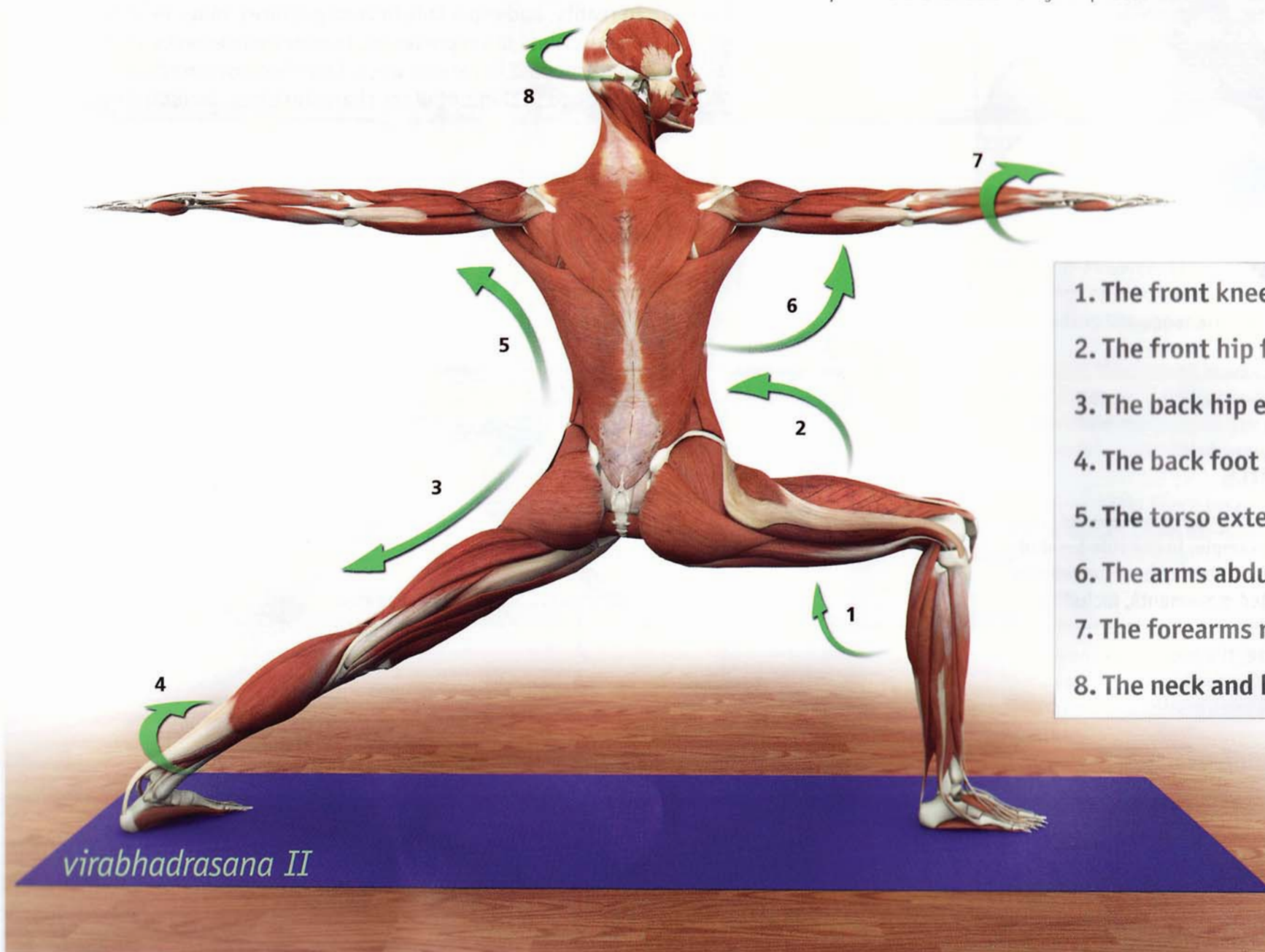
Transverse plane: Divides the body into upper and lower halves. Movement along this plane is called rotation. Rotation is further classified as medial rotation (toward the midline) or lateral rotation (away from the midline). Medial and lateral rotation are also referred to as internal and external rotation, respectively.

All movements of the body are composed of varying contributions of these six elemental movements.

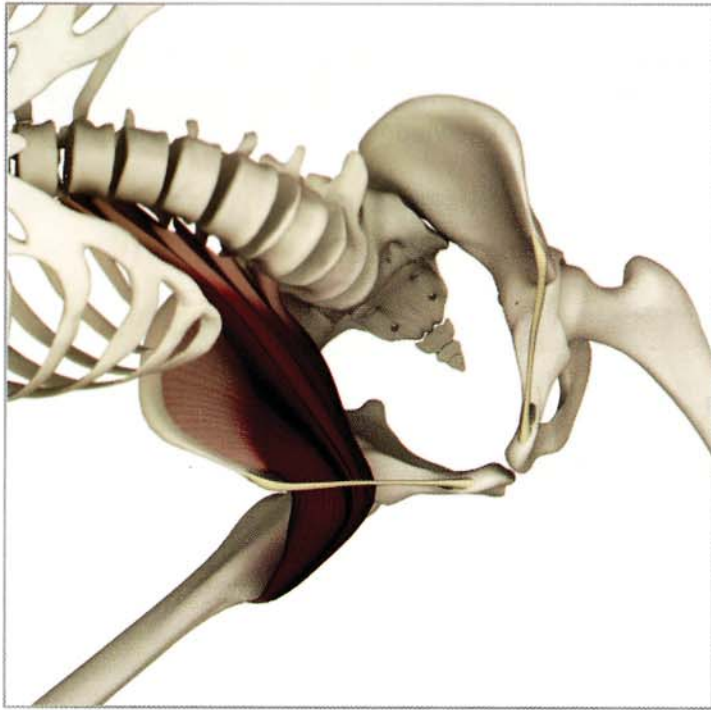


Pose with movements

The form of each asana reflects its function and vice versa. Here we use virabhadrasana II to analyze the positions of the body in a yoga posture. You can combine this analysis with knowledge of the muscle actions to optimize the function of your poses.



1. The front knee flexes.
2. The front hip flexes.
3. The back hip extends.
4. The back foot rotates internally.
5. The torso extends.
6. The arms abduct.
7. The forearms rotate internally.
8. The neck and head rotate.

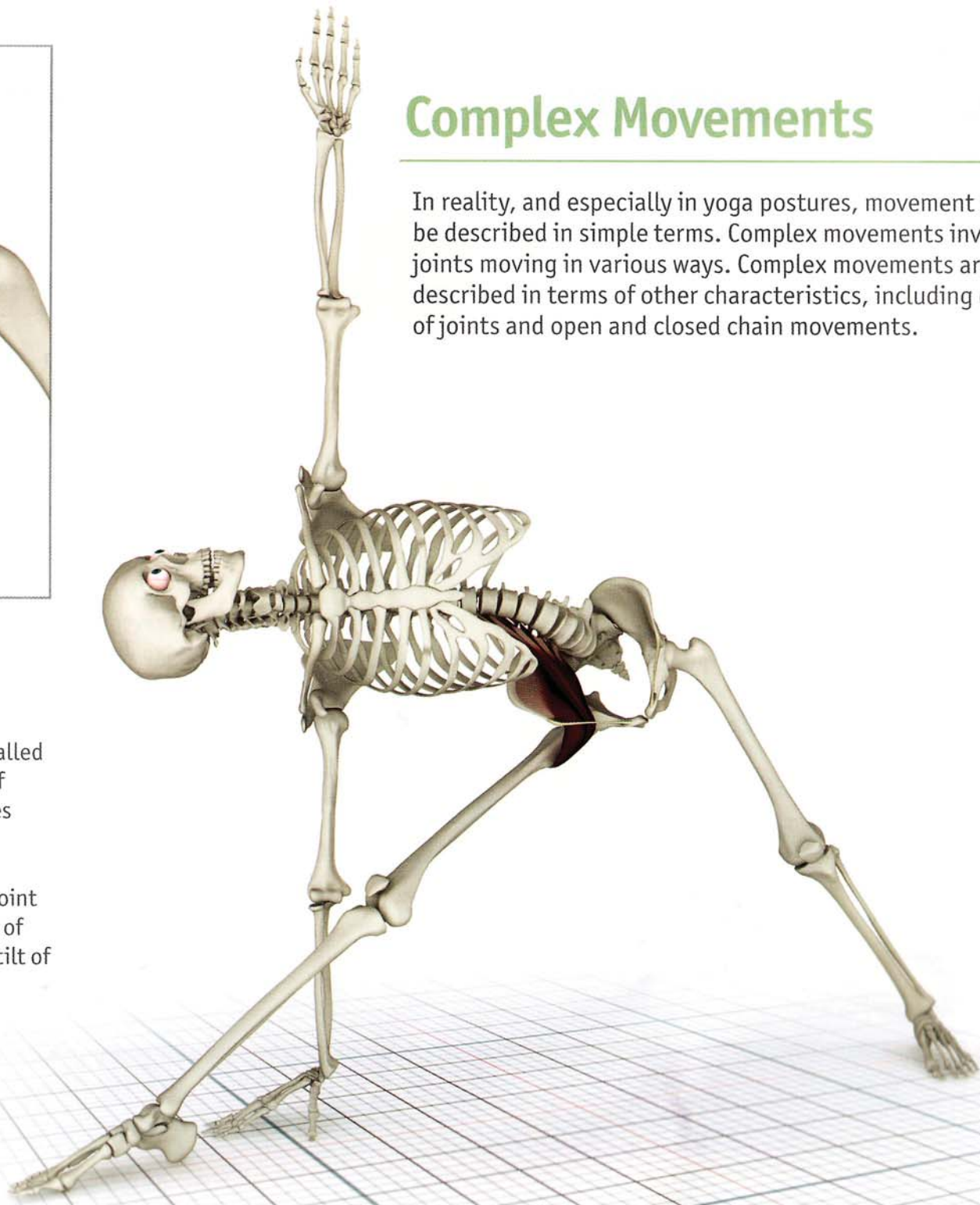


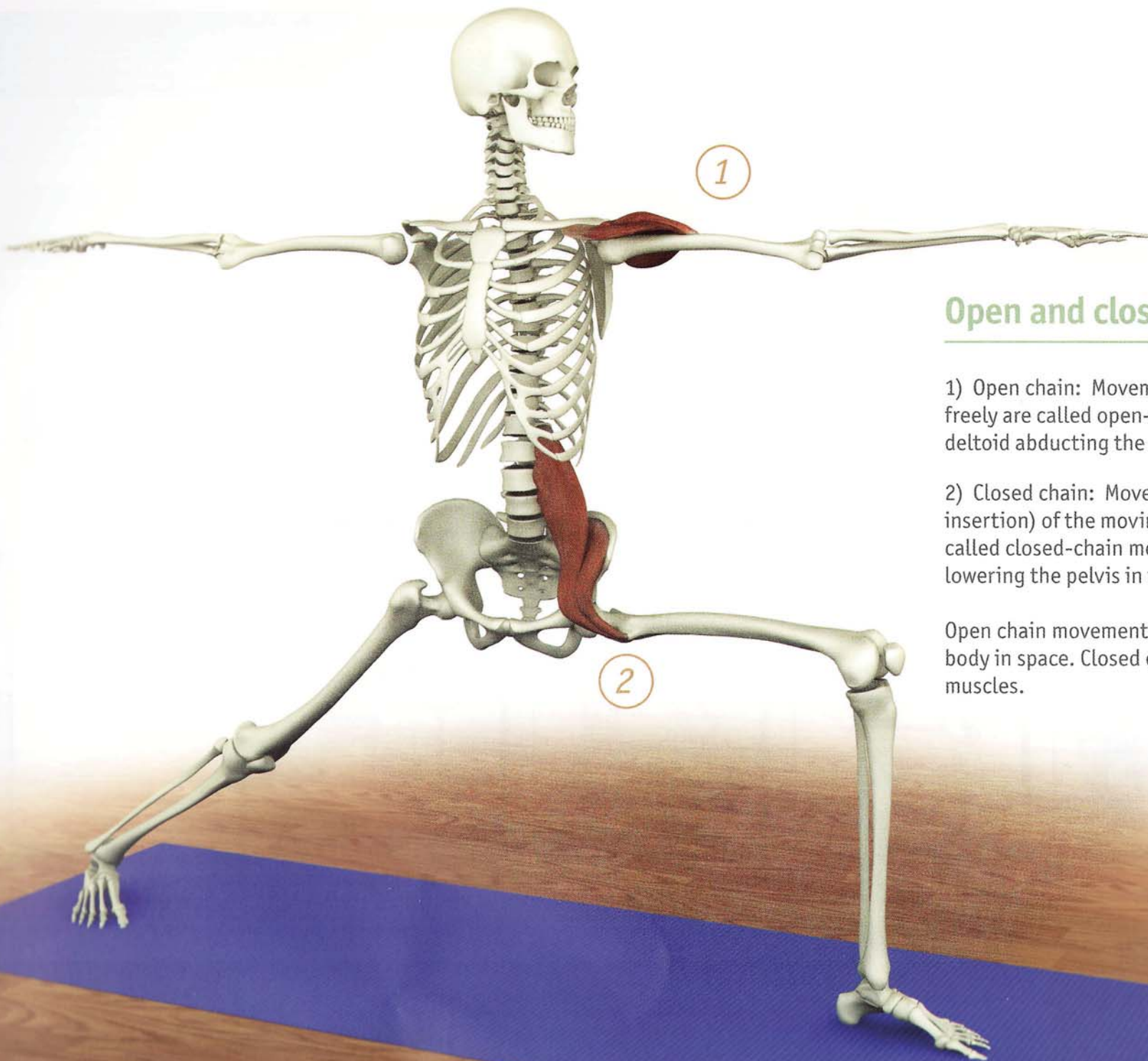
Coupling of Joints

Movement of adjacent joints in different planes is called coupled movement. For example, in the side bend of utthita trikonasana, the vertebral column undergoes a complex series of coupled movements, including rotation, flexion, and extension at various levels. Similarly, in the same pose, the position of the hip joint of the forward leg involves a combination of flexion of the femur (thigh bone) at the hip joint and forward tilt of the pelvis.

Complex Movements

In reality, and especially in yoga postures, movement can rarely be described in simple terms. Complex movements involve many joints moving in various ways. Complex movements are also described in terms of other characteristics, including coupling of joints and open and closed chain movements.





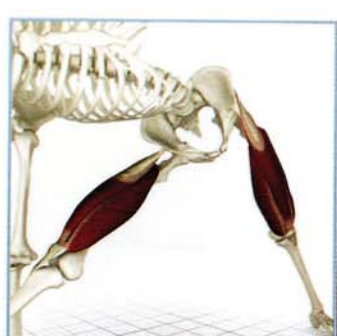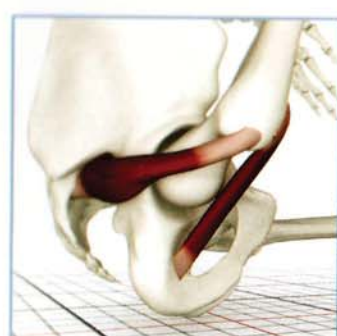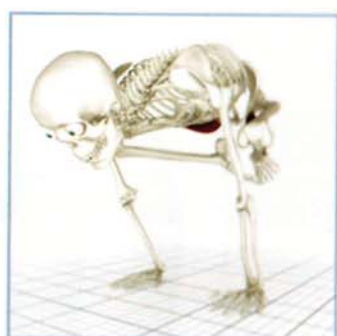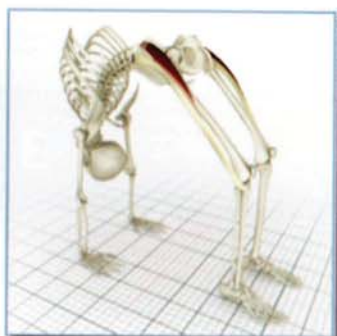
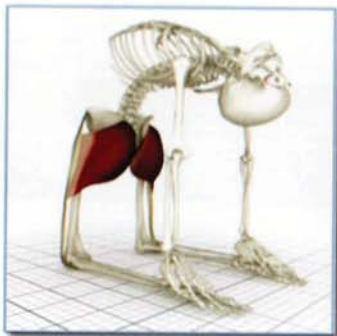Open and closed chain movements

- 1) Open chain: Movements in which the distal end moves freely are called open-chain movements (for example, the deltoid abducting the upper arms in virabhadrasana II).
- 2) Closed chain: Movements in which the distal end (the insertion) of the moving limb or body segment are fixed are called closed-chain movements (for example, the iliopsoas lowering the pelvis in virabhadrasana II).

Open chain movements teach balance and awareness of the body in space. Closed chain movements strengthen the core muscles.

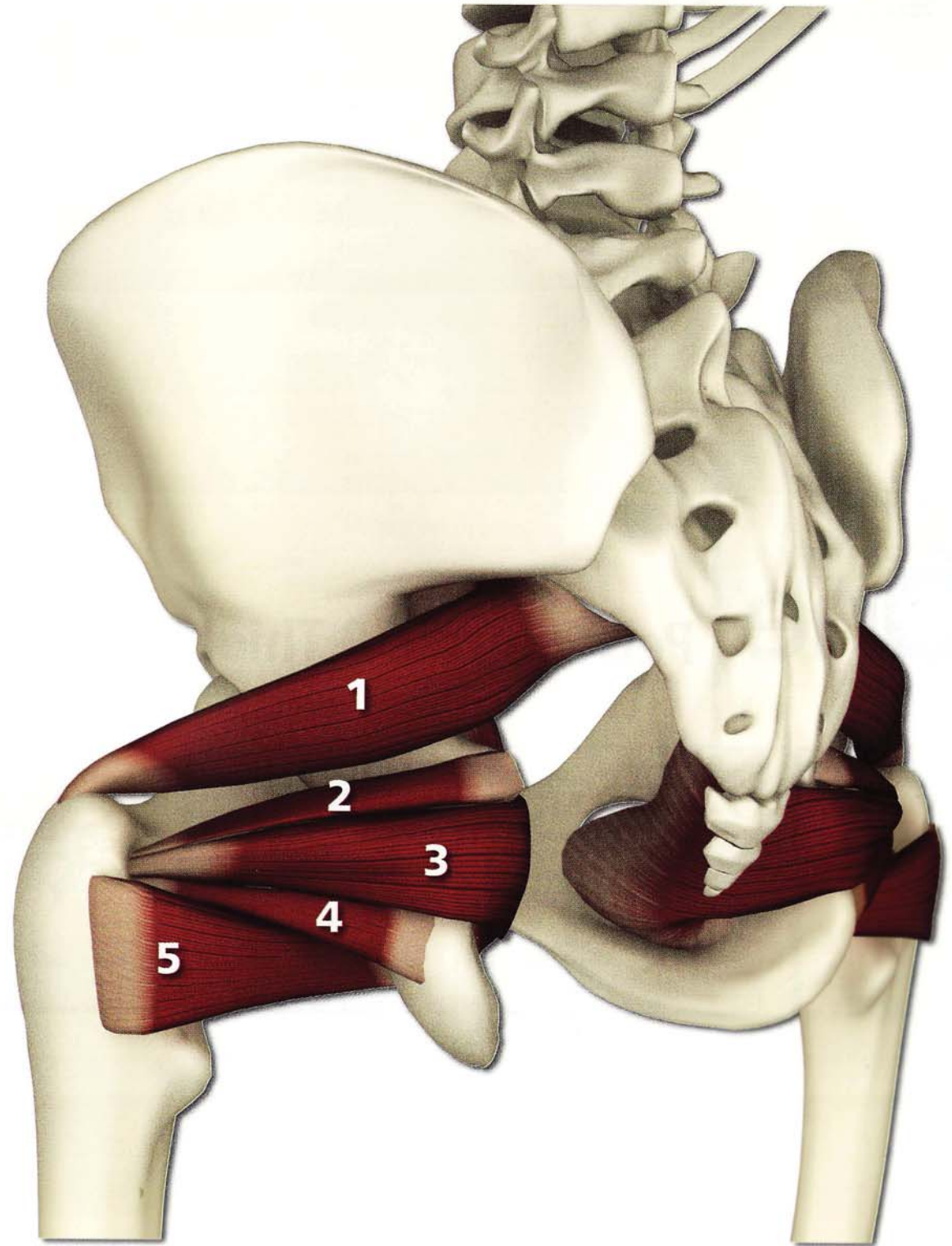
Part One

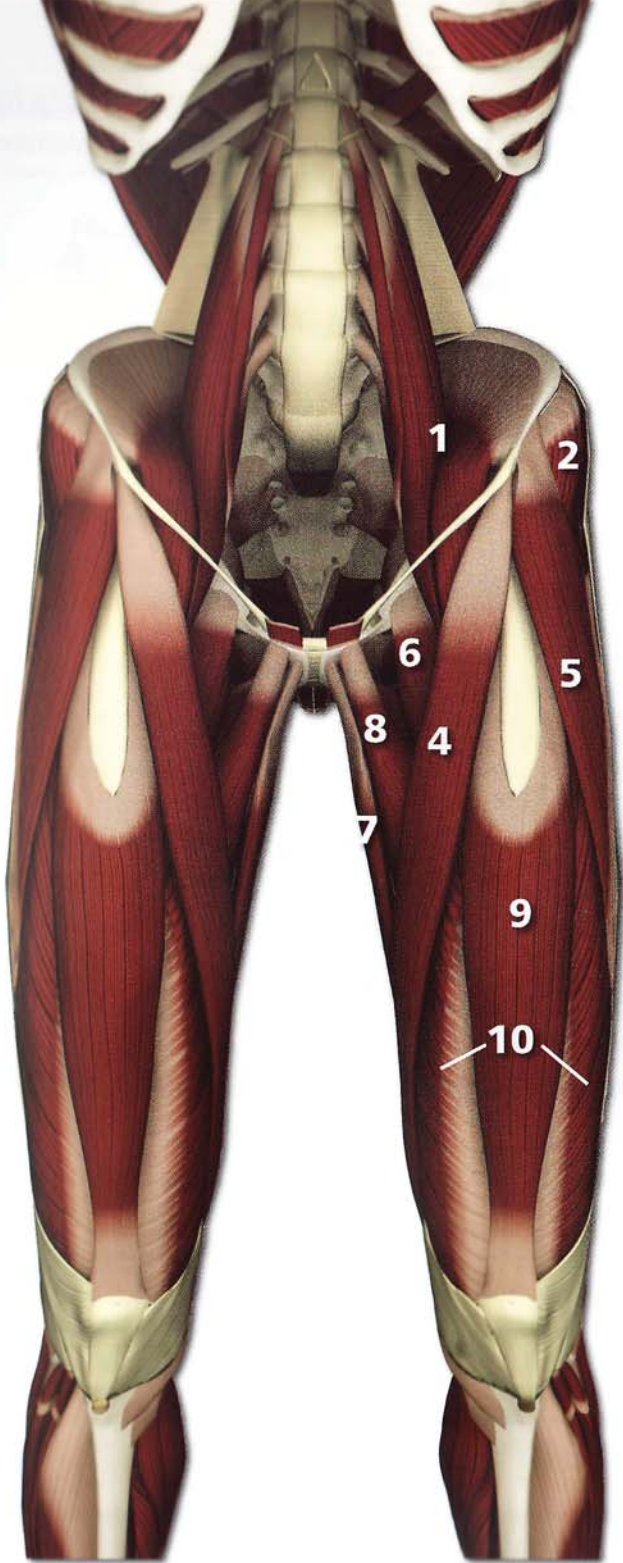
Pelvic Girdle & Thighs



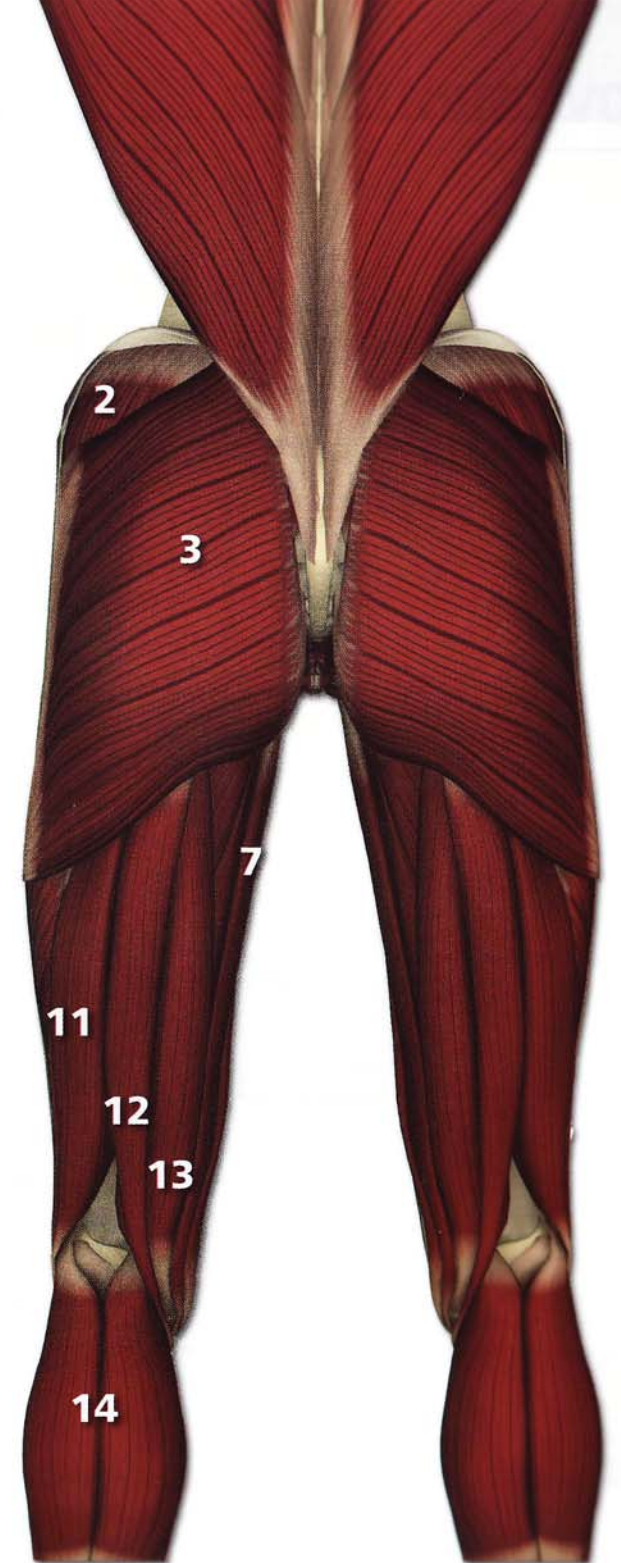
External rotators of the hip

- 1 piriformis
- 2 gemellus
- 3 obturator internus
- 4 obturator externus
- 5 quadratus femoris





- 1**
iliopsoas
- 2**
gluteus medius
- 3**
gluteus maximus
- 4**
sartorius
- 5**
tensor fascia lata
- 6**
pectineus
- 7**
gracilis
- 8**
adductor longus
- 9**
rectus femoris
- 10**
quadriceps
- 11**
biceps femoris
- 12**
semitendinosus
- 13**
semimembranosus
- 14**
gastrocnemius

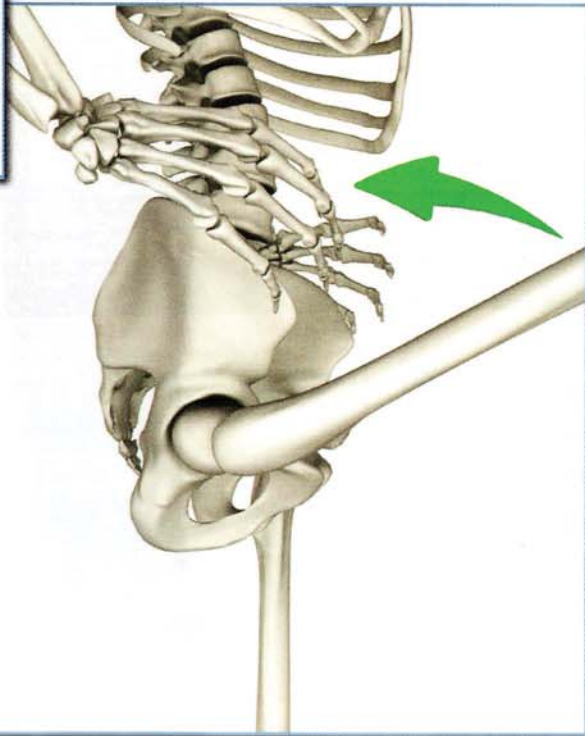
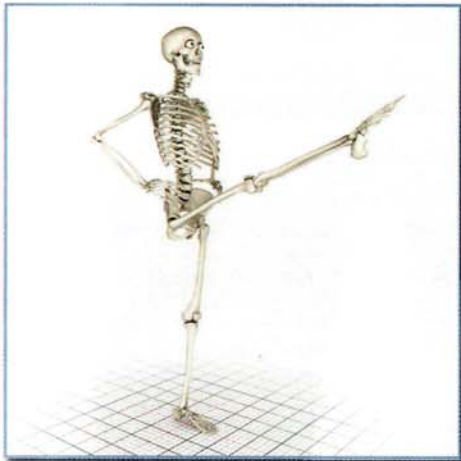

Movement: Hip

The following examples illustrate the elemental movements of the hip and pelvis. Look closely to appreciate the “coupling” of the movements of the hip joint and pelvis.

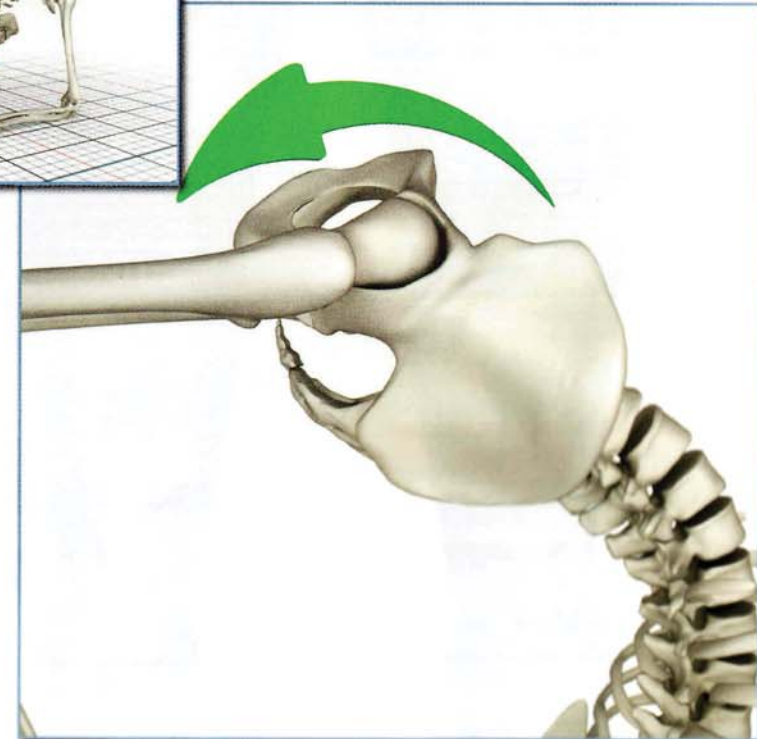

Flexion

Utthita Hasta Padangustasana



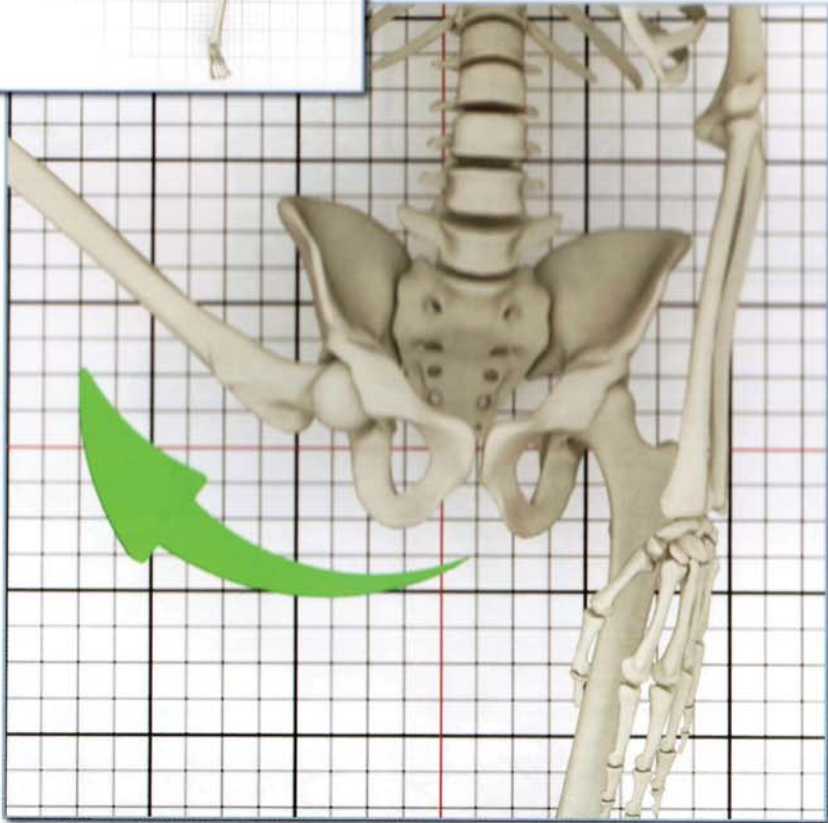
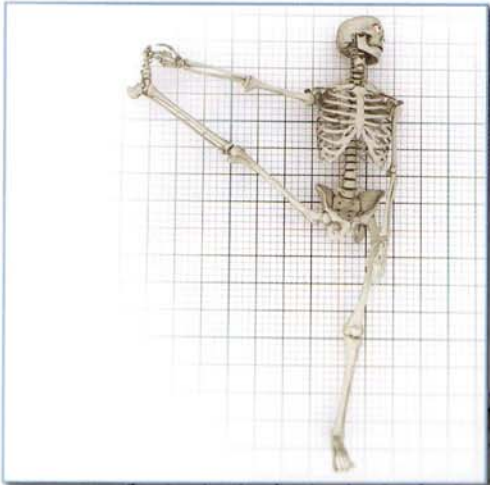
Extension

Vrishchikasana



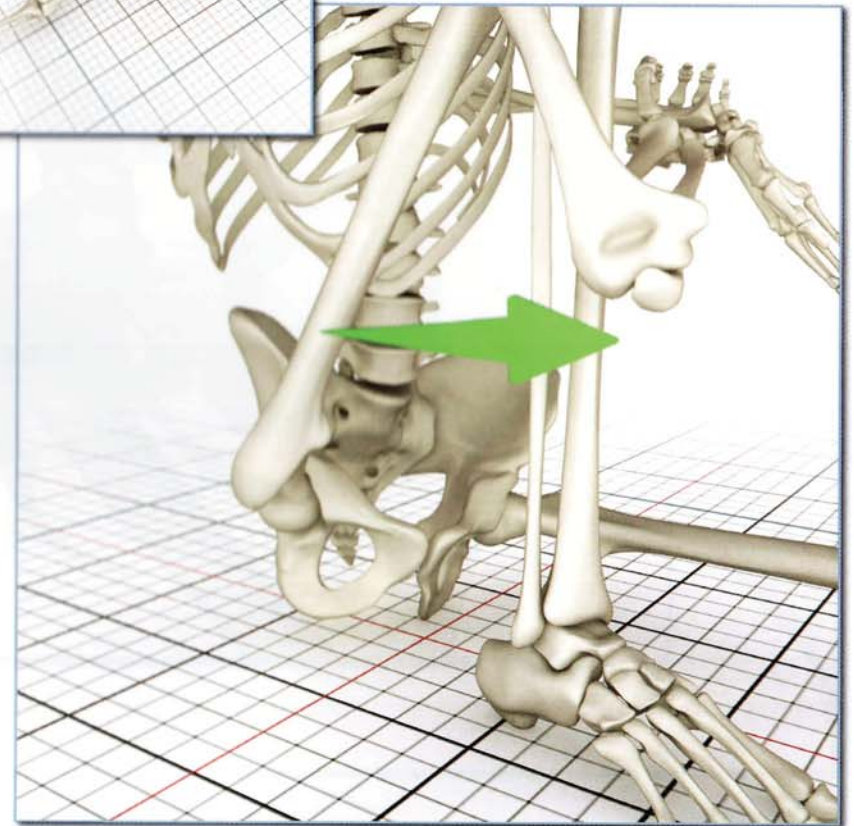
Abduction

(movement away from the midline)
Supta Padangusthasana B



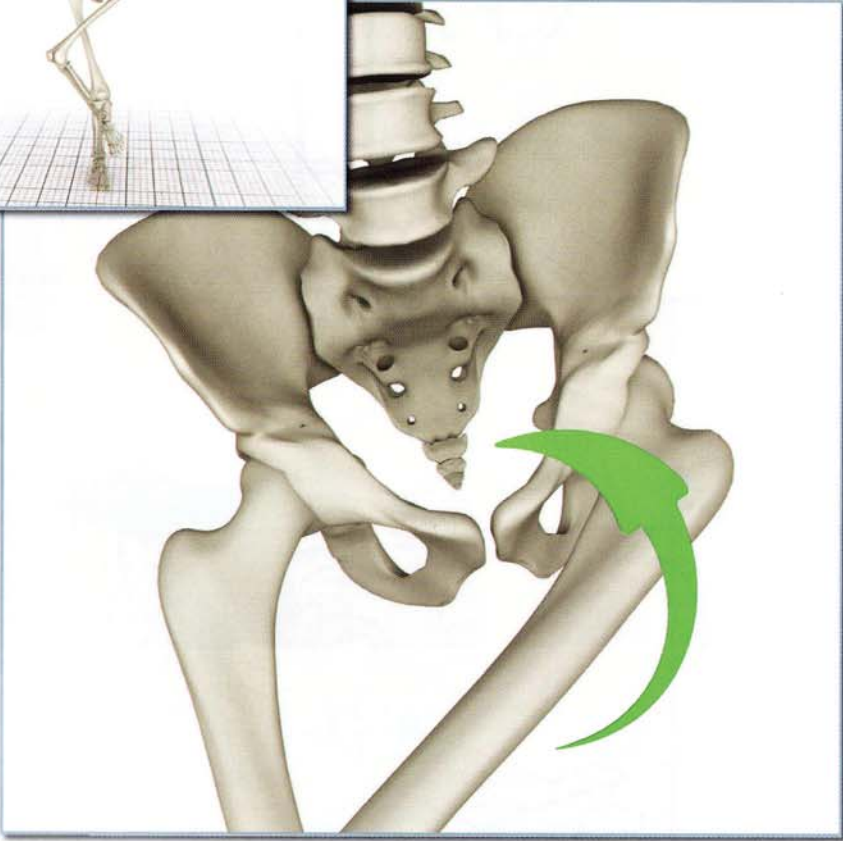
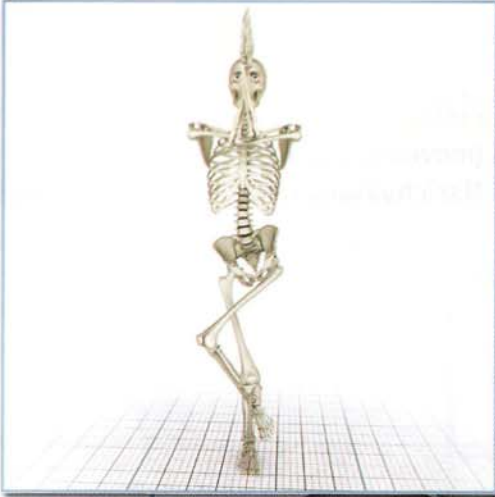Adduction

(movement towards the midline)
Marichyasana C

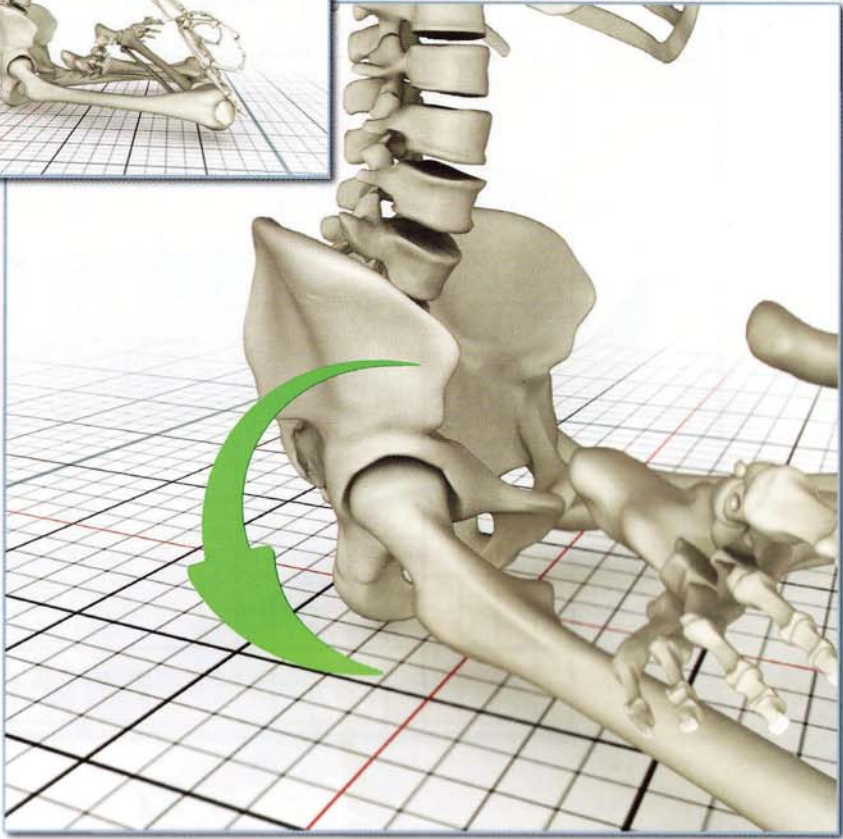


Movement: Hip

*Internal Rotation
Garudasana*

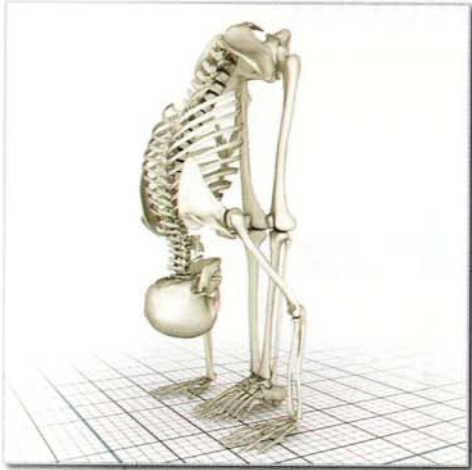

*External Rotation
Padmasana*

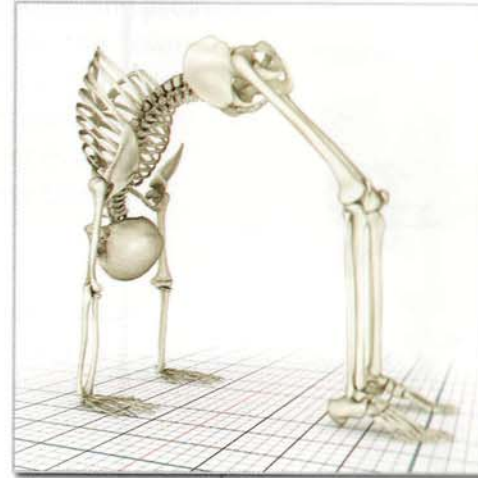

Movement: Pelvis

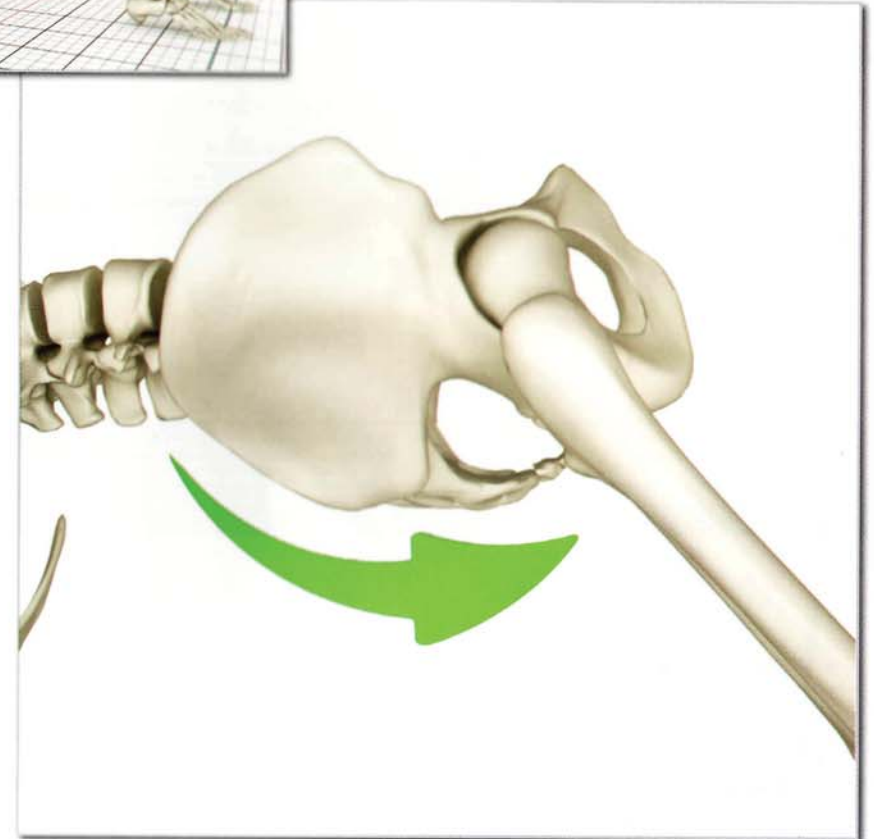
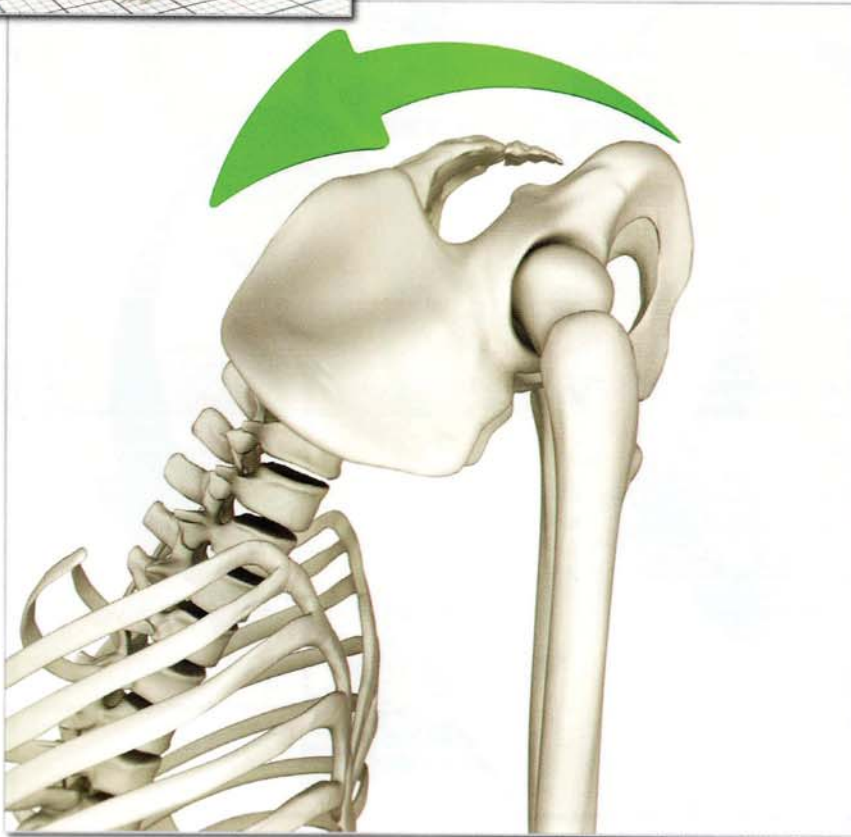Movement: Pelvis



*Anterior Tilt
Utthanasana*

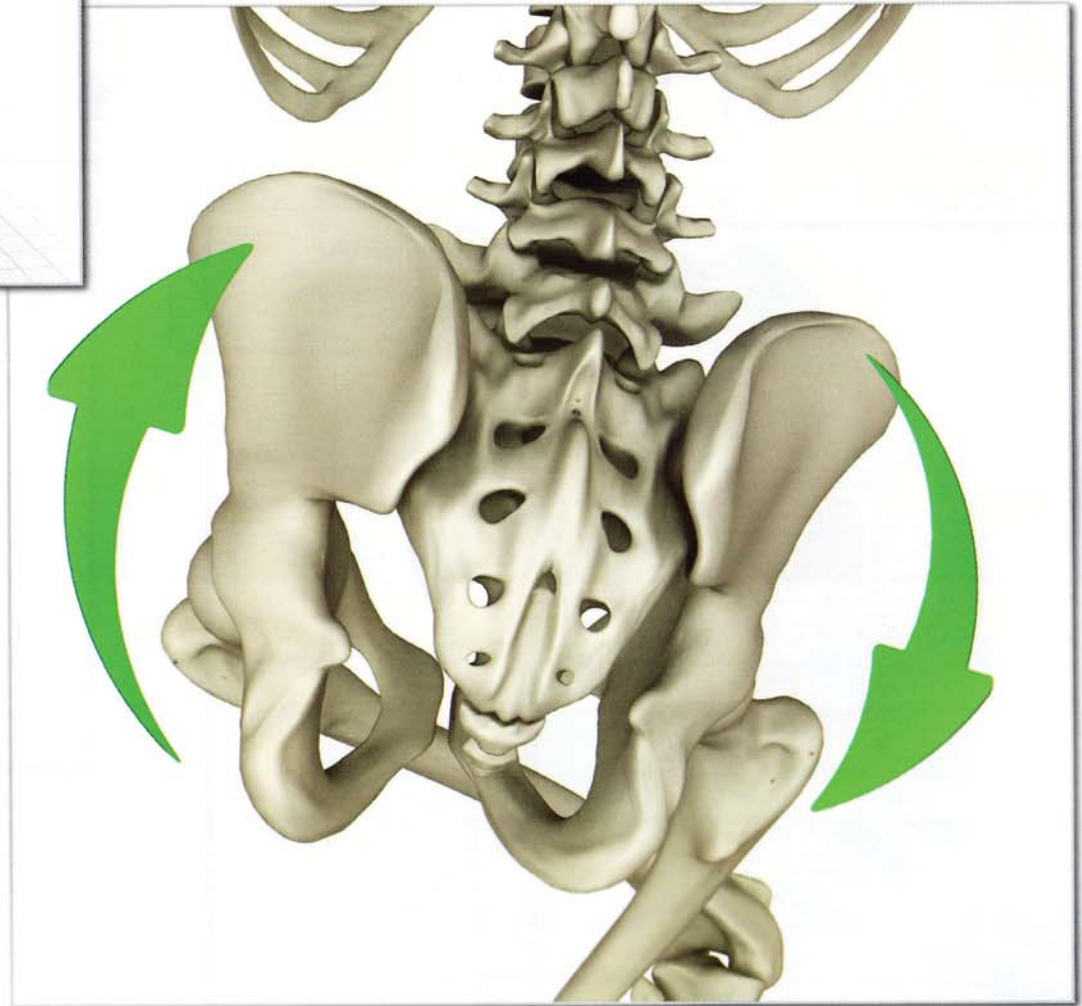
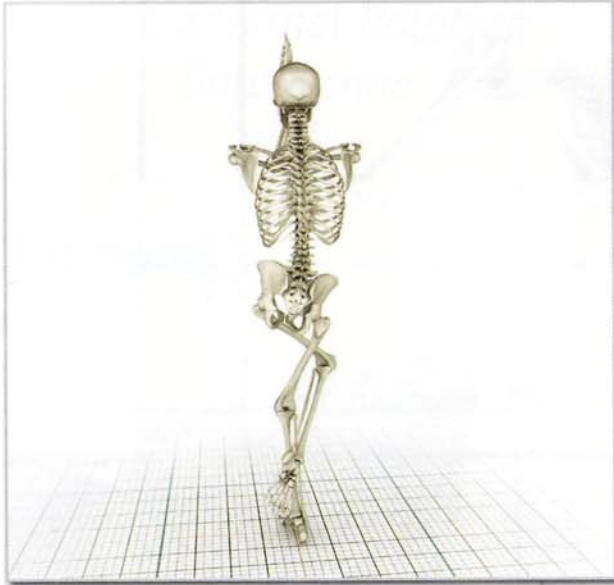


*Posterior Tilt
Urdhavadhanurasana*



Movement: Pelvis

*Rotation
Garudasana*

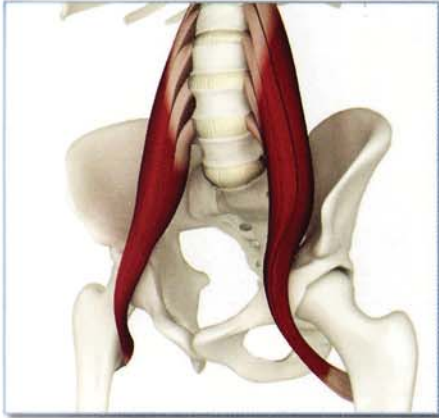

Chapter 1

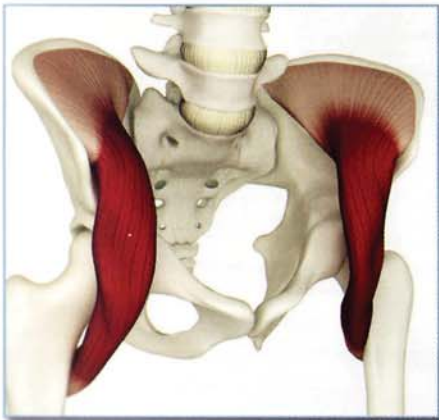Iliopsoas

Also known as the psoas muscle, the iliopsoas is actually a combination of two large muscles: the psoas major and the iliacus. The psoas major muscle originates in the lower back; the iliacus originates on the inside of the pelvis. Both muscles combine to form one tendon that attaches to the inside of the proximal femur bone.

psoas major



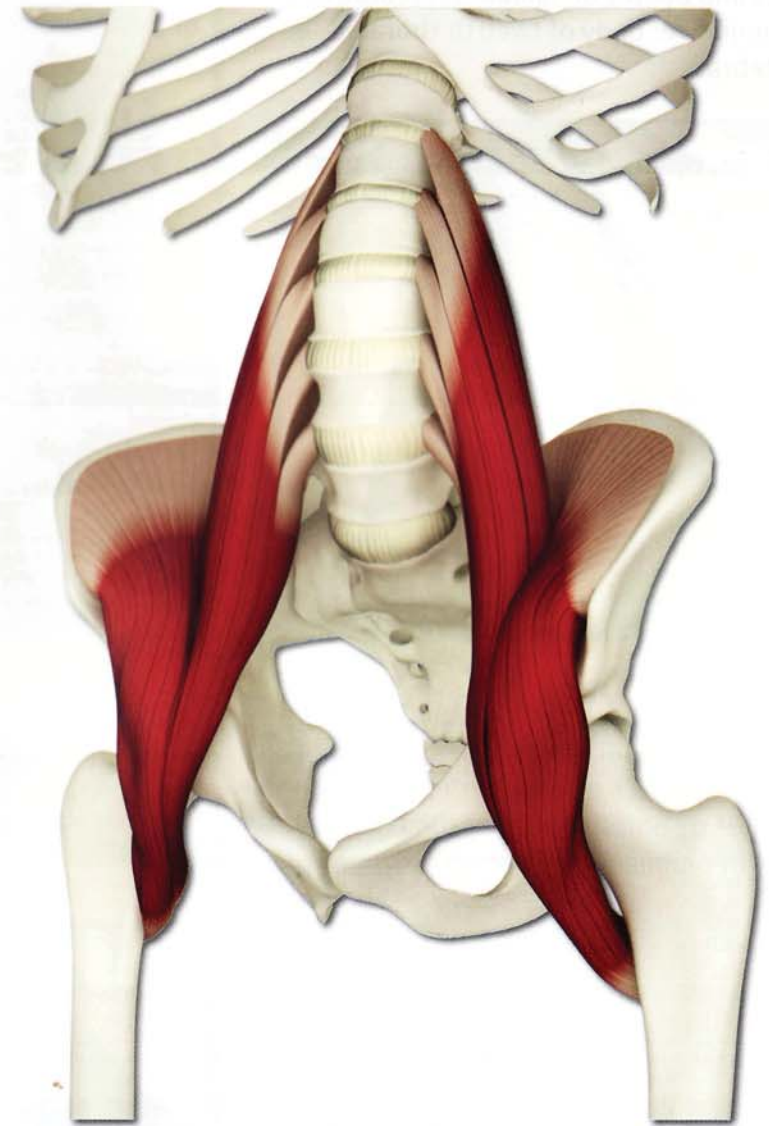
iliacus



The iliopsoas is thus called polyarticular. This means that it crosses over (and moves) more than one joint. The iliopsoas also acts like a pulley as it curves over the front rim of the pelvis on its way to the femur. Like other pulley systems, this serves to multiply the force generated when the iliopsoas contracts. The iliopsoas thus moves the bones of the lower back, pelvis and hip in a coupled fashion. This means that when it contracts, a combination of movements across several joints is possible.

The iliopsoas first awakens during infancy when we are learning to sit up and then to walk. Once awakened, the iliopsoas becomes constantly active in activities such as standing and walking. In spite of this constant use, our awareness of the iliopsoas quickly becomes unconscious. (Imagine if we had to think every time we took a step!)

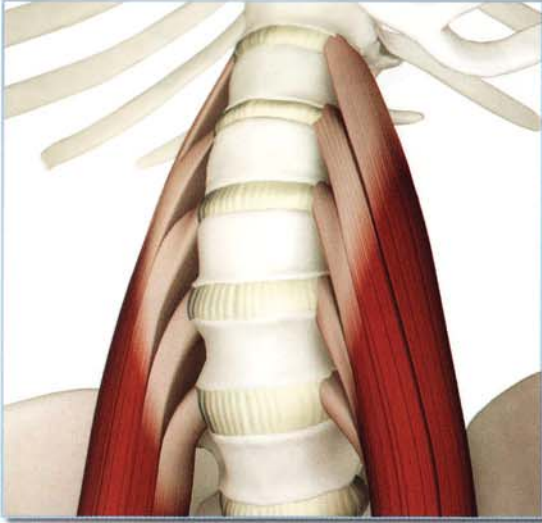
Hatha yoga can be used to reawaken our consciousness of this large and important muscle. Once you awaken the iliopsoas, contract or relax it to transform and deepen your asanas.



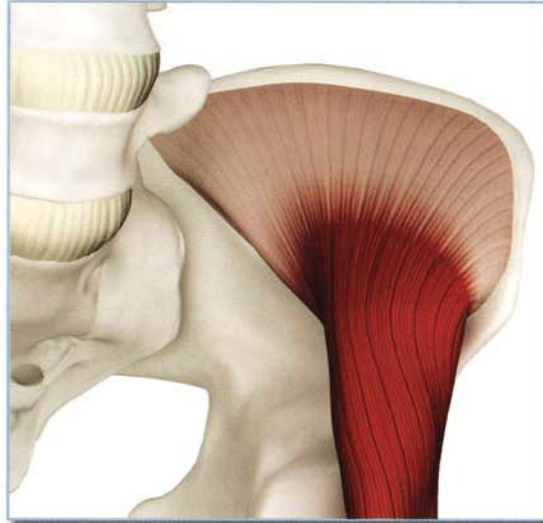iliopsoas

Origin

1) Psoas major: Tranverse processes, discs and bodies of lumbar vertebrae one through five; body of twelfth thoracic vertebra.

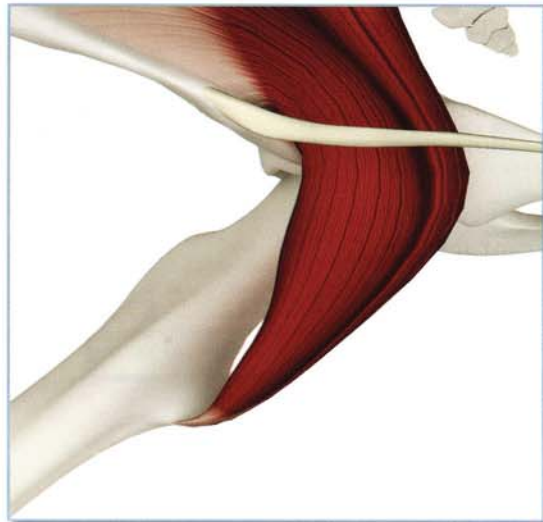


2) Iliacus: Upper two thirds of the inside surface of the iliac bone up to the inner lip of the iliac crest and anterior sacroiliac joint.



Insertion

Lesser trochanter (the smaller prominence or knob) of the proximal femur.

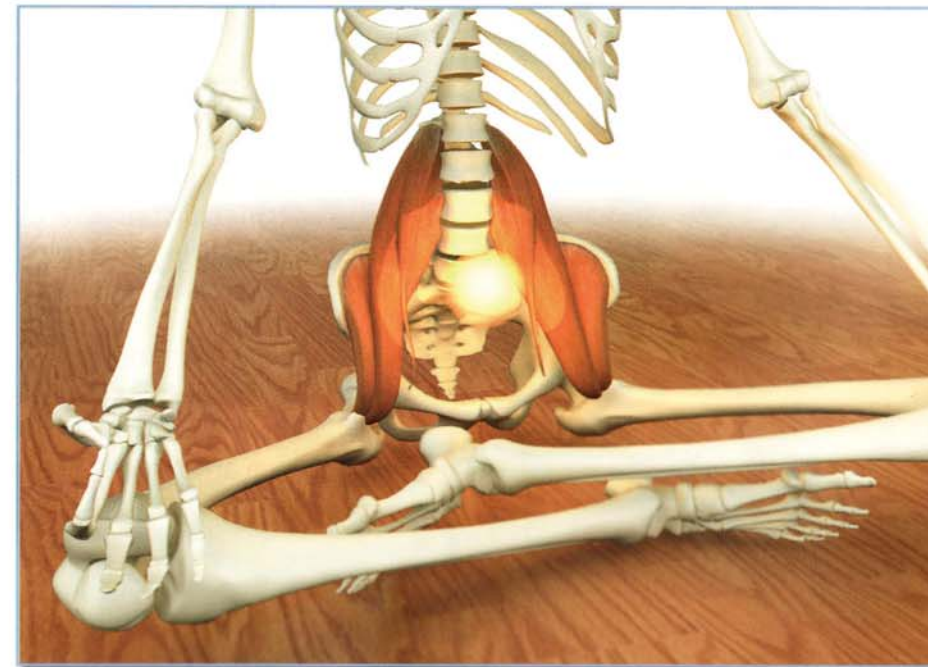
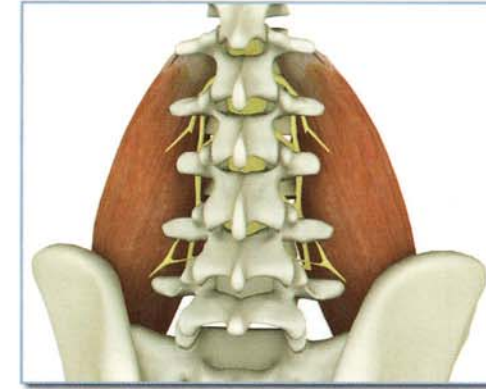

Innervation & chakra illuminated

Lumbar nerves 1,2,3,4

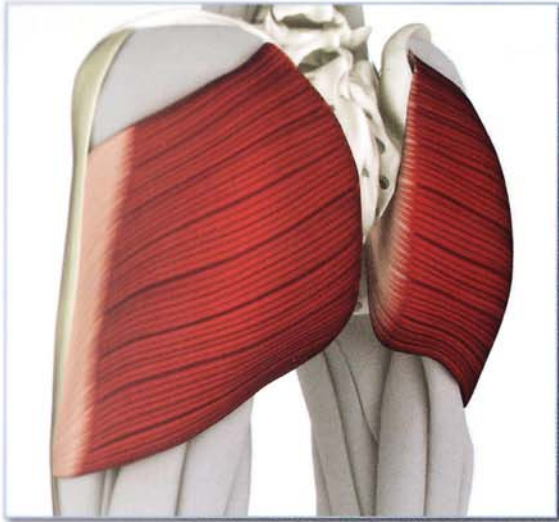
Chakra: Second

The second chakra is illuminated by contracting and lengthening the iliopsoas muscle. This is due to stimulation of the various sensory nerves at its origin and insertion, within the muscle itself, and the skin surrounding it.

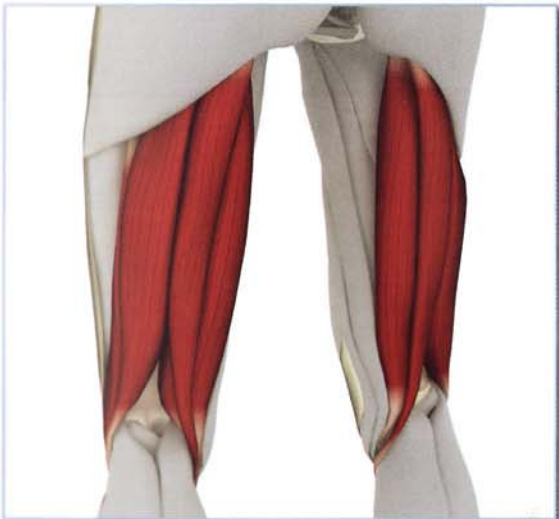

Iliopsoas (il-e-o-SO-us)

Antagonists

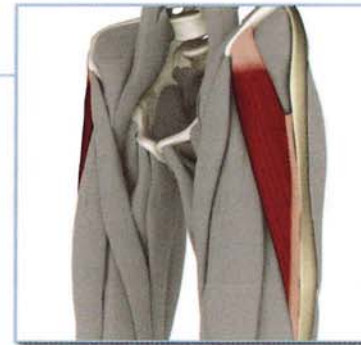


Gluteus maximus: extends hip and trunk resulting in lengthening and stretching of the Iliopsoas, particularly in backbends.

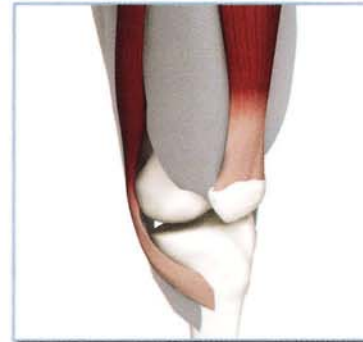

Hamstrings: extends the hip when initiating backbends, can be used to draw the opposite leg iliopsoas into a deeper stretch in lunging postures.

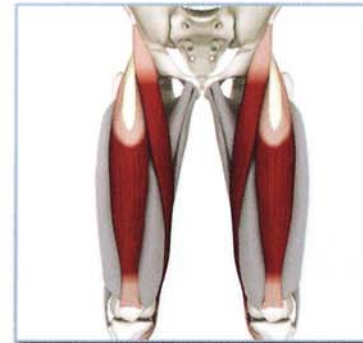Synergists



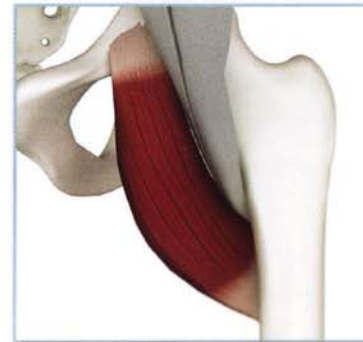Tensor fascia lata: assists the iliopsoas in fine-tuning hip flexion.



Sartorius: assists the iliopsoas in fine-tuning hip flexion and external rotation.



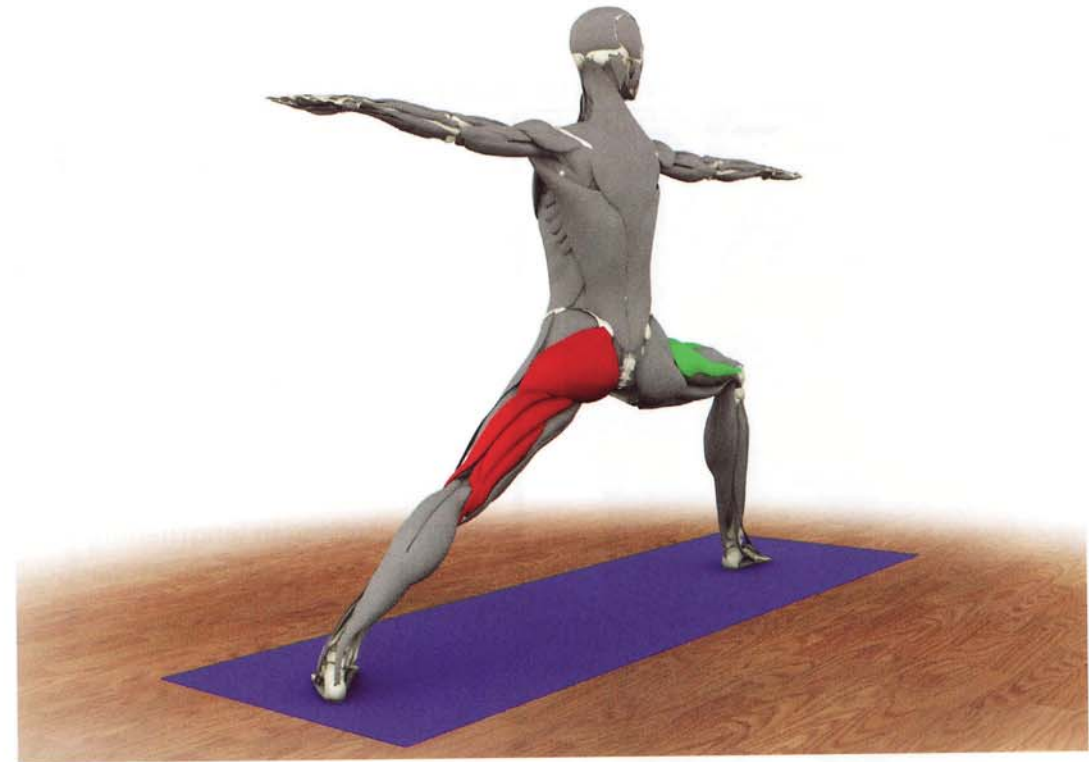
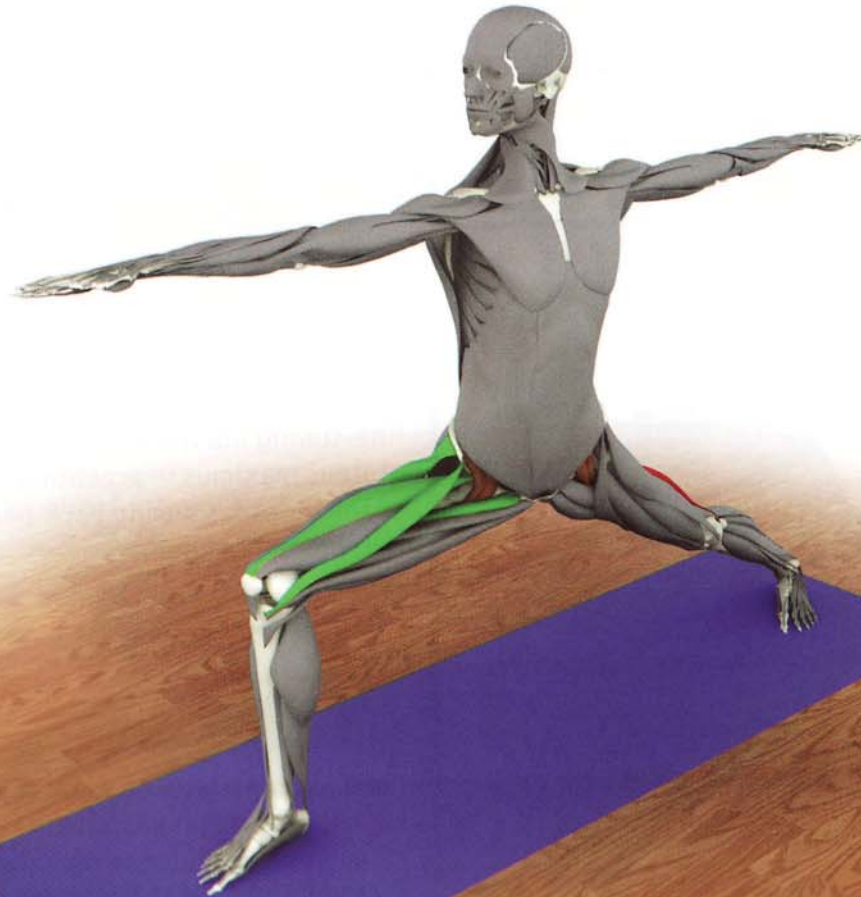
Rectus femoris: assists the iliopsoas in fine-tuning hip flexion, also assists the gluteus maximus in accentuating stretch of the iliopsoas during back-bending (by extending the knee).



Pectineus: assists the iliopsoas in fine-tuning hip flexion and provides adduction component to stabilize hip (also balances abduction action of sartorius).

Synergy

This illustration uses virabhadrasana II to demonstrate the tensor fascia lata, sartorius, rectus femoris, and pectineus as synergists of the psoas. Similarly, the extended back hip demonstrates how the gluteus maximus and hamstrings act as antagonists to the psoas.



virabhadrasana II

Synergy

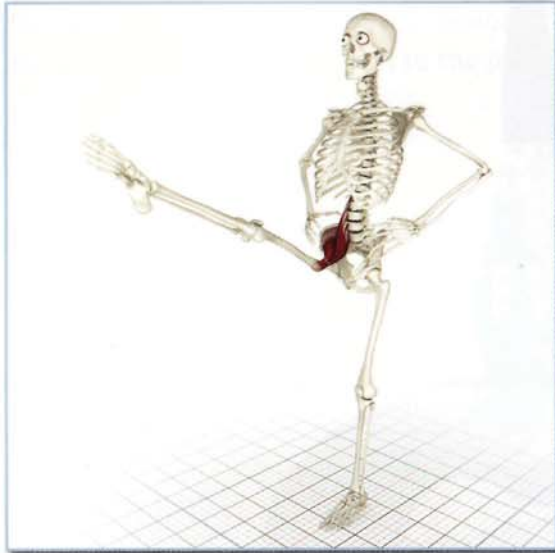This illustration uses eka pada viparita dandasana to demonstrate the gluteus maximus and hamstrings stretching the psoas and the synergists of the psoas in the planted leg. Similarly, the flexed hip of the leg in the air demonstrates the tensor fascia lata, sartorius, rectus femoris and pectineus as synergists of the psoas.



eka pada viparita dandasana

Iliopsoas (il-e-o-SO-us)

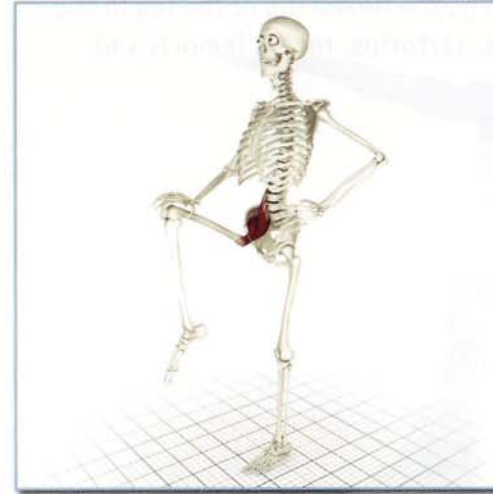
Action



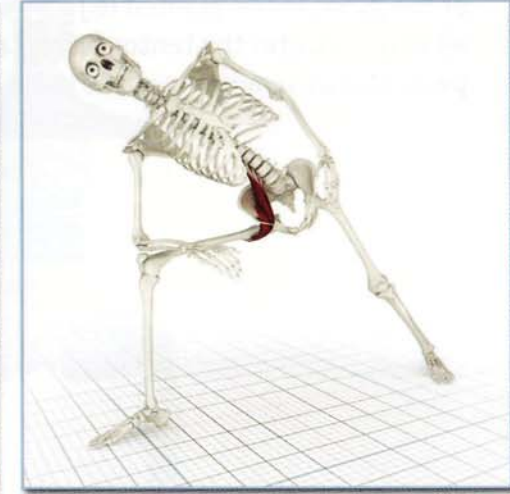
Open chain
(Origin fixed, insertion moving):

Flexes and laterally rotates the femur at the hip. Ex. Padangusthasana D

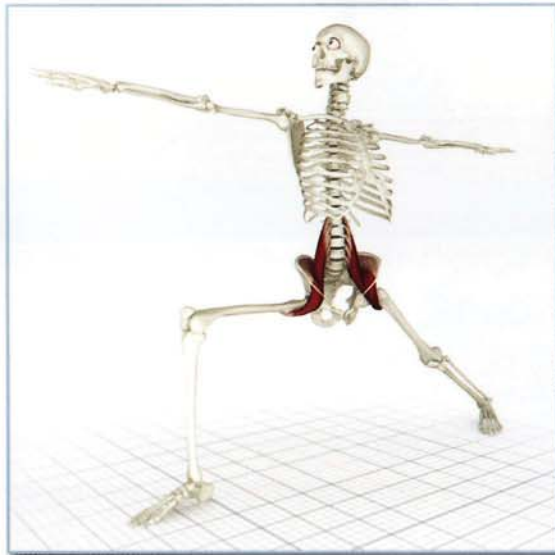Awakening



Open chain isometric resistance to femur flexing.

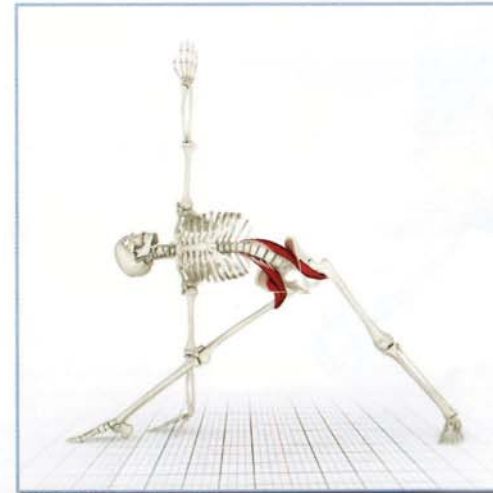


Closed chain isometric resistance to trunk flexing.

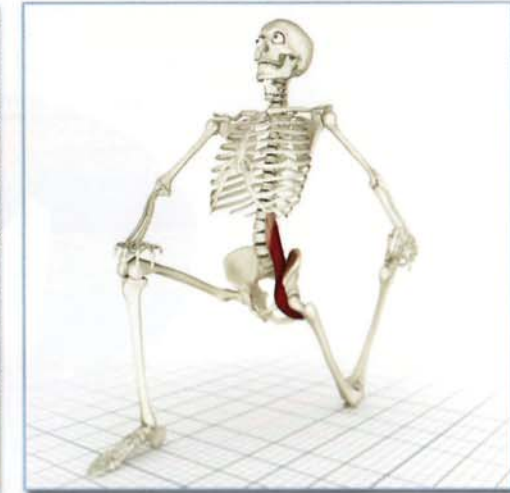

Closed chain
(Insertion fixed, origin moving):

Flexes the trunk, anteverts (tilts forward) the pelvis, straightens and supports the lumbar spine. Ex. Virabhadrasana B



Conscious contraction in standing poses.

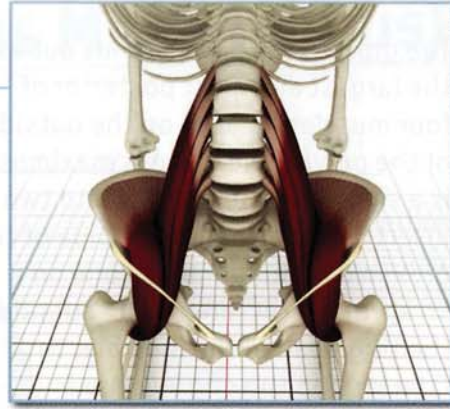
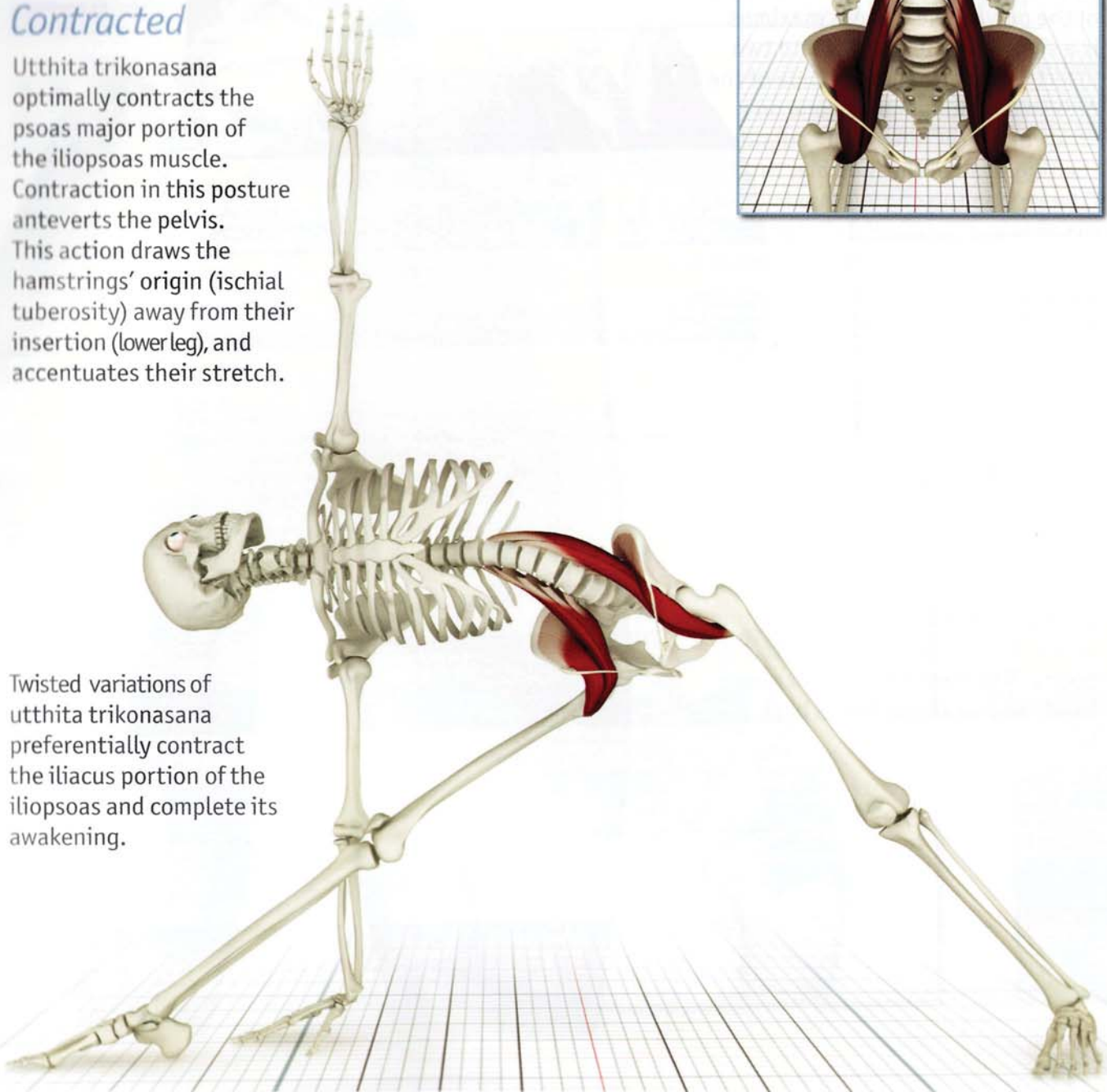


Eccentric contraction in lunging poses.

Contracted

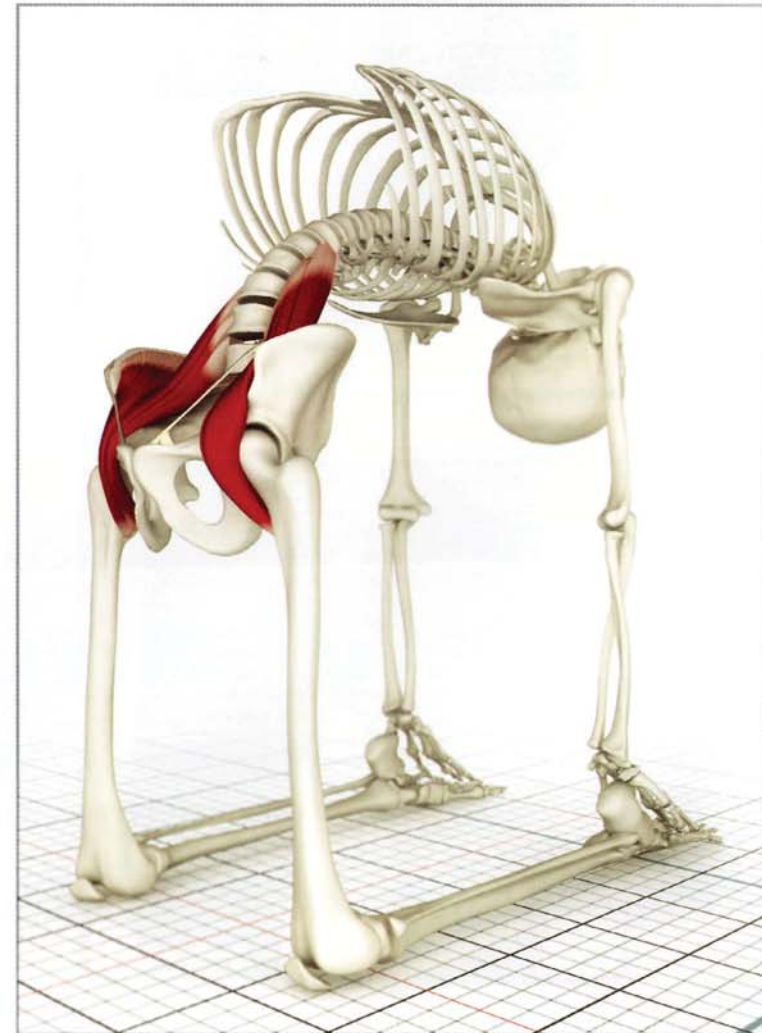
Utthita trikonasana optimally contracts the psoas major portion of the iliopsoas muscle. Contraction in this posture anteverts the pelvis. This action draws the hamstrings' origin (ischial tuberosity) away from their insertion (lower leg), and accentuates their stretch.

Twisted variations of utthita trikonasana preferentially contract the iliacus portion of the iliopsoas and complete its awakening.



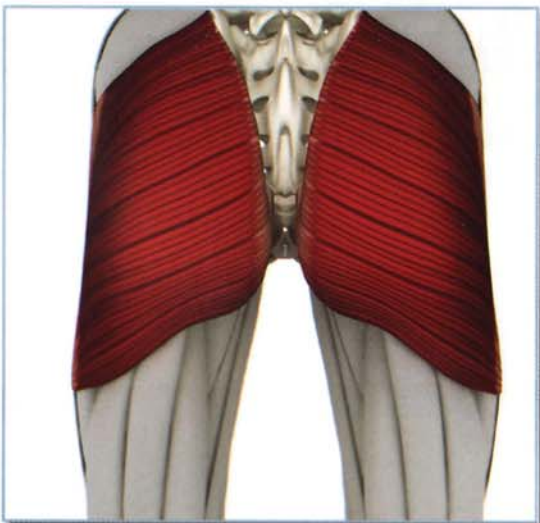
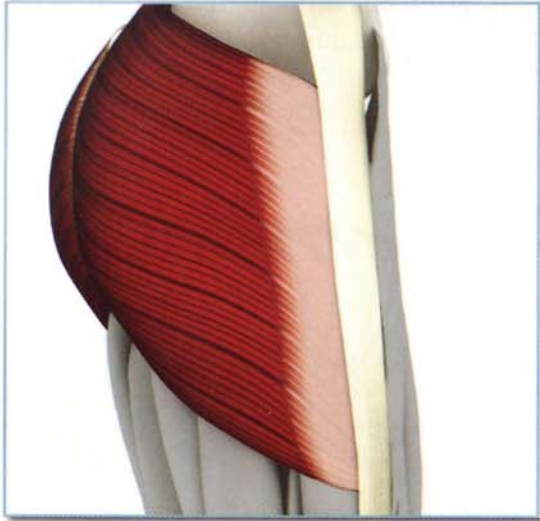
Stretched

Ushtrasana stretches the iliopsoas through contraction of the hip and trunk extensors, including the gluteus maximus. Stretch is accentuated by contraction of the quadriceps (including the rectus femoris, which is eccentrically contracted).



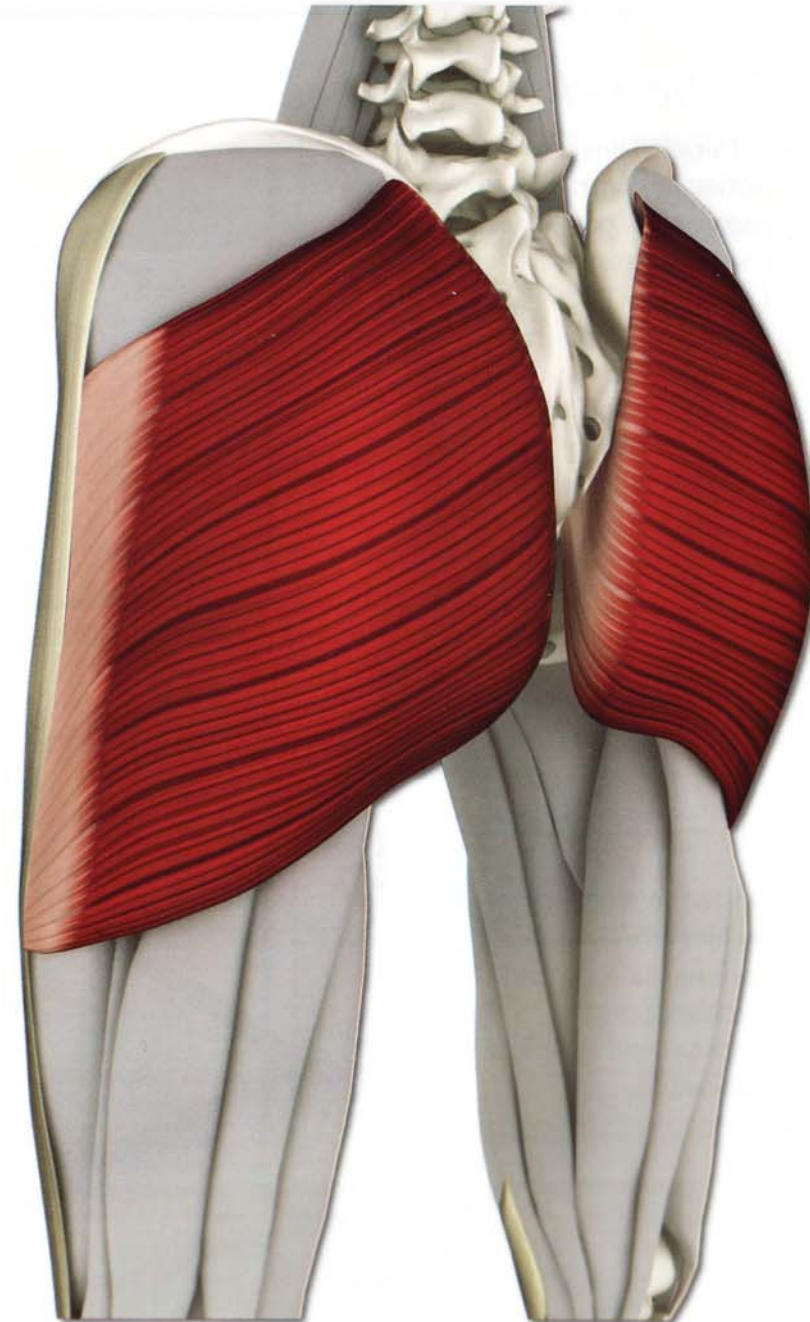
Chapter 2

Gluteus Maximus



The gluteus maximus stands out as the largest and most posterior of four muscles located on the outside of the pelvis. The gluteus maximus is a single muscle divided into two insertions: one on the outside of the proximal femur bone and one on a strap-like structure on the outside of the thigh called the iliotibial band. Contracting the gluteus maximus extends and outwardly rotates the femur. Fibers attached to the iliotibial band tense it and assist in moving the knee. The gluteus maximus functions as a mono- and polyarticular muscle. Tightness of the gluteus maximus limits forward bending at the hips, such as in utthanasana.

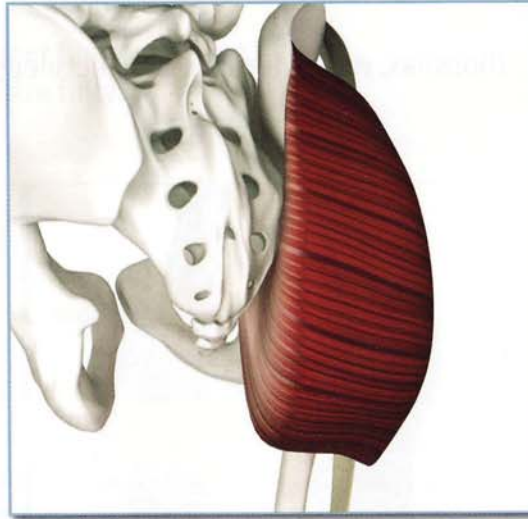
Like the iliopsoas, the gluteus maximus works unconsciously during standing and walking. Many important yoga postures awaken the gluteus maximus including standing poses, backbends and forward bends. Tightness limits forward bends and weakness limits back bends.



Gluteus Maximus (GL00-te-us MAK-si-mus)

Origin

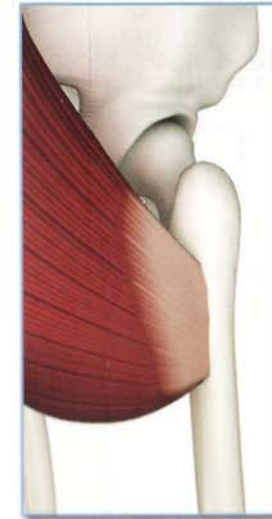
Outer posterior surface of the ilium, posterior surface of the sacrum and coccyx, and the aponeurosis of the erector spinae muscles of the back.



Insertion

1) Gluteal tuberosity on lateral surface of the proximal femur below the greater trochanter.

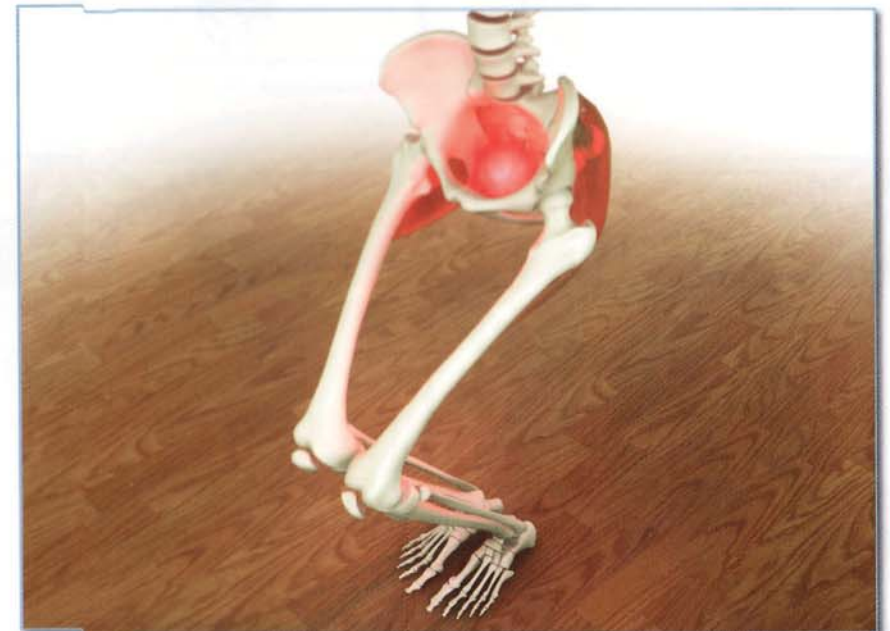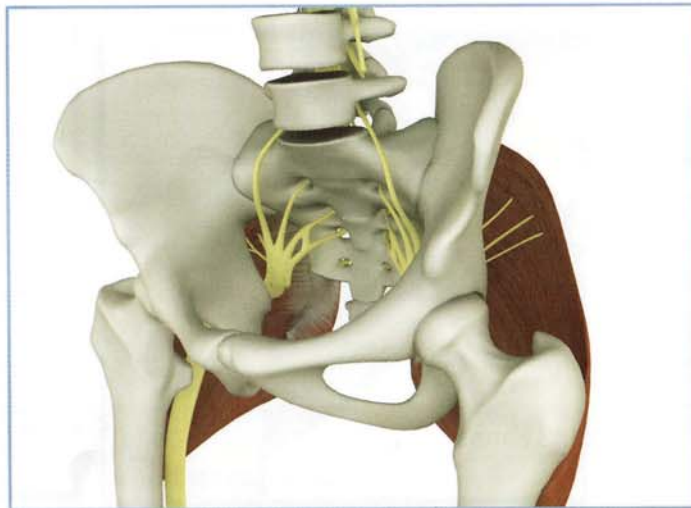
2) Iliotibial band (inserts onto Gerdy's tubercle on the front of the proximal tibia).



Innervation & chakra illuminated

Inferior gluteal nerve (lumbar spinal nerve 5 and sacral spinal nerves 1 and 2).

Chakra illuminated: First.



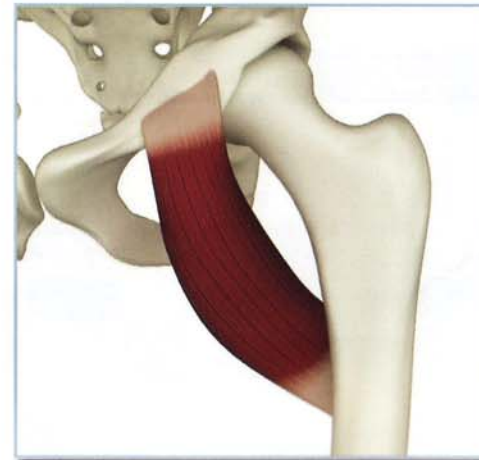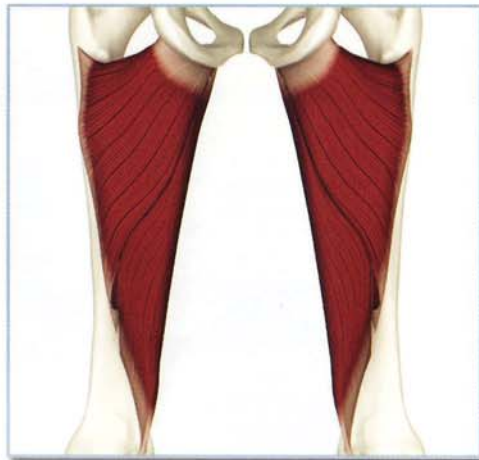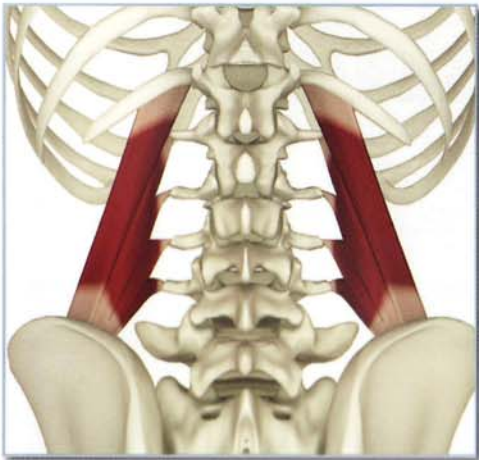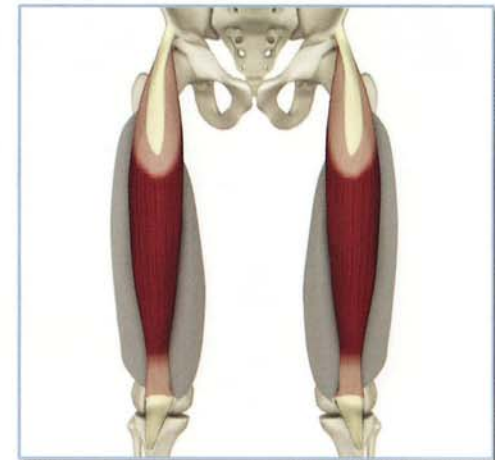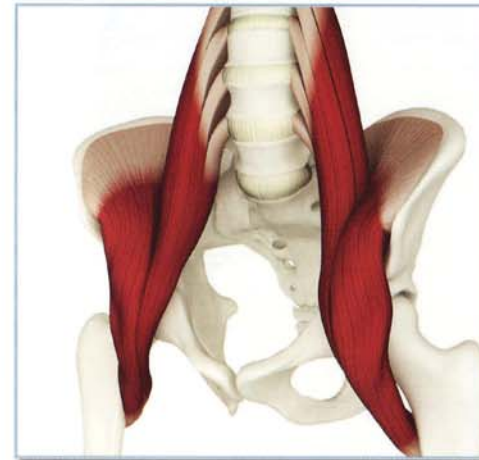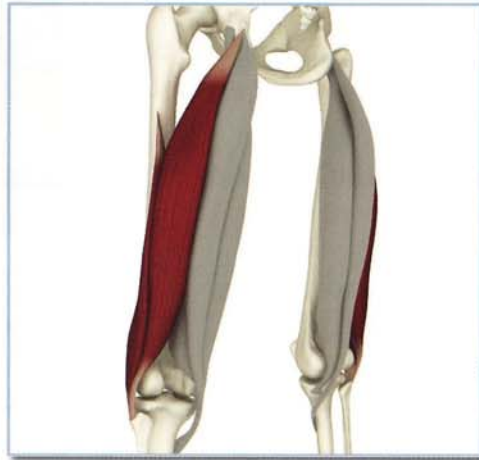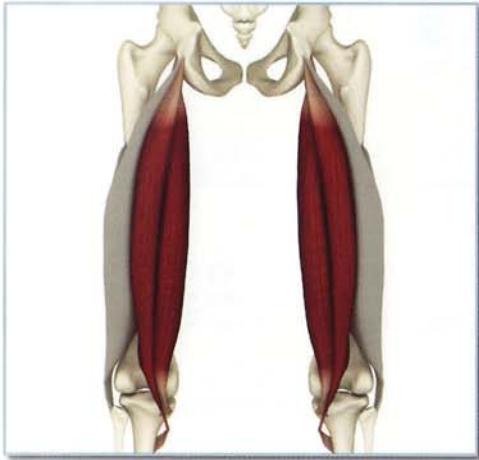Gluteus Maximus (GL00-te-us MAK-si-mus)

Synergists

Semimembranosis, semitendinosis, biceps femoris, quadratus lumborum and adductor magnus.

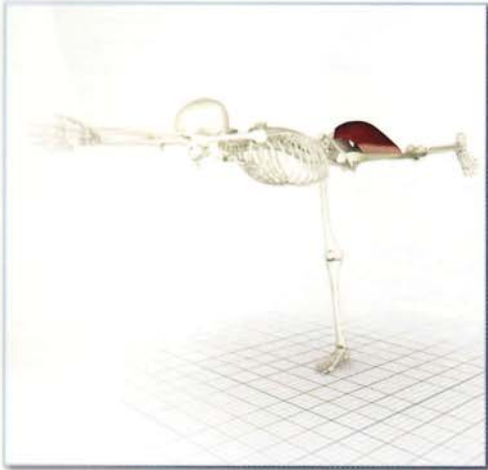
Antagonists

Iliopsoas, rectus femoris and pectineus.



Action

Extends and externally rotates hip. Upper fibers assist to abduct thigh. Assists to stabilize fully extended knee (via iliotibial band).



Open chain contraction extends and externally rotates the hip joint.

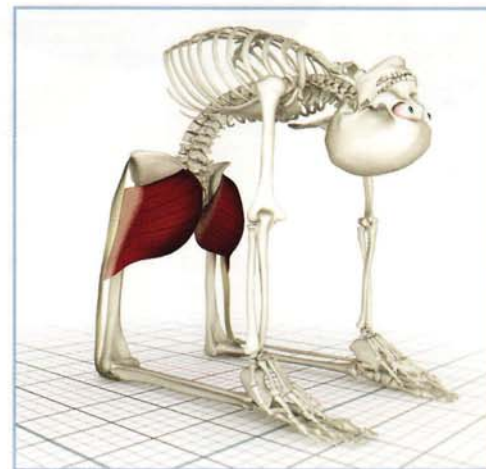
Contracting the gluteus maximus lifts and externally rotates the back leg in virabhadrasana III. The fibers inserting on the iliotibial band also assist in stabilizing the straight knee.



Closed chain contraction extends trunk in virabhadrasana II.

Awakening

The gluteus maximus can be eccentrically contracted in padangustasana, stretching and strengthening it.

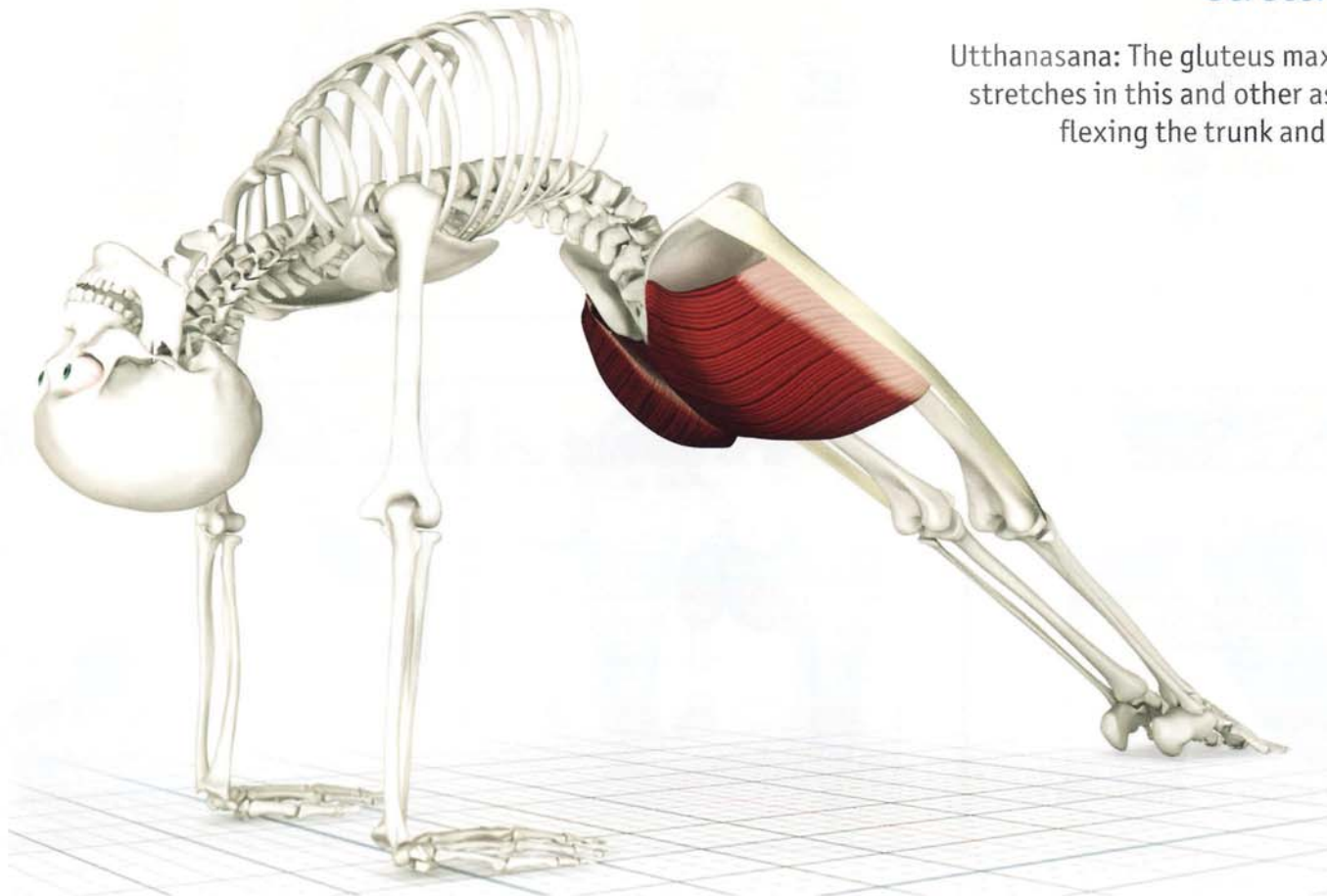


Closed chain contraction of the gluteus maximus in ushtrasana extends the trunk.

Gluteus Maximus (GL00-te-us MAK-si-mus)

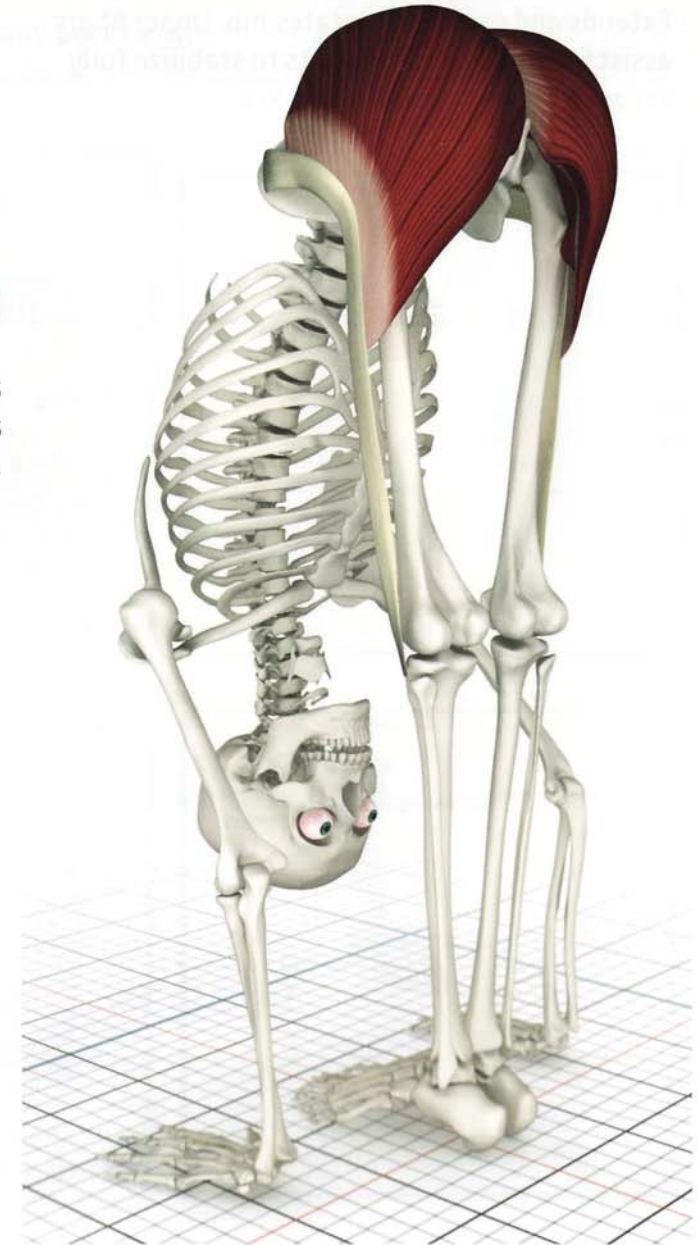
Contracted

Purvottanasana: The gluteus maximus contracts in this asana. Its external rotation component is counteracted by contraction of the gluteus medius (anterior fibers), tensor fascia lata and adductor group. (Accentuate this by pressing down the ball of the foot.)



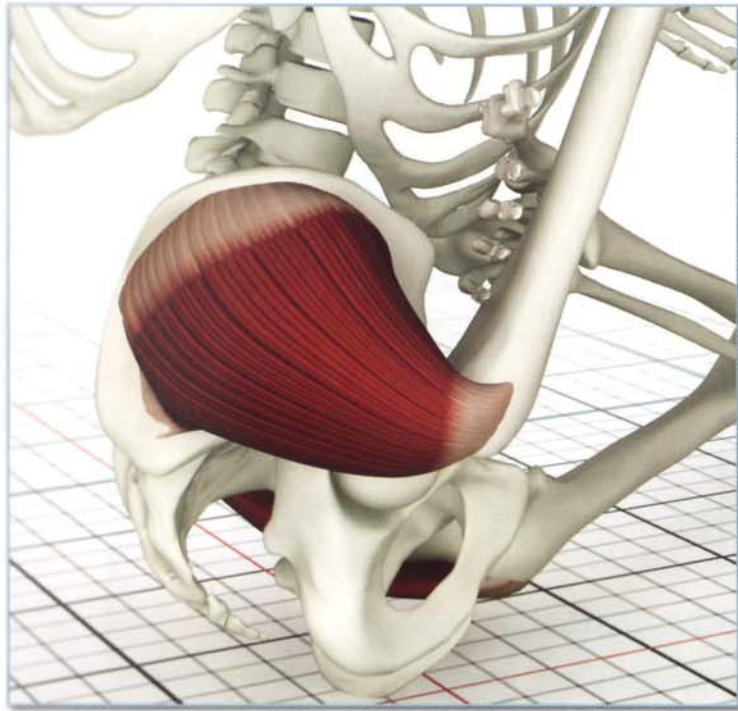
Stretched

Utthanasana: The gluteus maximus stretches in this and other asanas flexing the trunk and hips.



Chapter 3

Gluteus Medius

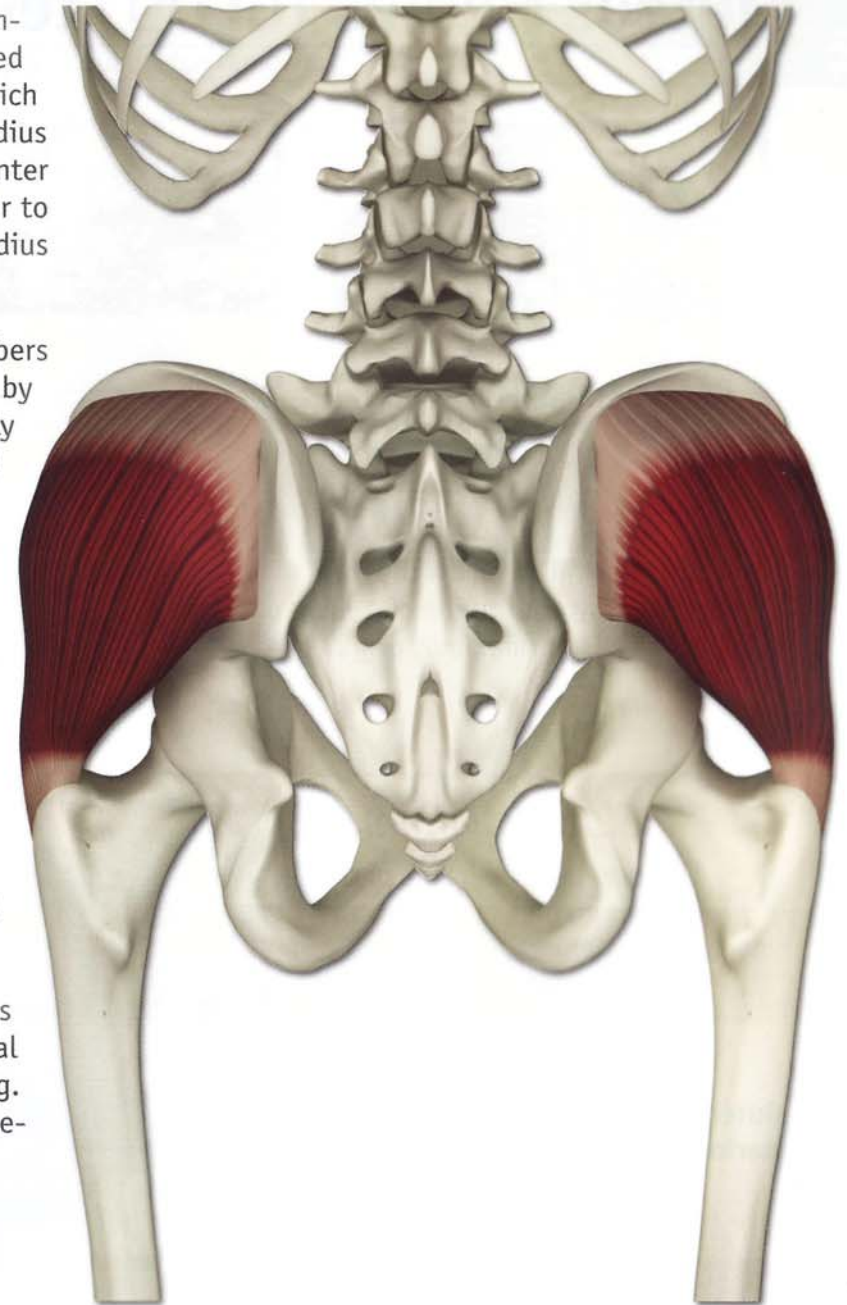


The gluteus medius presents a medium-sized, fan-shaped muscle located forward of the gluteus maximus, which partially covers it. The gluteus medius inserts on the tip of the greater trochanter (a protuberance on the proximal femur to which muscles attach). The gluteus medius covers the gluteus minimus.

Direction and placement of muscle fibers determines the movement produced by contraction. Anterior fibers internally rotate and middle fibers abduct the femur. When the femur is fixed in place, as in one-legged standing poses, contracting the gluteus medius tilts the pelvis, maintaining balance.

We are largely unaware of the gluteus medius, though it is constantly active and balances the pelvis when standing and walking. Contract it in backbends to counterbalance the external rotation of the hips produced by contraction of the gluteus maximus.

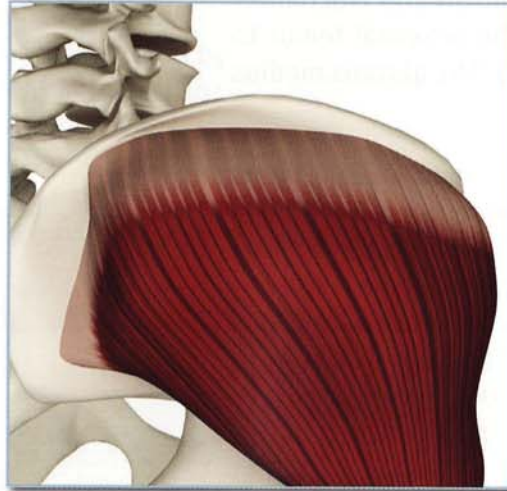
Tightness in the gluteus medius limits postures that require extensive external rotation of the femur at the hip (e.g. lotus posture). Weakness limits one-legged standing poses.



Gluteus Medius (GL00 -te-us ME-de-us)

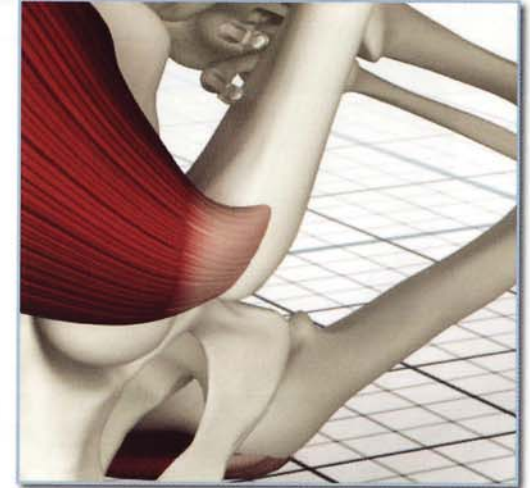Origin

Outer surface of ilium below the iliac crest and anterior to the gluteus maximus origin.



Insertion

Superior surface of greater trochanter of the proximal femur.

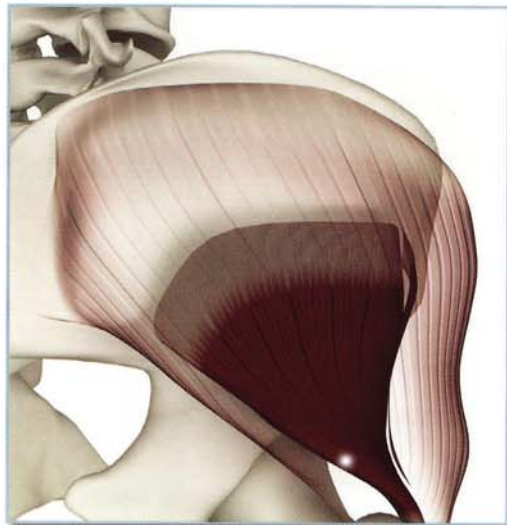


Gluteus Minimus

This see-through image of the gluteus medius illustrates the position of the gluteus minimus, which has a similar function.

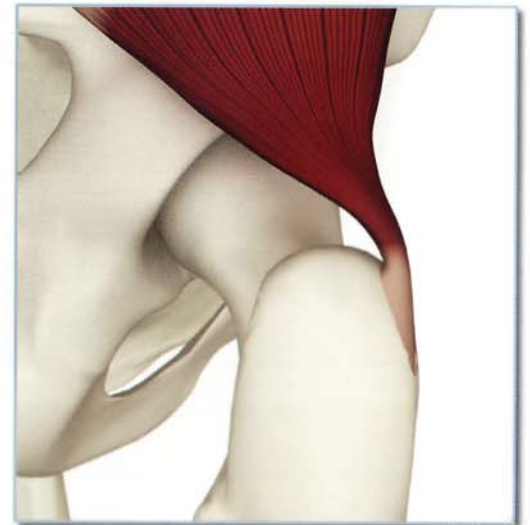Origin

Outer surface of the ilium below and anterior to the gluteus medius origin.



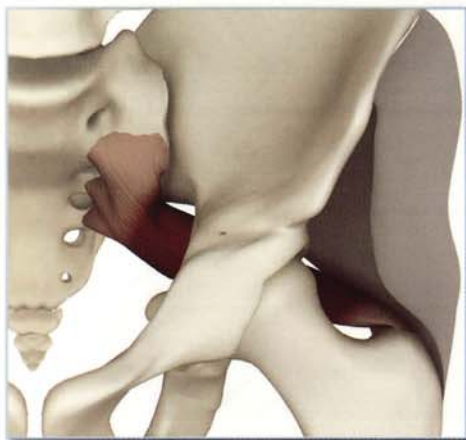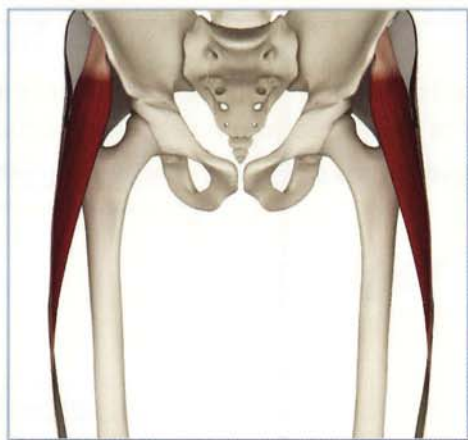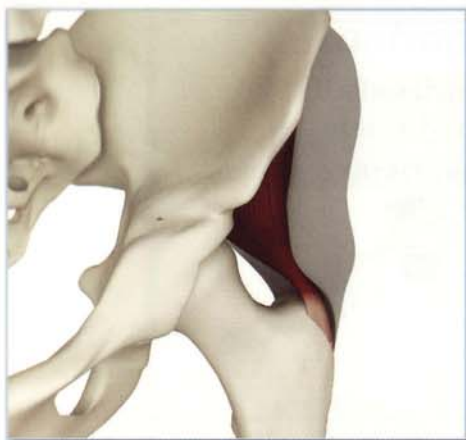Insertion:

Anterior portion of the greater trochanter.



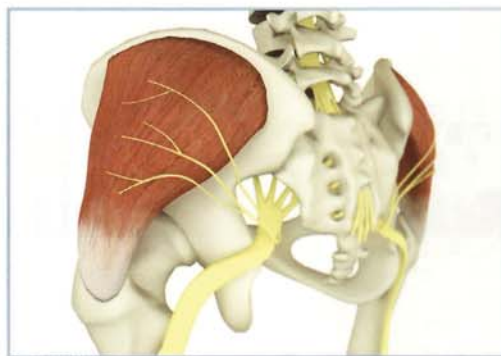
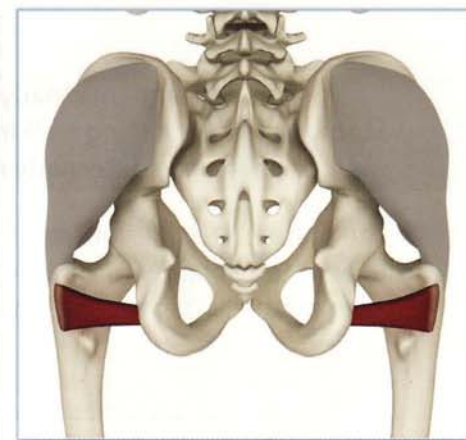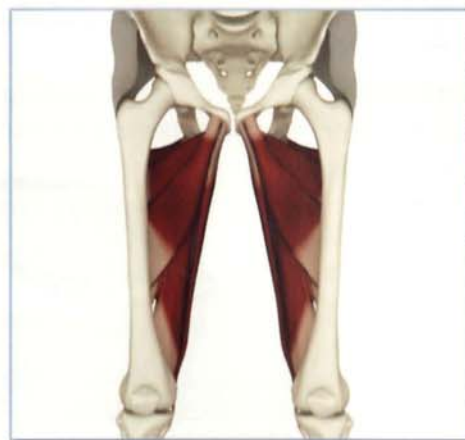Synergists

Gluteus minimus, tensor fascia lata and piriformis.



Antagonists

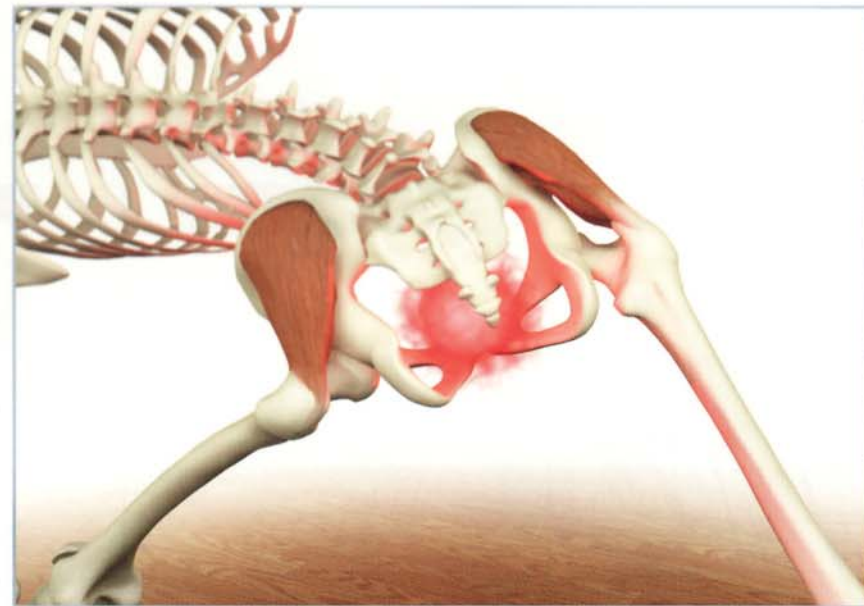
Adductor group and quadratus femoris.



Innervation & chakra illuminated

Superior gluteal nerve (lumbar spinal nerves 4 and 5,
and sacral spinal nerve 1)

Chakra illuminated: First



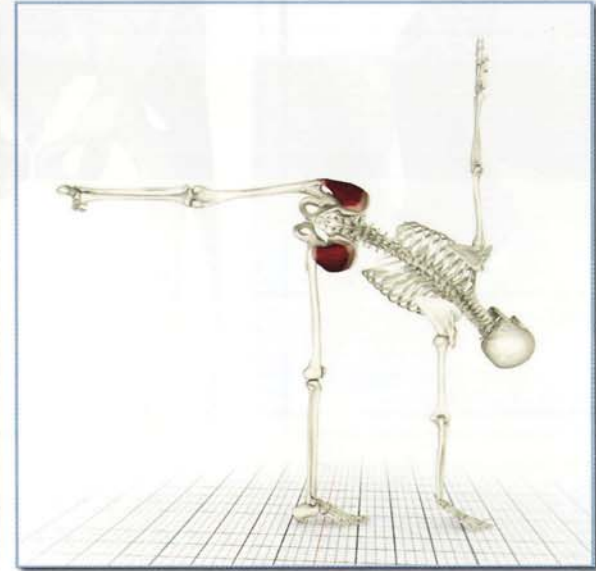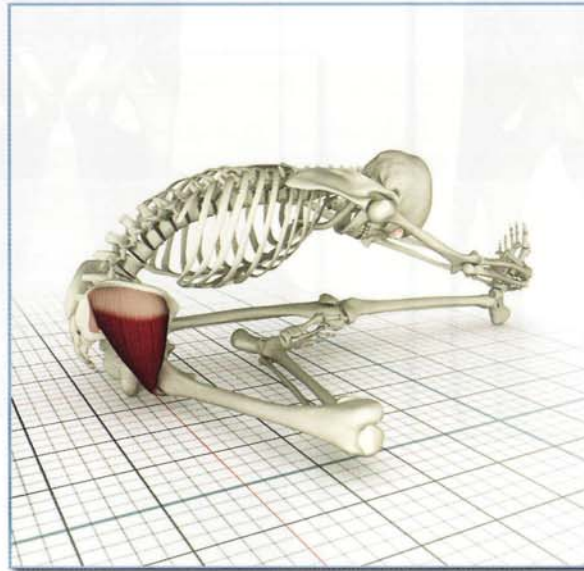Gluteus Medius (GLOO -te-us ME-de-us)

Action

Abducts and internally rotates hip. Stabilizes pelvis during walking. Posterior fibers may externally rotate thigh.

The gluteus medius contracts and abducts the bent leg in janusirasana. Anterior fibers also medially rotate the thigh, protecting the knee.

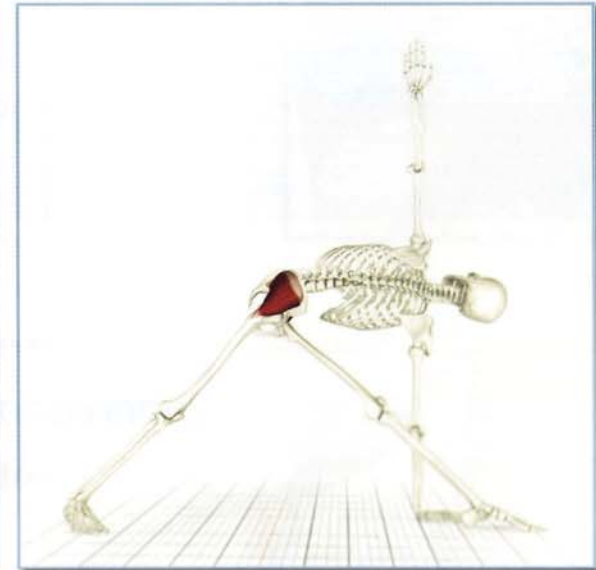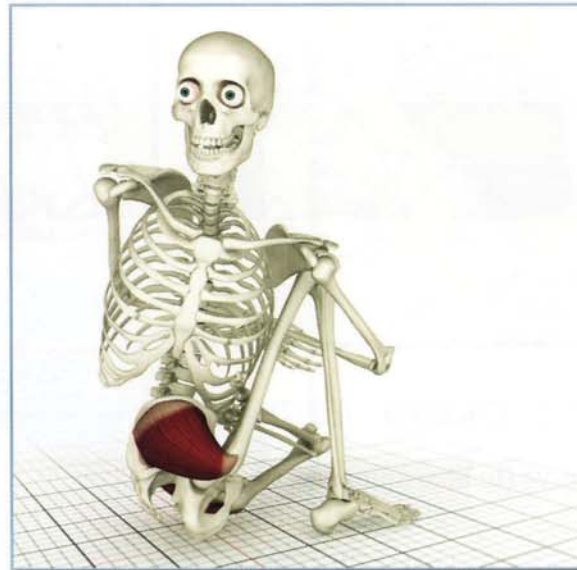The gluteus medius contracts and abducts the straight leg, lifting it in ardhasandrasana.



Awakening

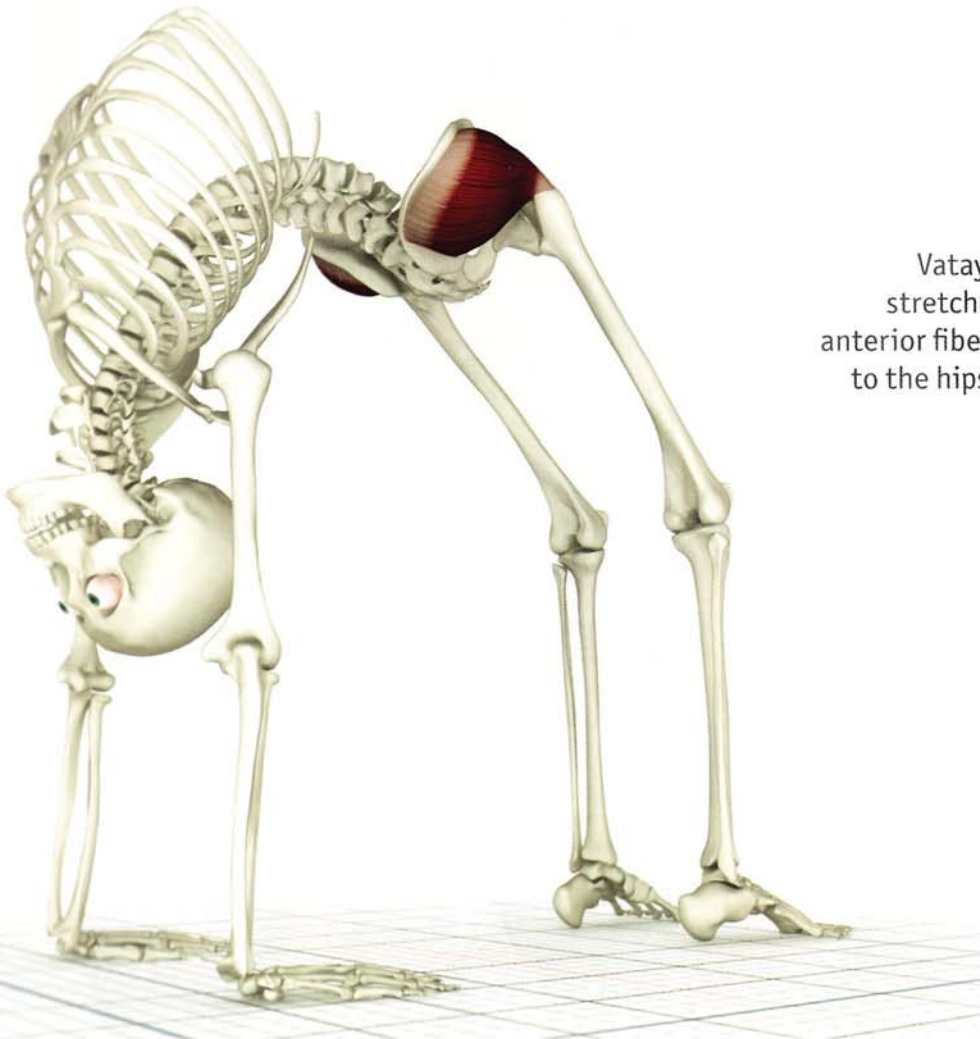
Contracting the gluteus medius in marichyasana IV accentuates the twist. This isometric contraction awakens the gluteus medius.

Contracting the gluteus medius in the back leg of parivrtta trikonasana accentuates the twist from the trunk by rotating the femur.



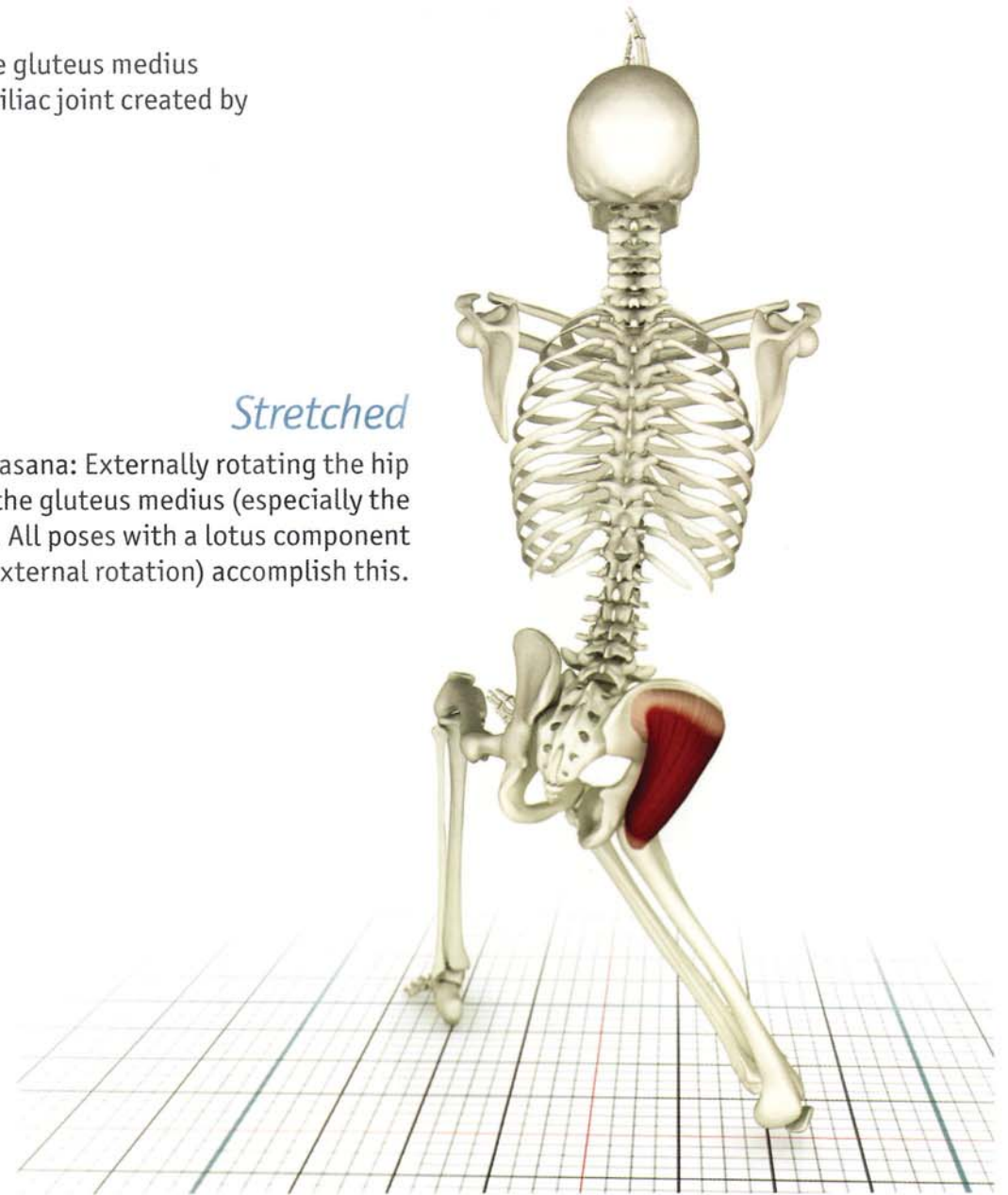
Contracted

Urdhva-dhanurasana: Contracting the anterior fibers of the gluteus medius internally rotates the hips and releases stress at the sacroiliac joint created by contracting the gluteus maximus (to extend the hip).



Stretched

Vatayanasana: Externally rotating the hip stretches the gluteus medius (especially the anterior fibers). All poses with a lotus component to the hips (external rotation) accomplish this.

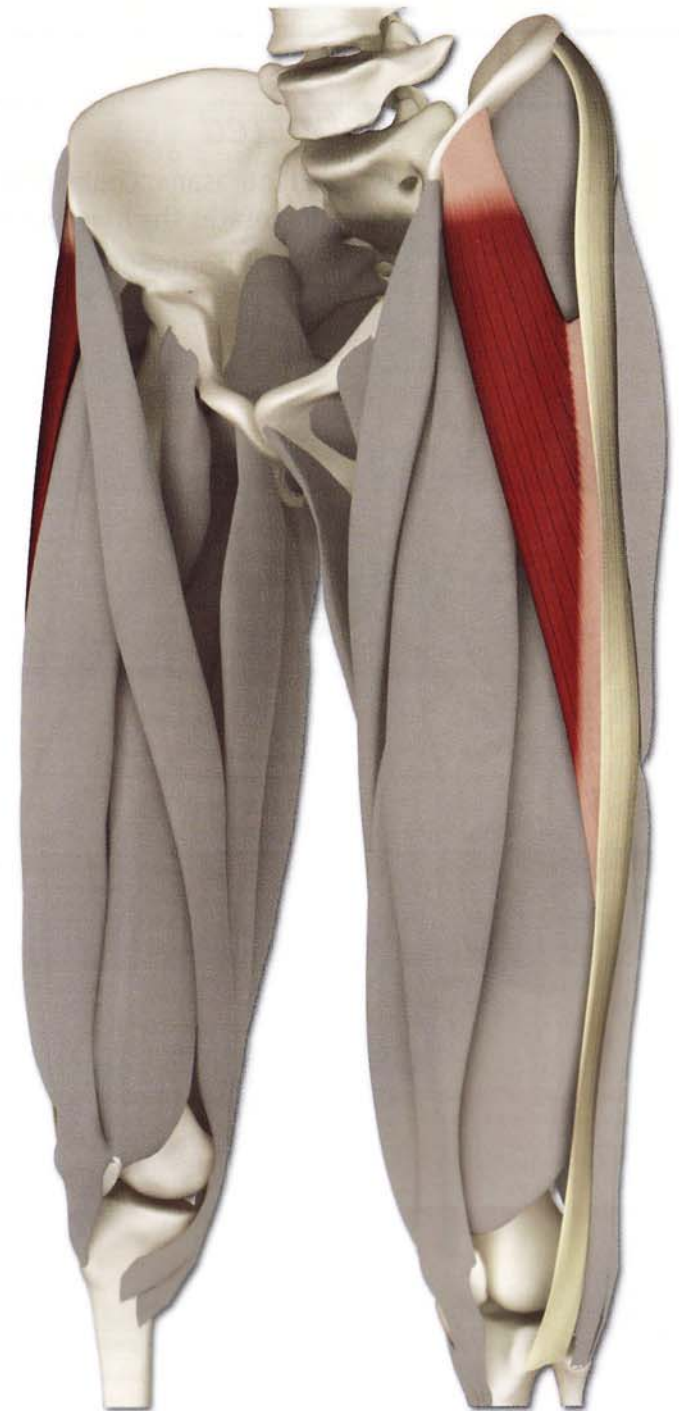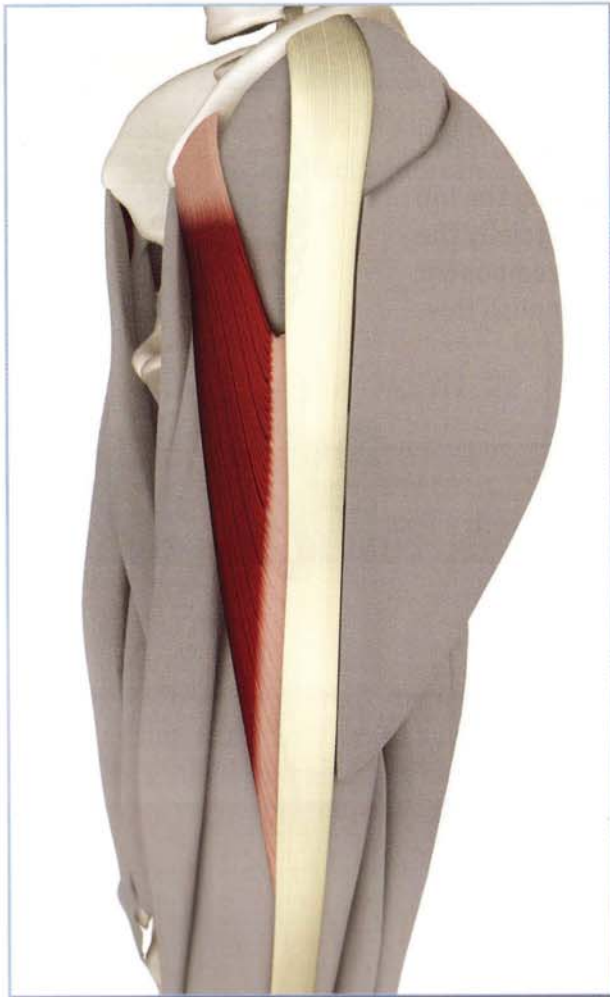


Chapter 4

Tensor Fascia Lata

This small polyarticular muscle originates from the iliac crest in front of the gluteus medius, assisting it with internal rotation of the hip. Inserting on the iliotibial band, it also works with the anterior fibers of the gluteus maximus to extend the knee.

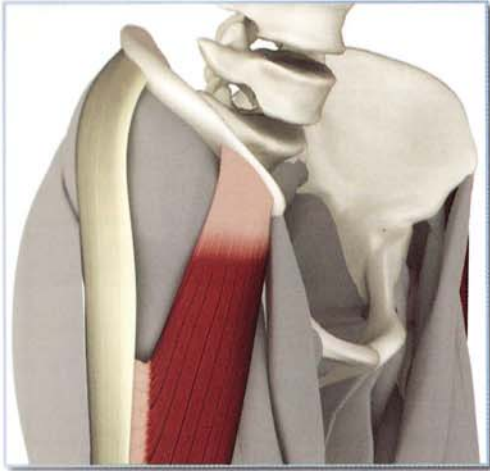
Tightness in the tensor fascia lata limits postures that externally rotate the hip, such as padmasana.



Tensor Fascia Lata (TEN-sor FASH-e-a LA-te)

Origin

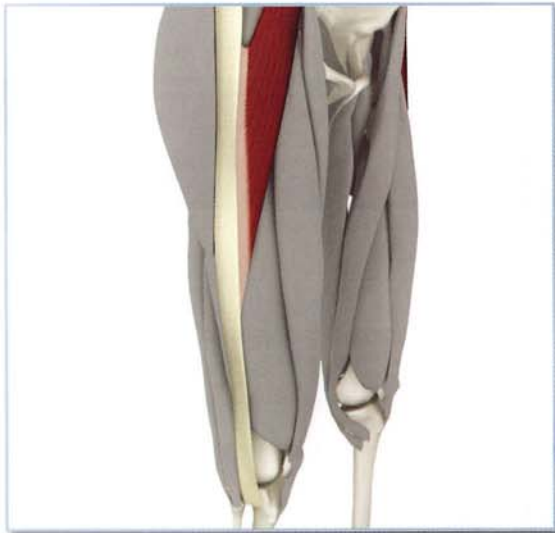
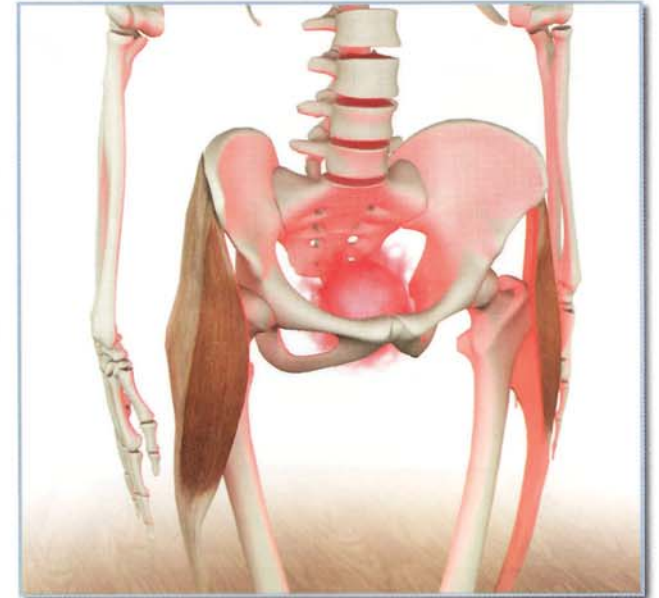
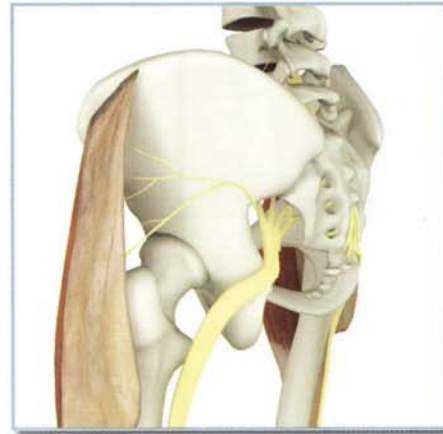
Anterior portion of the outside of the iliac crest, and the anterior superior iliac spine.



Innervation & chakra illuminated

Superior gluteal nerve (lumbar nerves 4 and 5, and sacral nerve 1).

Chakra illuminated: First.



Insertion

Iliotibial band (and from there to the anterolateral proximal tibia).

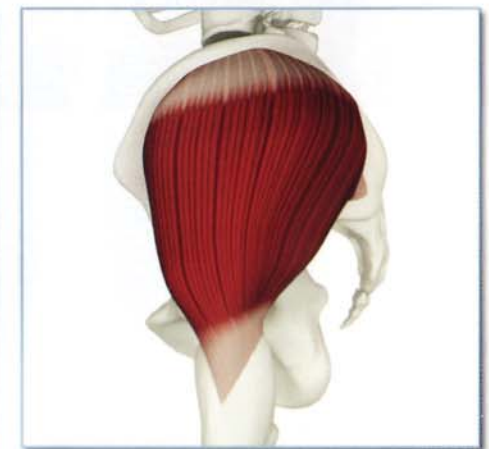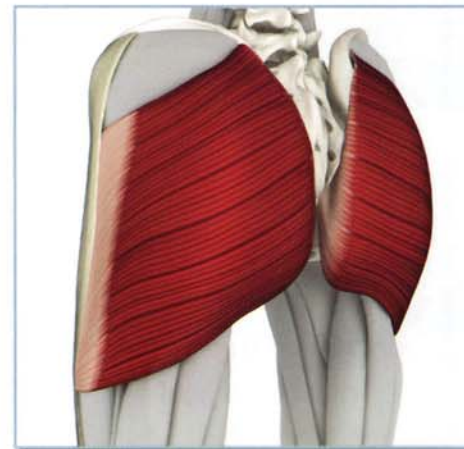
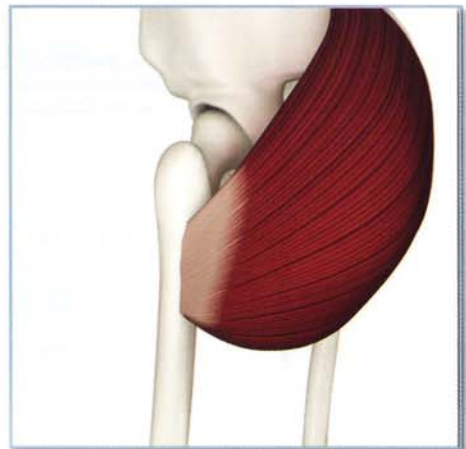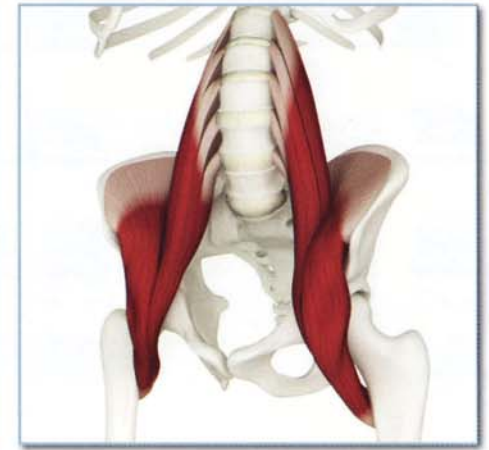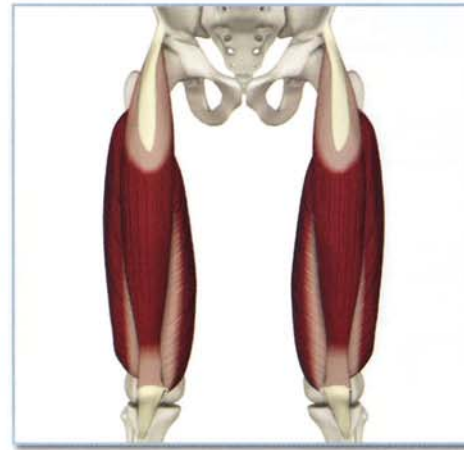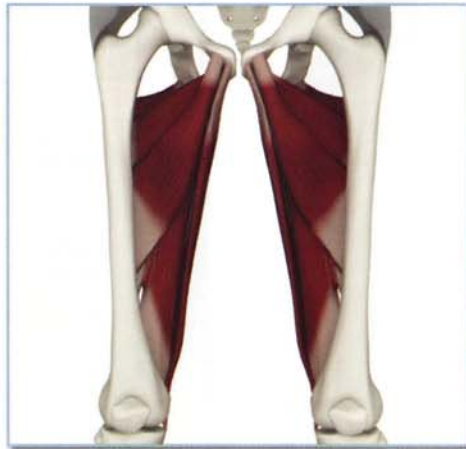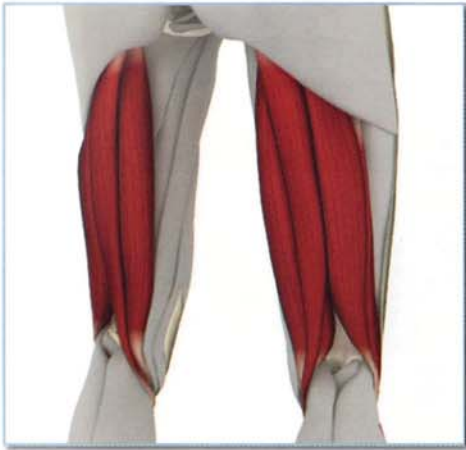Tensor Fascia Lata (TEN-sor FASH-e-a LA-te)

Antagonists

Hamstrings, adductor group and gluteus maximus (femoral insertion).

Synergists

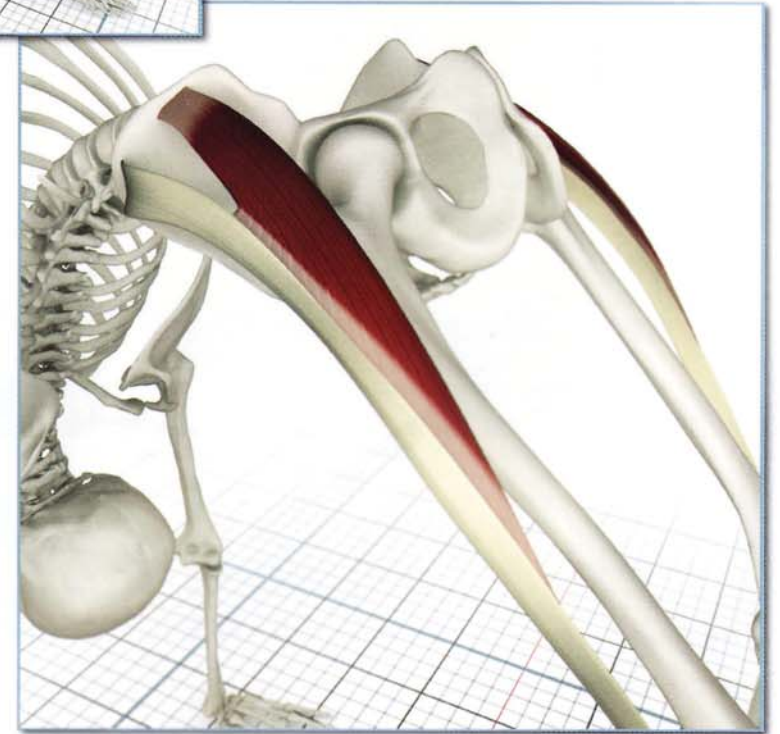
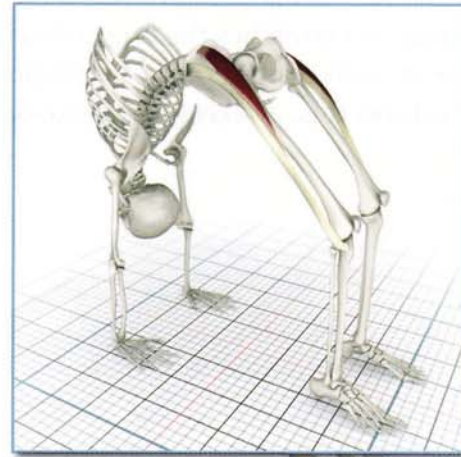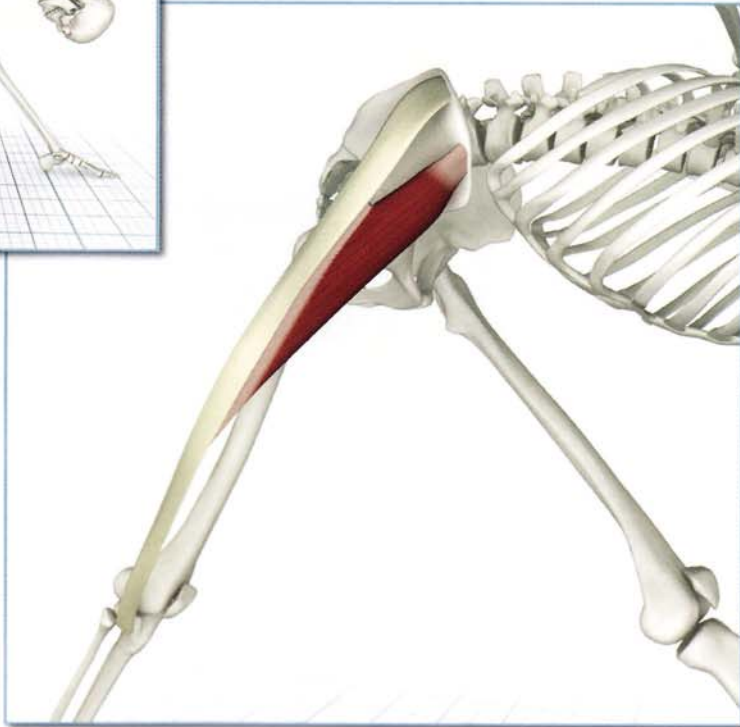
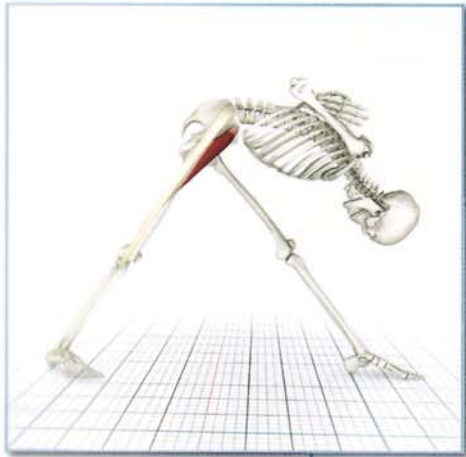Quadriceps, iliopsoas and anterior portion of gluteus maximus (iliotibial band insertion), gluteus medius.



Action

Flexes, internally rotates and abducts the hip, and supports the femur on the tibia during standing.

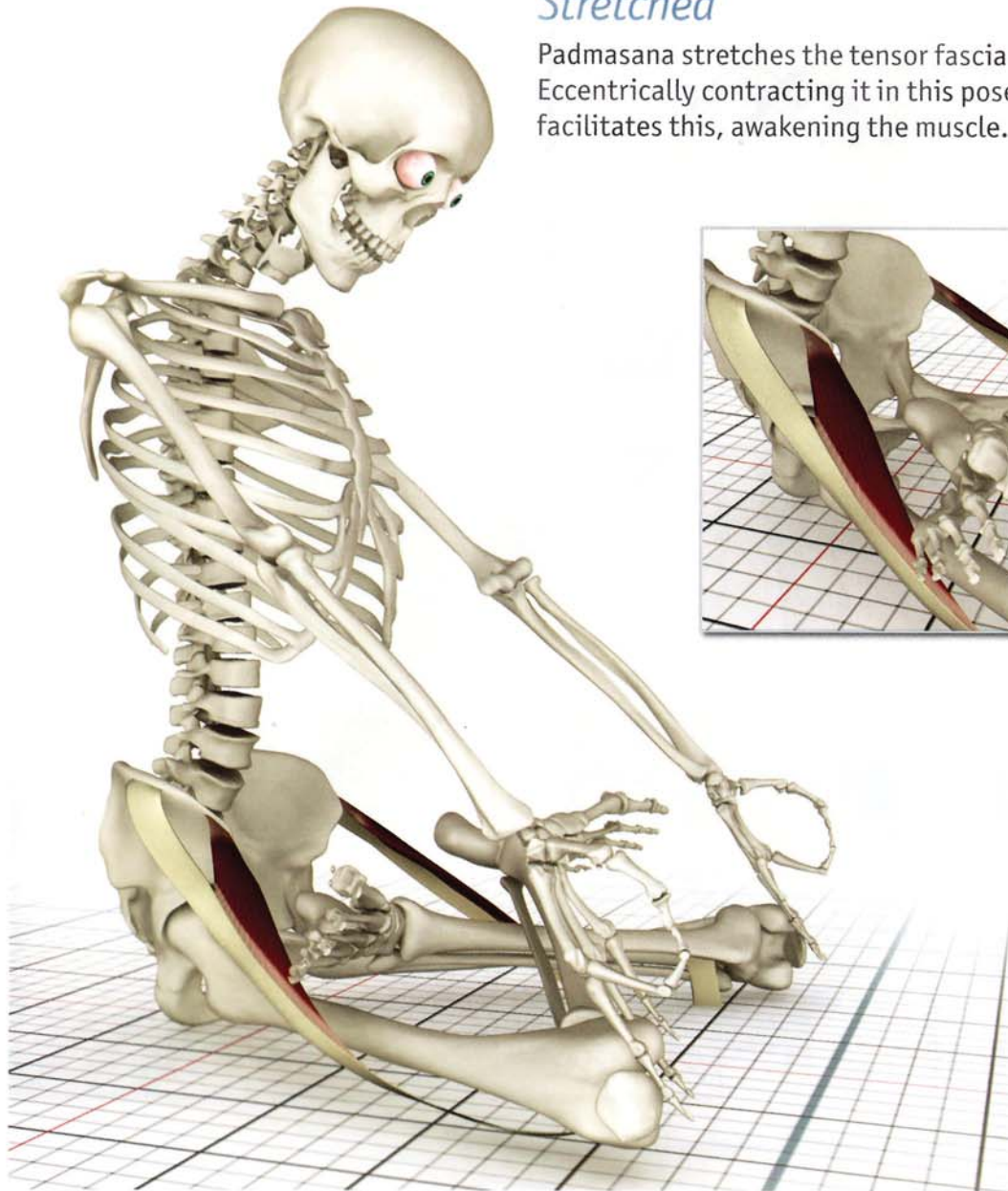
Open chain contraction in parsvottonasana and urdhvadhanurasana turns the thighs inward and straightens the knee.



Tensor Fascia Lata (TEN-sor FASH-e-a LA-te)

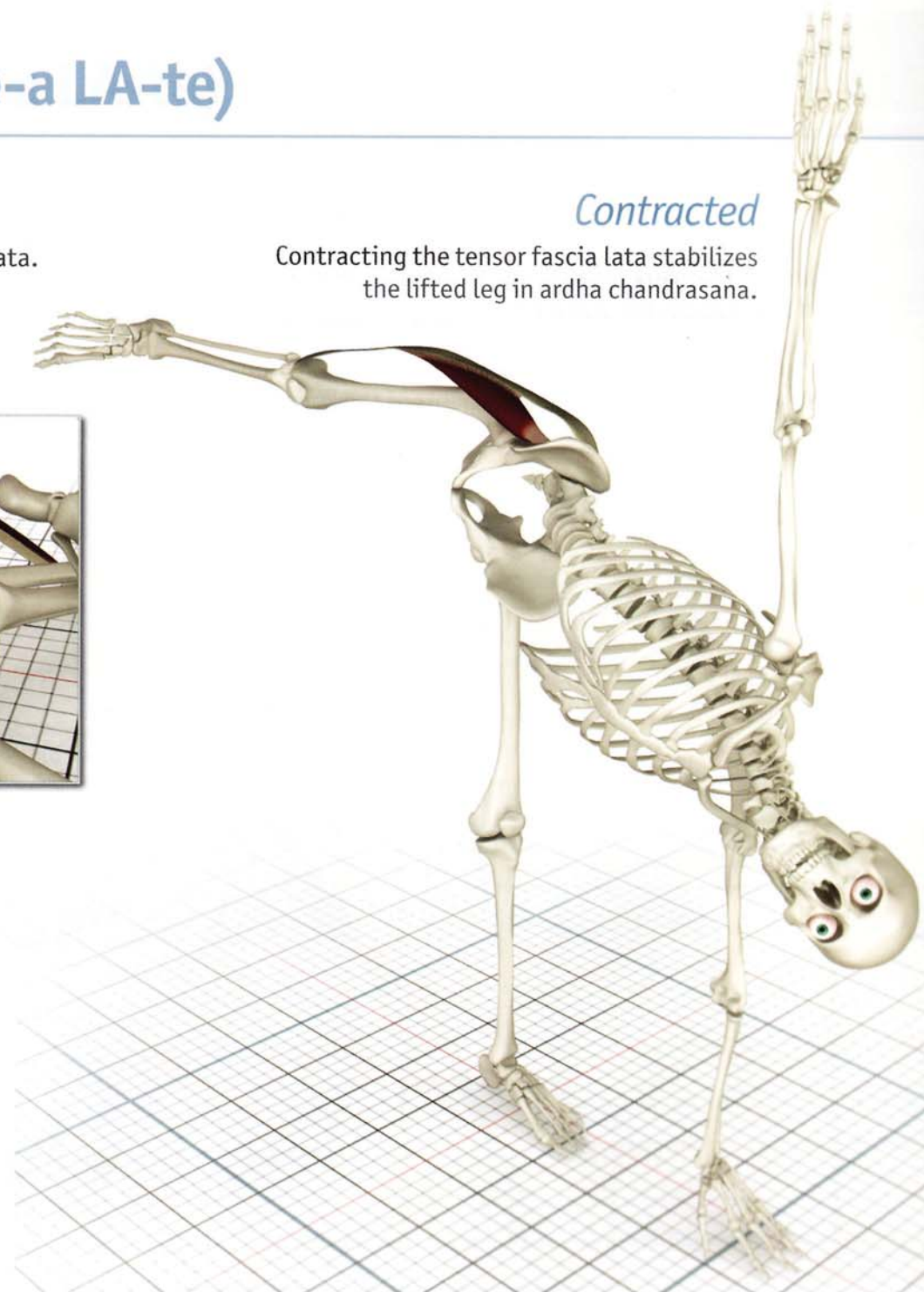
Stretched

Padmasana stretches the tensor fascia lata. Eccentrically contracting it in this pose facilitates this, awakening the muscle.



Contracted

Contracting the tensor fascia lata stabilizes the lifted leg in ardha chandrasana.



Chapter 5a

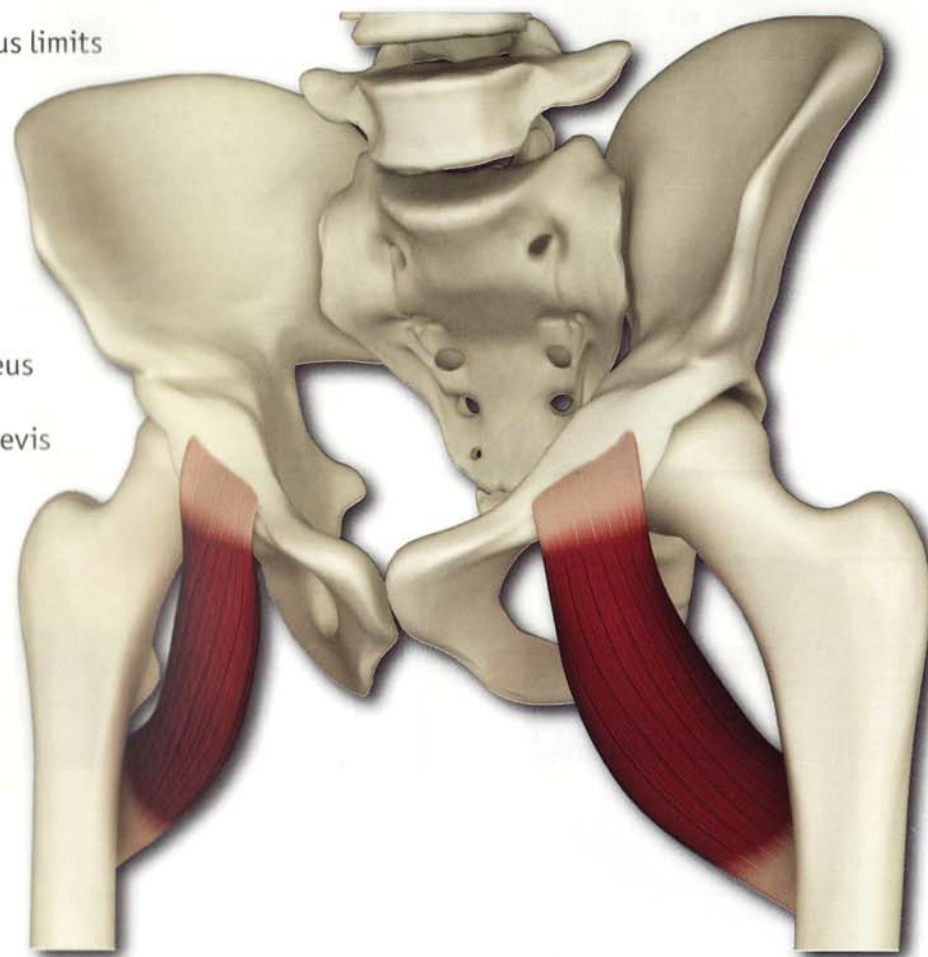
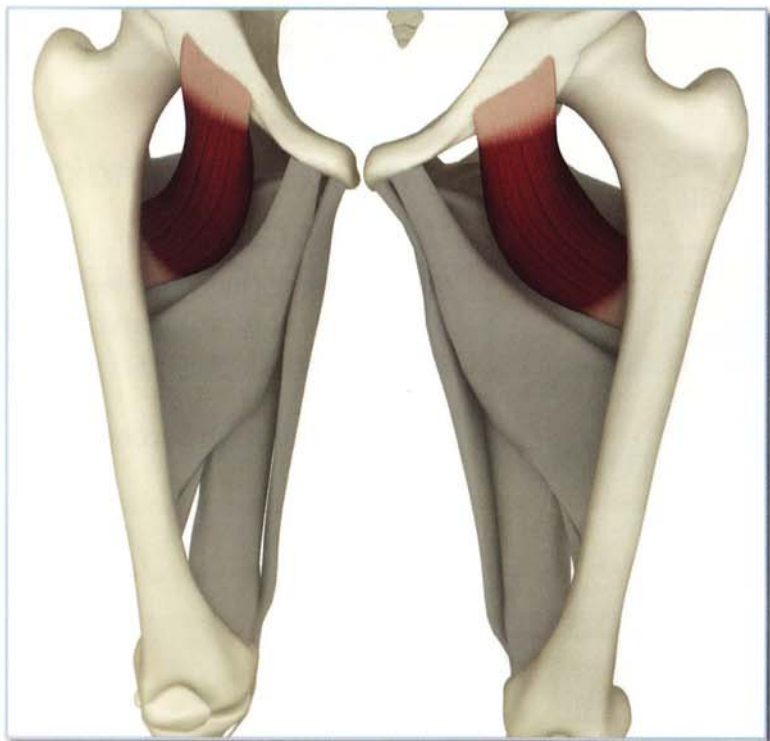
Pectineus

The pectineus is the proximal muscle in the adductor group. It is a flat rectangular muscle originating from the front of the pelvic girdle and inserting on the inside of the proximal femur. It is monoarticular.

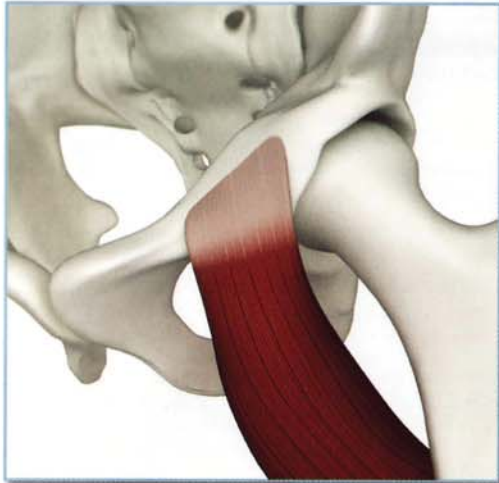
Tightness in the pectineus limits the depth of poses like baddhakonasana.

Weakness limits gomukhasana B. Contraction accentuates moola bandha.

Awareness of the pectineus awakens its neighboring adductor muscles, the brevis and longus.

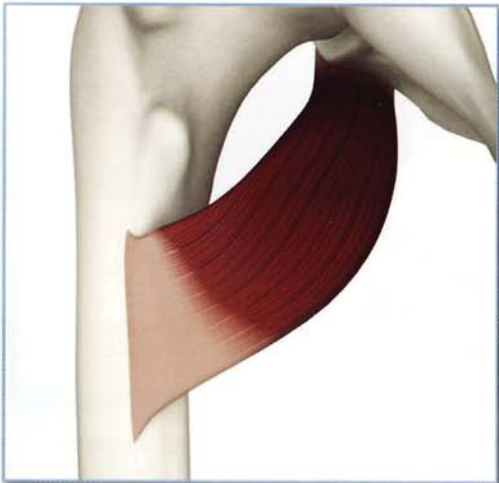
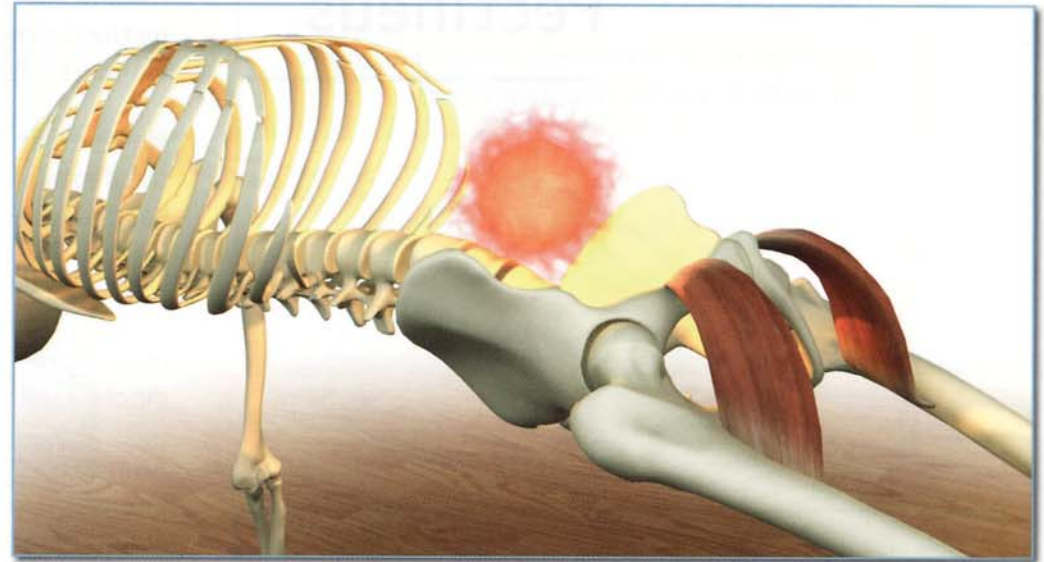


Pectineus (pec-ti-NEUS)



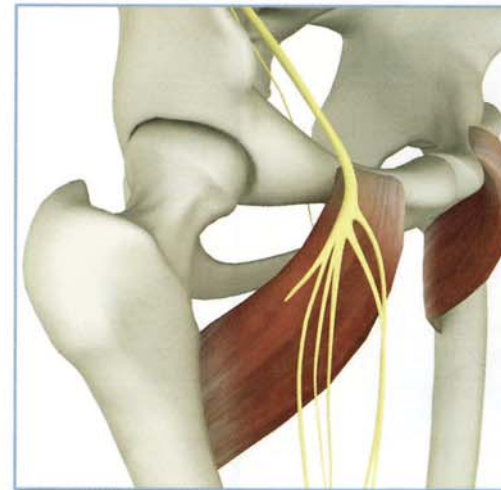
Origin

Pecten (a bulge) of the pubic bone on the iliopubic ramus, lateral to the pubic symphysis.
(front view)



Insertion

Pectineal line extending from the lesser trochanter to the linea aspera on the inside of the proximal femur.
(back view)



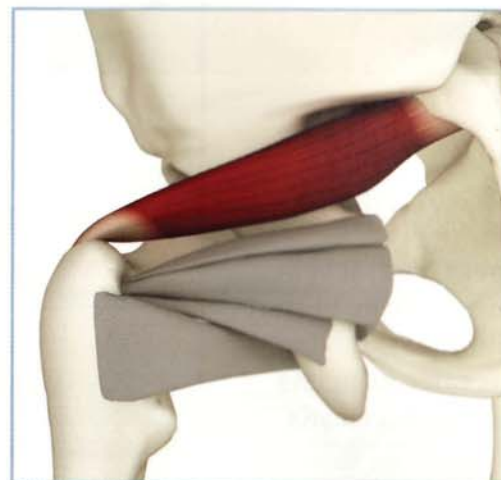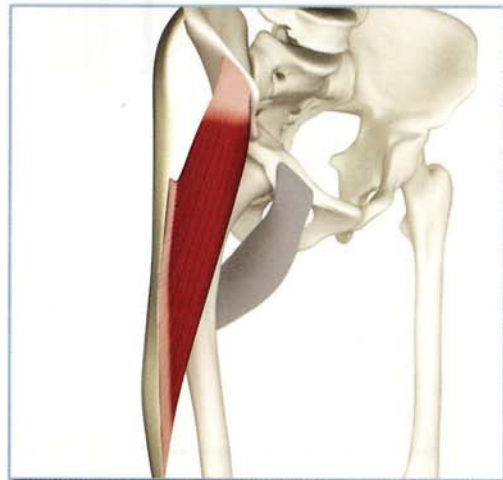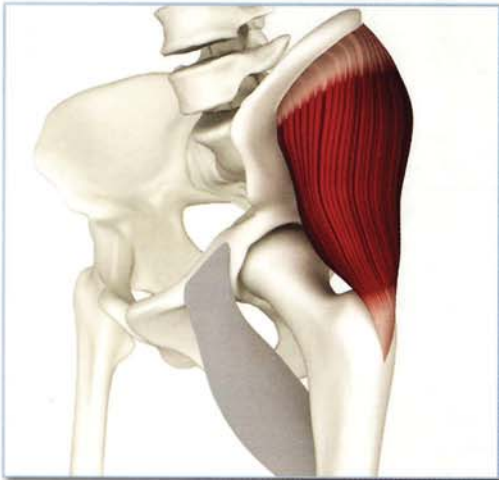
Innervation & chakra illuminated

Femoral nerve (lumbar spinal nerves 3 and 4) +/- obturator nerve (lumbar spinal nerves 2, 3 and 4).

Chakra illuminated: Second.

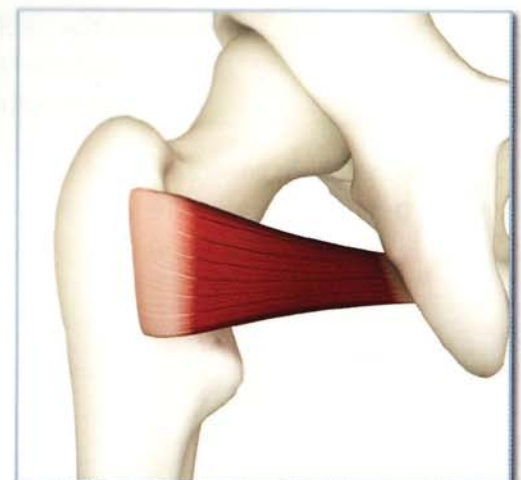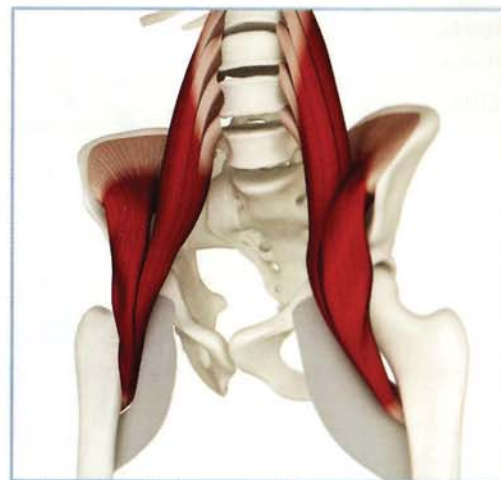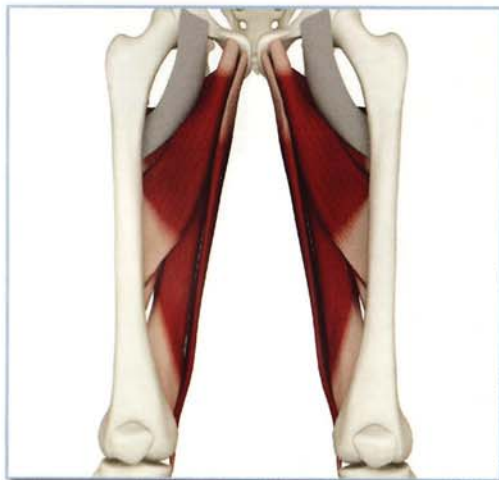Antagonists

Gluteus medius, gluteus minimus, tensor fascia lata and piriformis.



Synergists

Adductor group, iliopsoas and quadratus femoris.

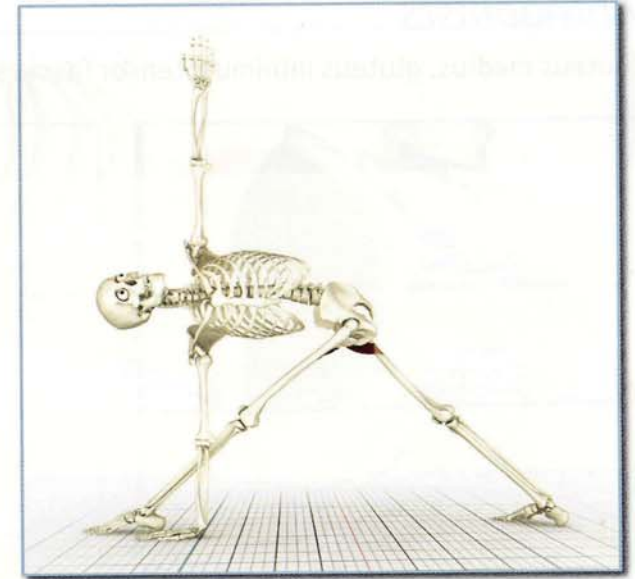
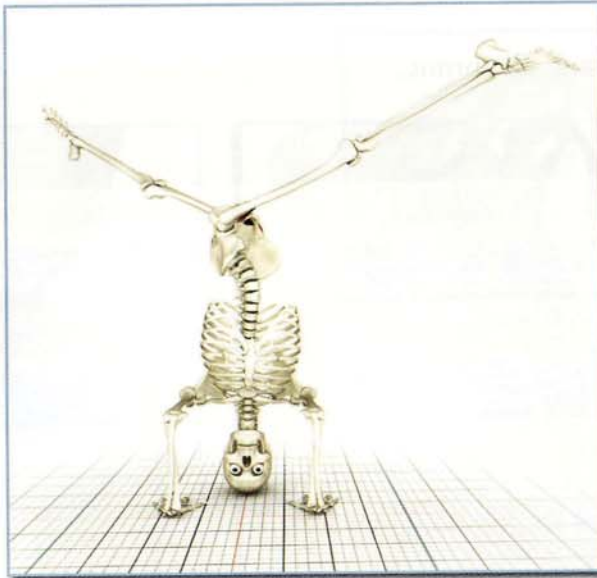


Pectineus (pec-ti-NEUS)

Action

Adducts, flexes and internally rotates hip.

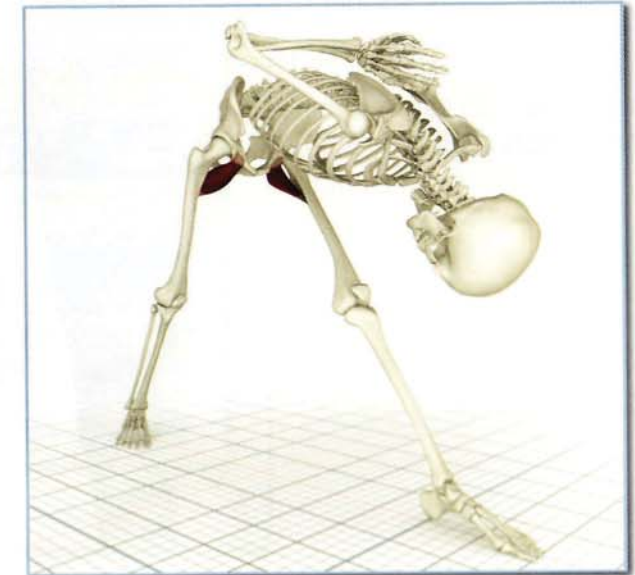The pectineus contracts in parivrtaikapada sirasana adducting both femurs and assisting the iliopsoas, flexing the forward hip. This same principle applies in parivrta trikonasana.



Awakening

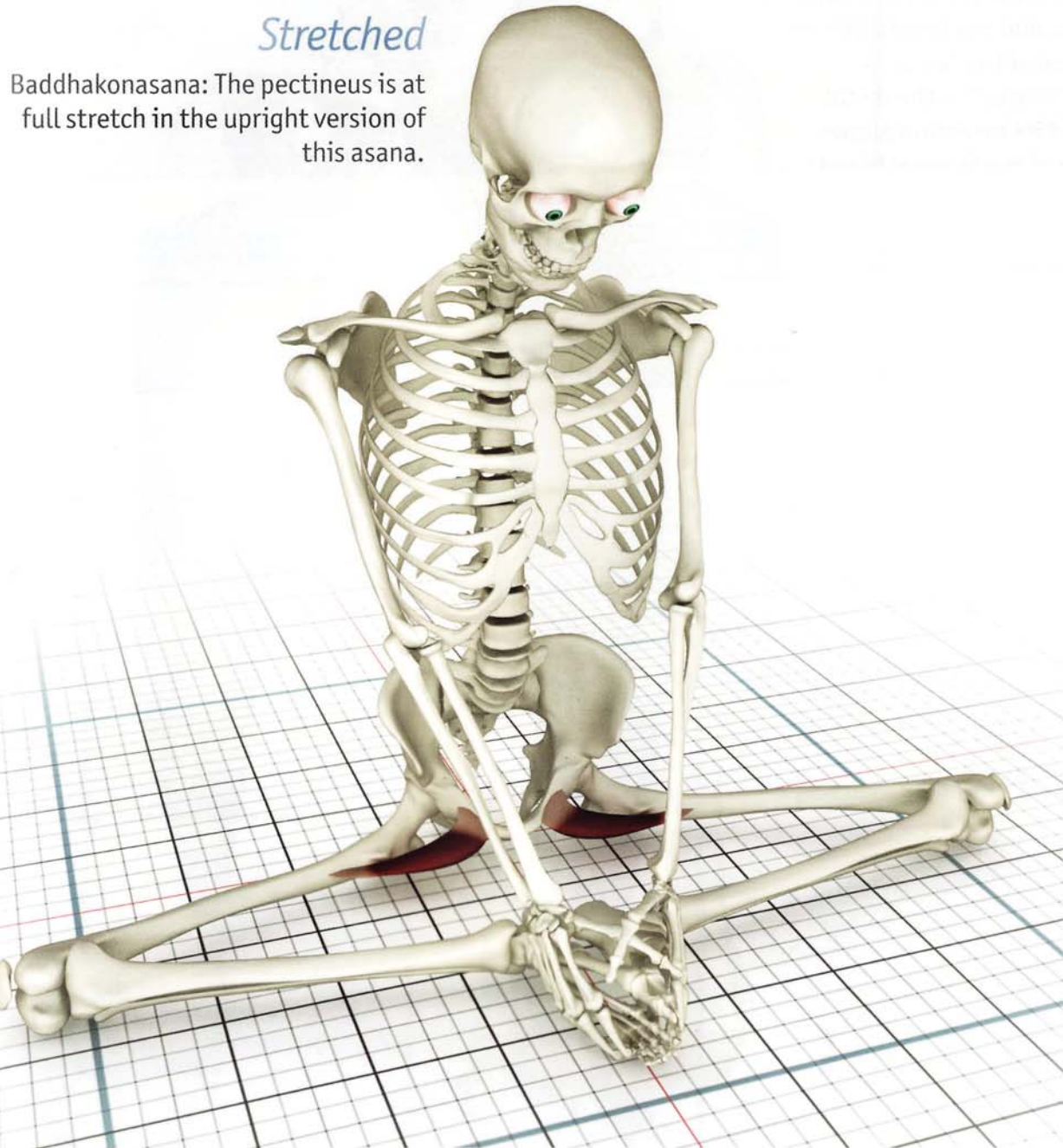
Baddhakonasana awakens the pectineus.
Isometric eccentric contraction accentuates this.

Closed chain contraction of the front leg pectineus draws the pelvis (and trunk) forward in parsvottanasana.



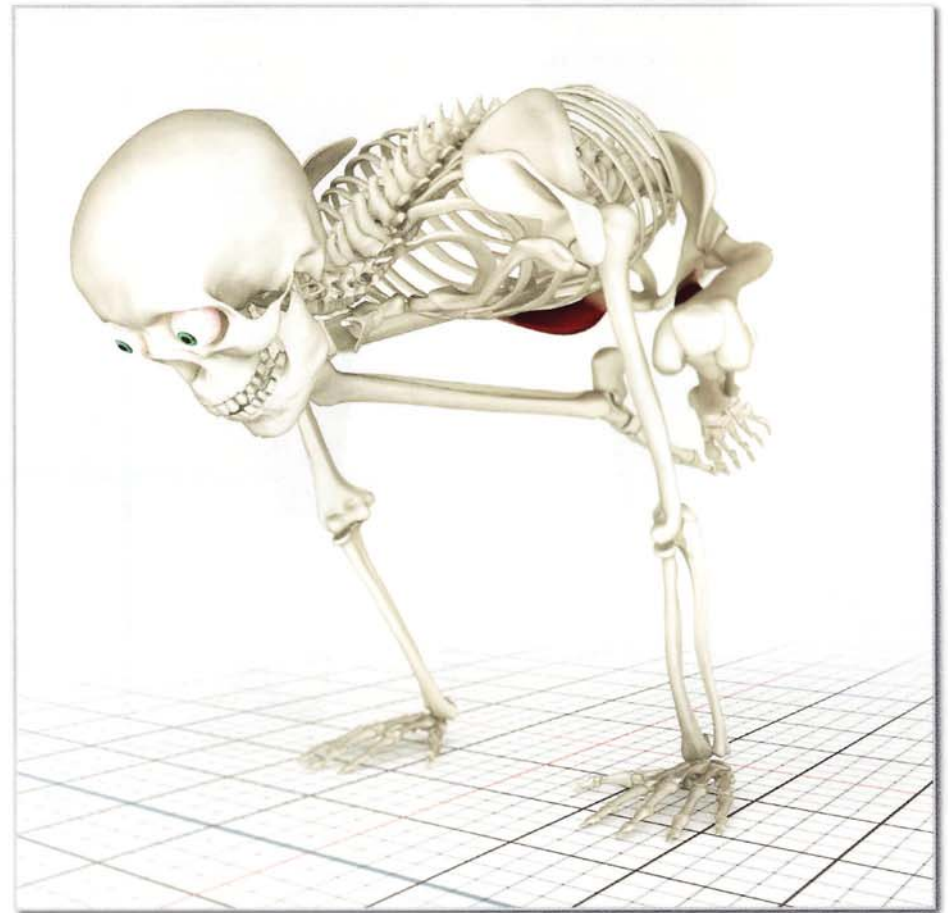
Stretched

Baddhakonasana: The pectineus is at full stretch in the upright version of this asana.



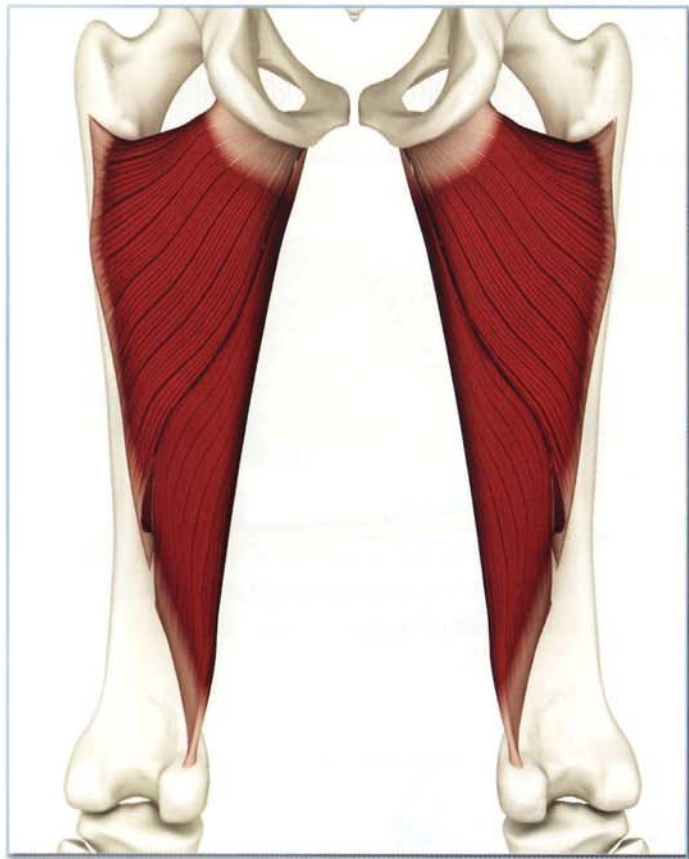
Contracted

Bakasana: Contracting the adductor group stabilizes this asana.



Chapter 5b

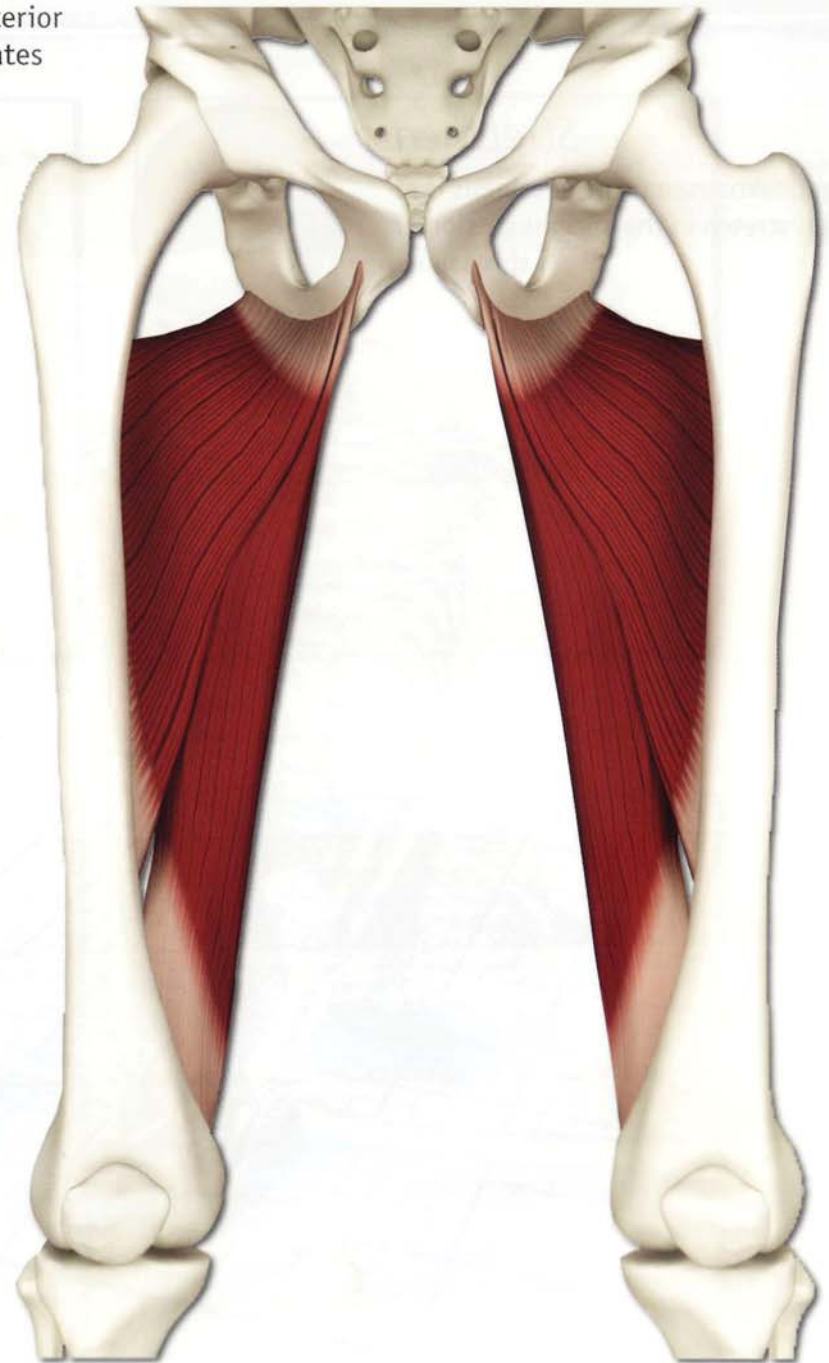
Adductor Magnus



Posterior

This is the largest and most posterior of the adductor group. It originates from the back of the pelvis and inserts along the length of the inside of the femur. A hole or "hiatus" in the distal region of its insertion allows passage of the femoral blood vessels.

Its posterior location means that it functions to adduct and extend the thigh backward. It is a synergist to the gluteus maximus, assisting it in back-bending postures such as *urdhavadhanurasana*. Tightness limits poses such as front splits. Weakness limits *bakasana*. Contraction of the adductor magnus accentuates *moola bandha*.

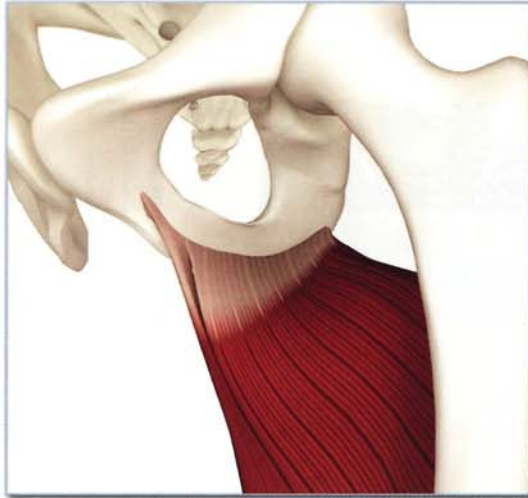

Adductor Magnus (ad-DUK-tor MAG-nus)

Origin

Anterior section:
Ischiopubic ramus.

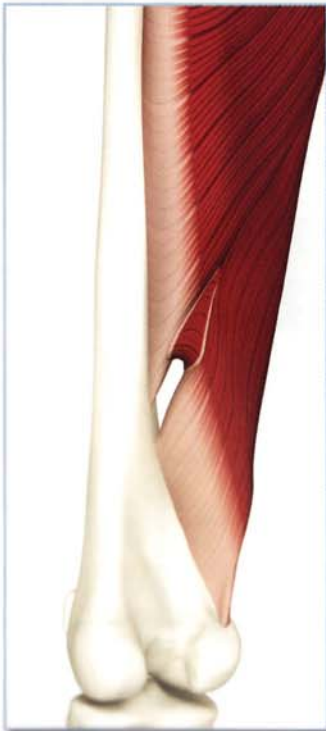
Posterior section:
Ischial tuberosity.



Insertion

1) Anterior section: Linea aspera on the back of middle third of the femur.

2) Posterior section: Medial epicondyle on inside of the distal femur above the knee joint.



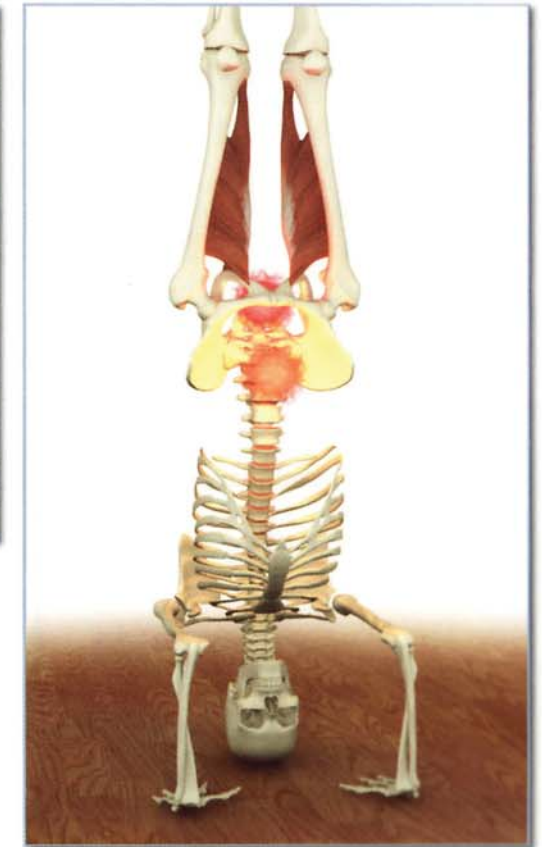
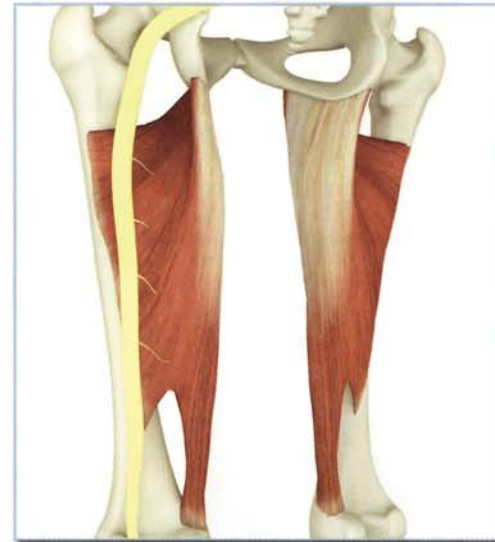Innervation & chakra illuminated

Anterior fibers: Obturator nerve (lumbar spinal nerves 2, 3 and 4).

Posterior fibers: Tibial portion of sciatic nerve (lumbar spinal nerves 3, 4 and 5).

Chakra illuminated:

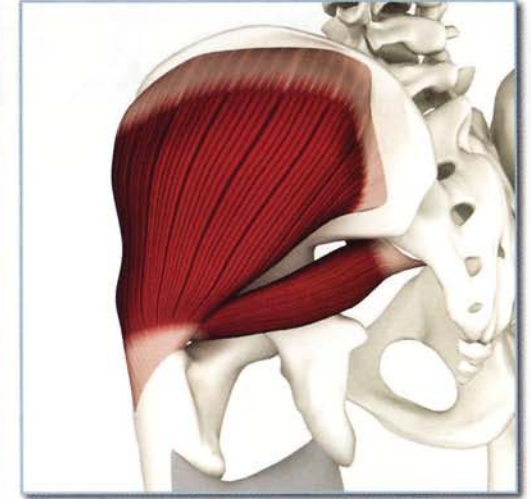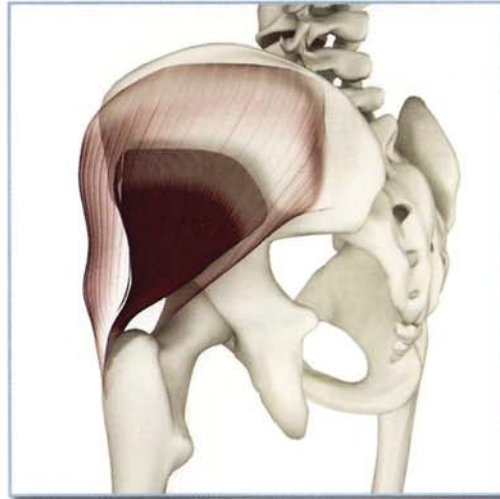
Upper part of first, lower part of second.



Adductor Magnus (ad-DUK-tor MAG-nus)

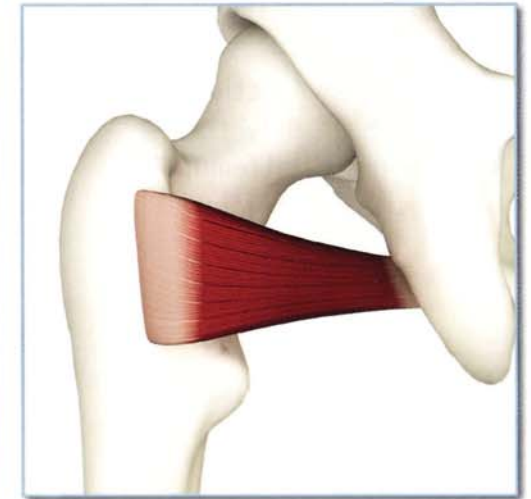
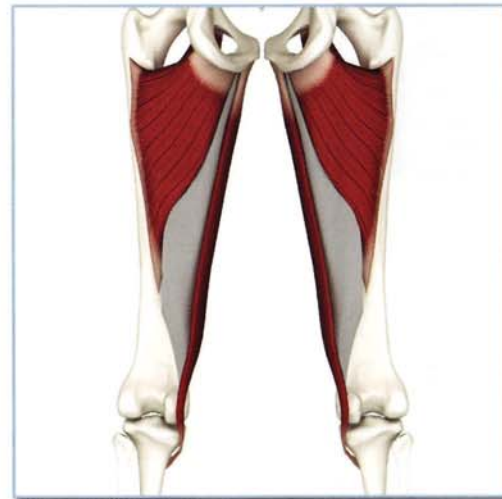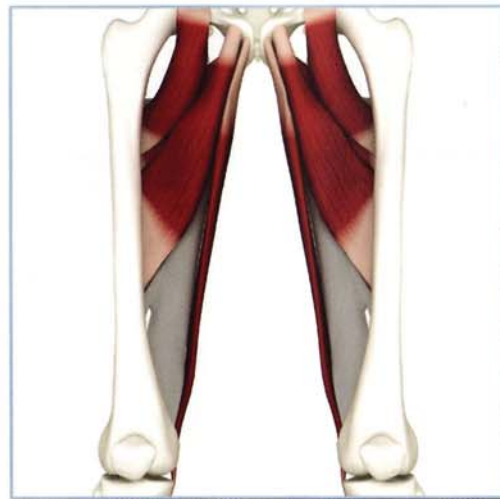Antagonists

Gluteus medius, gluteus minimus, tensor fascia lata and piriformis.



Synergists

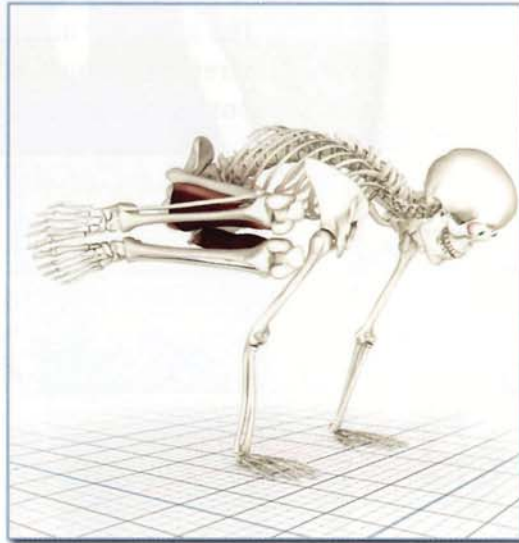
Adductor group and quadratus femoris.



Action

Adducts hip. Posterior fibers extend and externally rotate hip.

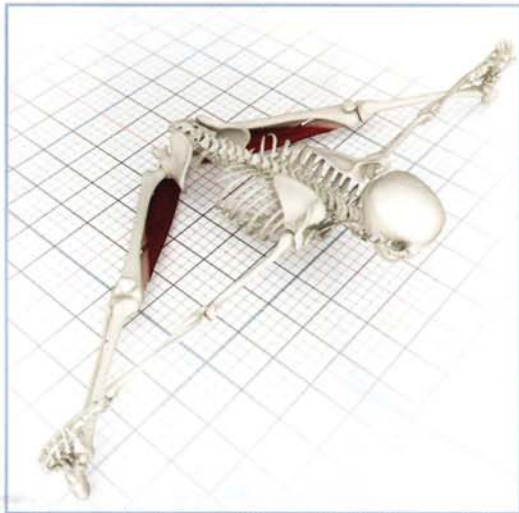
Contracting the adductor magnus squeezes the thighs together in parsva bakasana.



Contracting the adductor magnus assists the gluteus maximus, extending and externally rotating the back leg in parivrtta parsvokonasana.

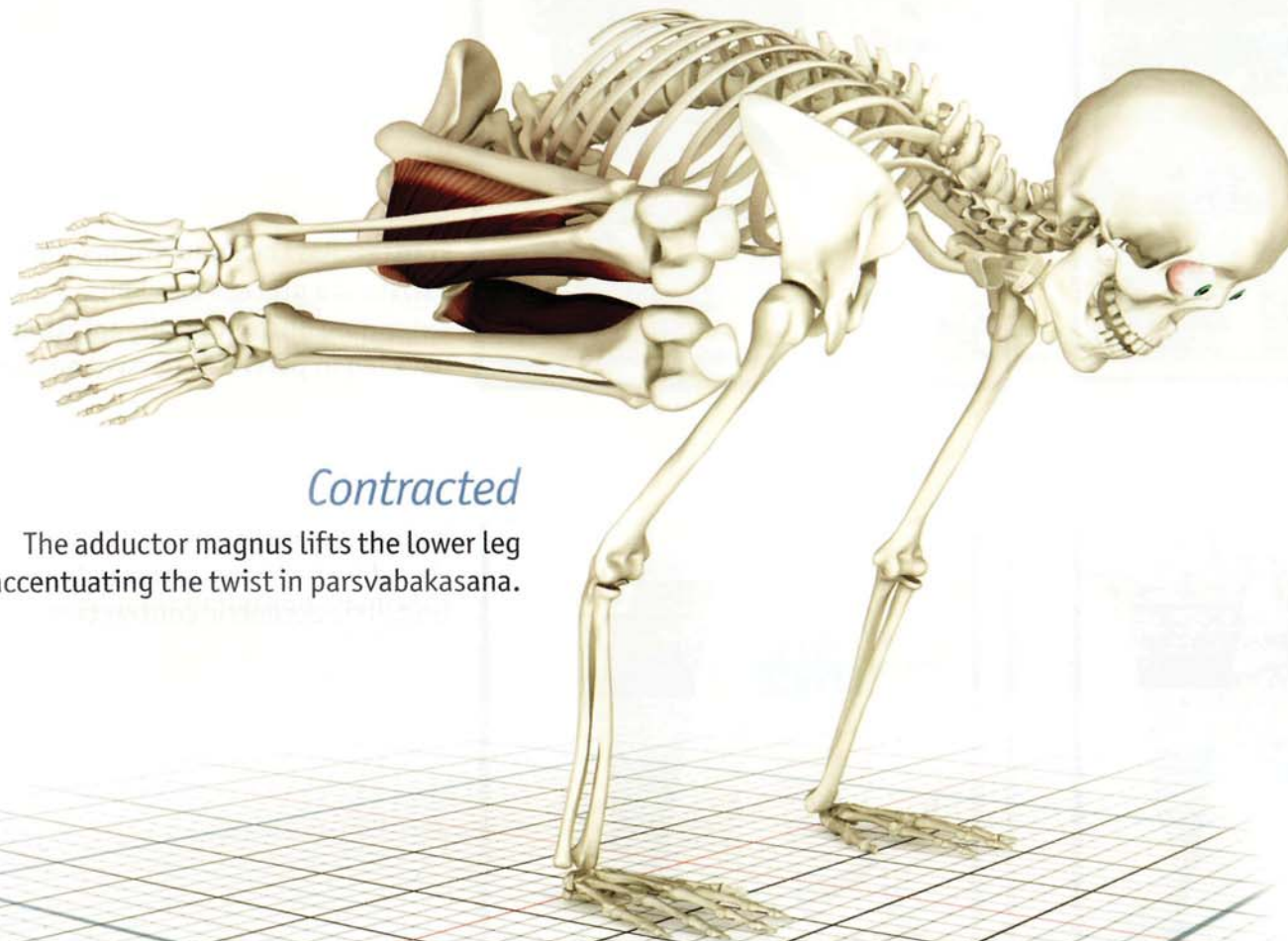
Awakening

Upavistha konasana stretches and awakens the adductor magnus by abducting and flexing the hip.



Baddhakonasana stretches and awakens the adductor magnus through isometric eccentric contraction.

Adductor Magnus (ad-DUK-tor MAG-nus)

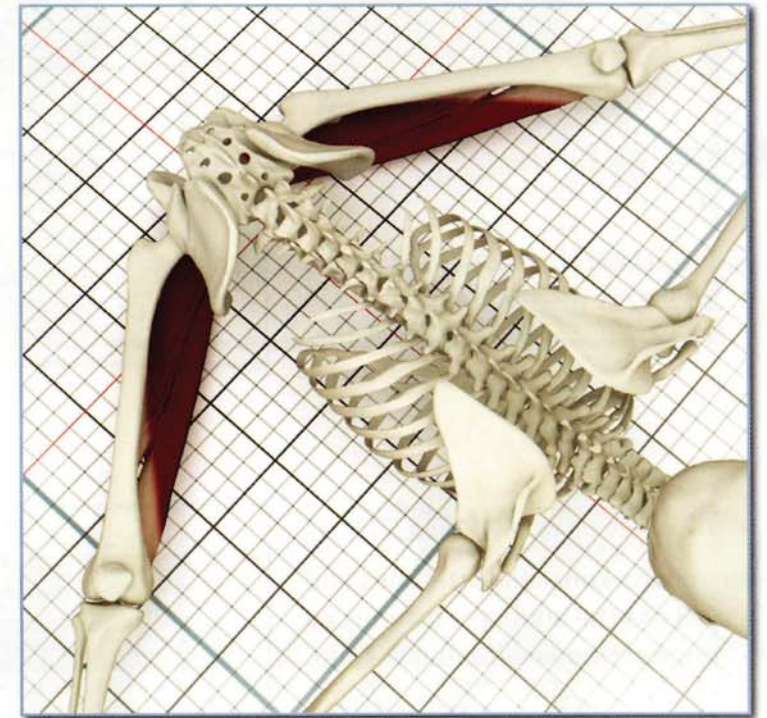

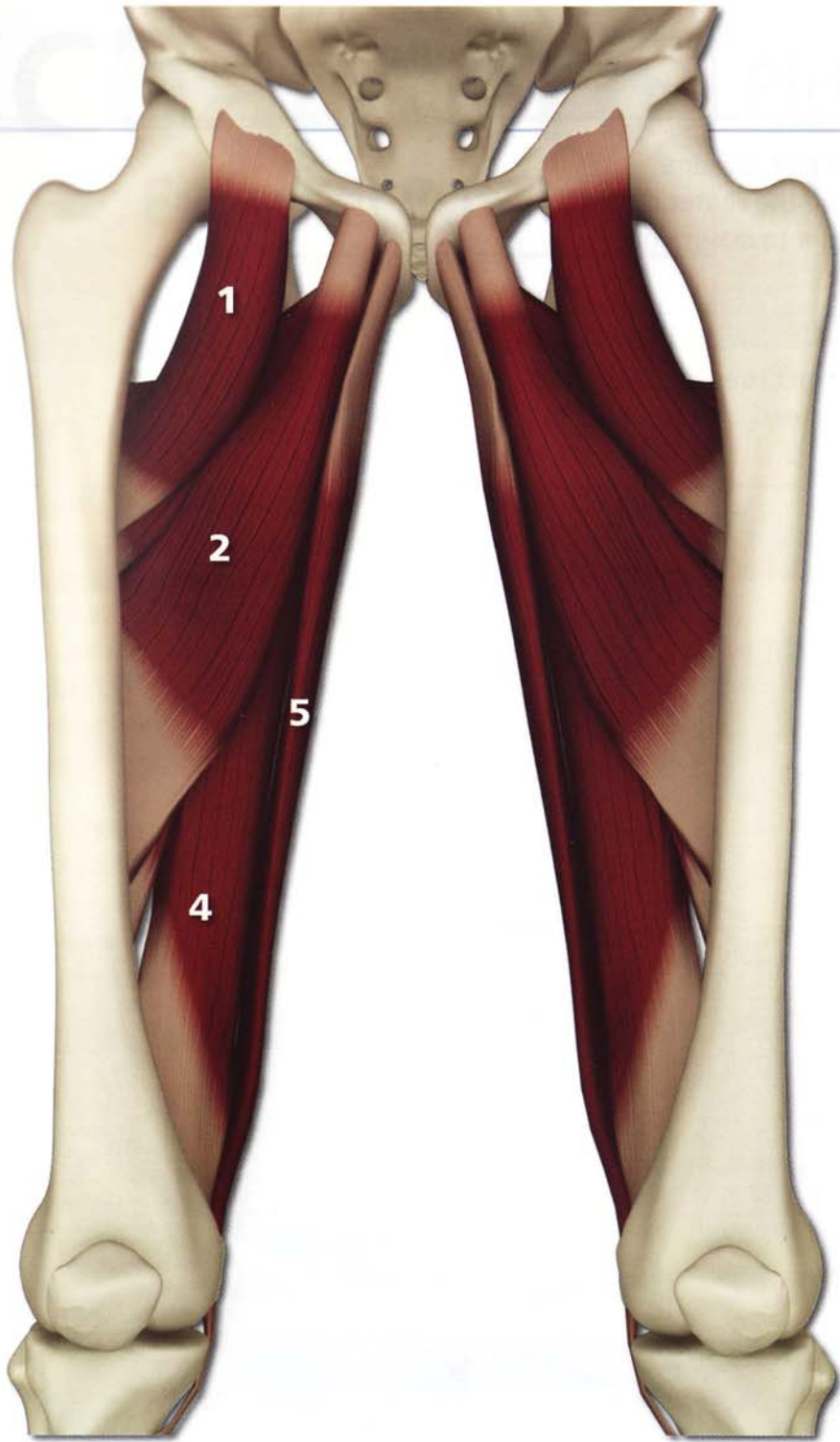
Contracted

The adductor magnus lifts the lower leg accentuating the twist in parsvabakasana.

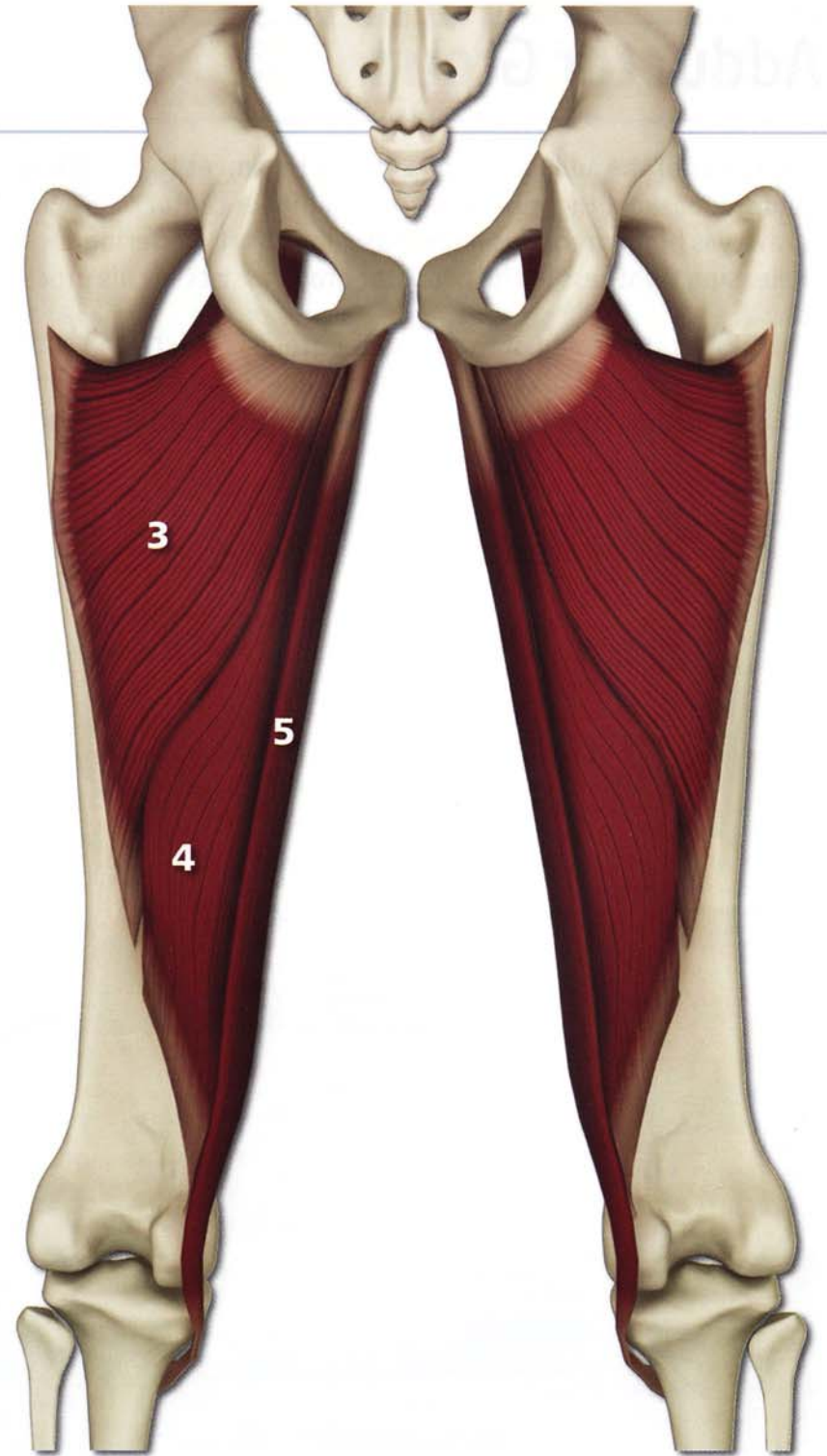
Stretched

The adductor magnus and the entire adductor group stretches in upavistha konasana (the more distal and posterior muscles are preferentially stretched).





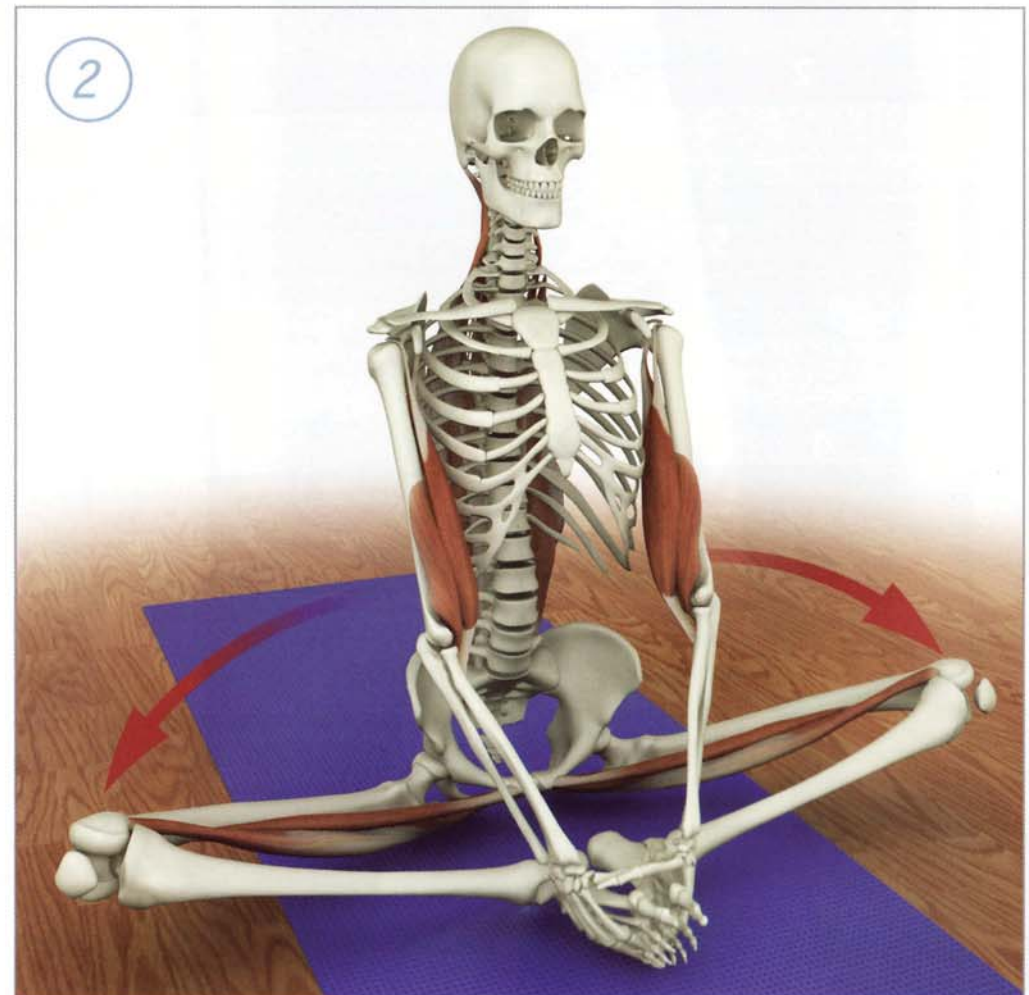
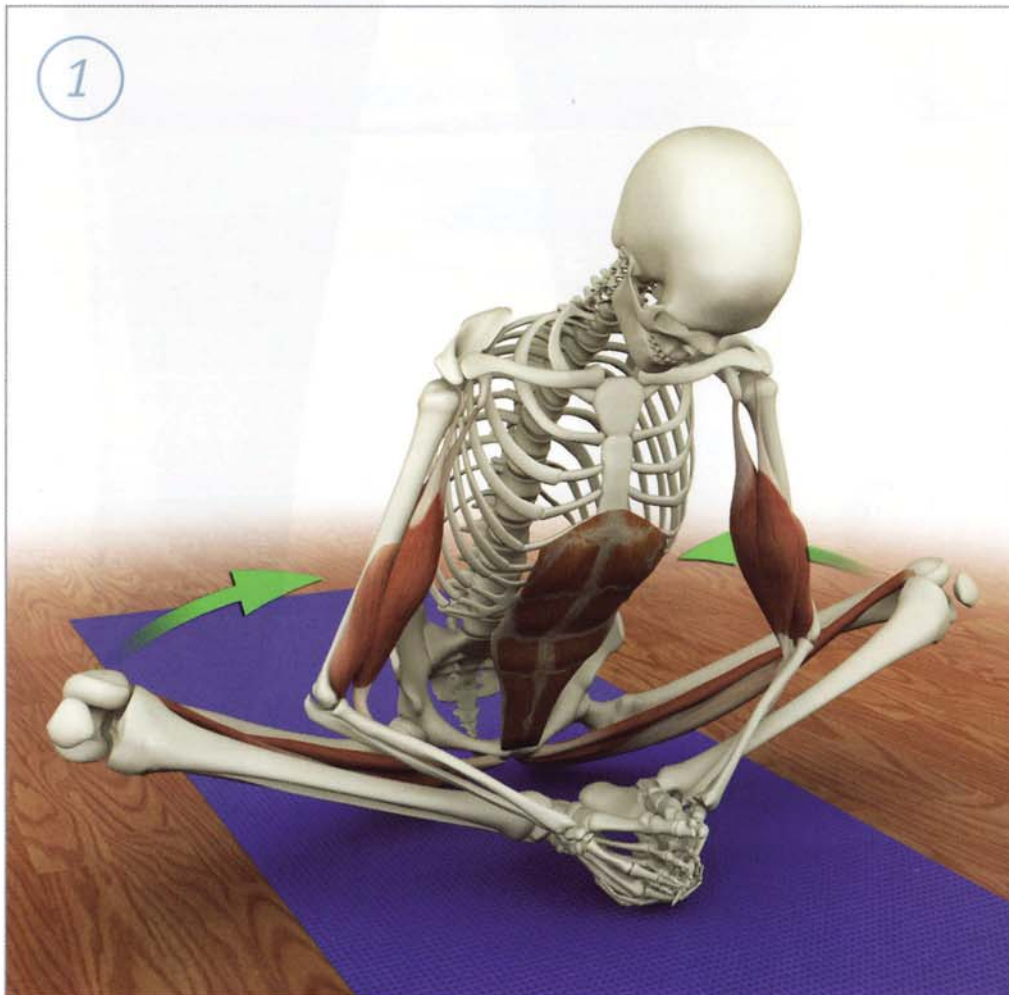
- 1**
pectineus
- 2**
longus
- 3**
brevis
- 4**
magnus
- 5**
gracilis



Adductor Group

Tightness of the adductor group causes the knees to be higher in seated postures, such as baddhakonasana and siddhasana. Higher knees means a higher center of gravity. Holding a seated posture where the center of gravity is higher requires more muscular effort. Lowering the knees makes these postures easier to maintain. Releasing tightness in the adductor group assists in this process.

Facilitated stretching of the adductor group is illustrated here. Begin by placing the legs into baddhakonasana and then attempt to adduct them while resisting them with the elbows. Contract the adductors isometrically for a few moments and then draw them out to length by lowering the knees.



baddhakonasana

Chapter 6

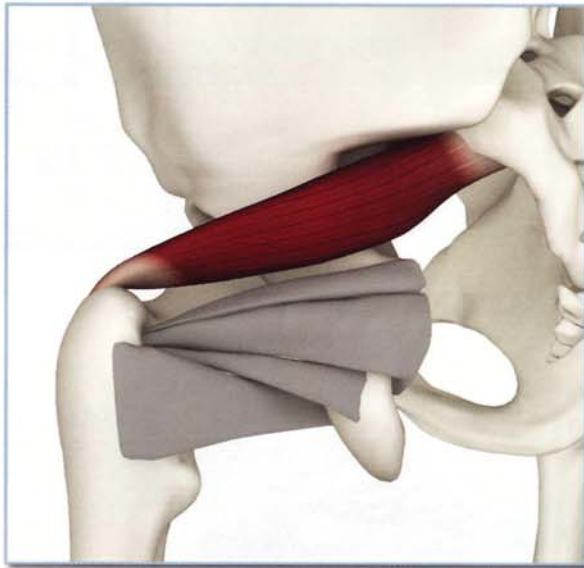
External Rotators

Piriformis & Quadratus Femoris

Piriformis (piri-FOR-mus):

This is a pyramid-shaped muscle originating from the inside of the pelvis at the sacrum. The piriformis wraps around the ilium and inserts on the tip of the greater trochanter on the proximal femur.

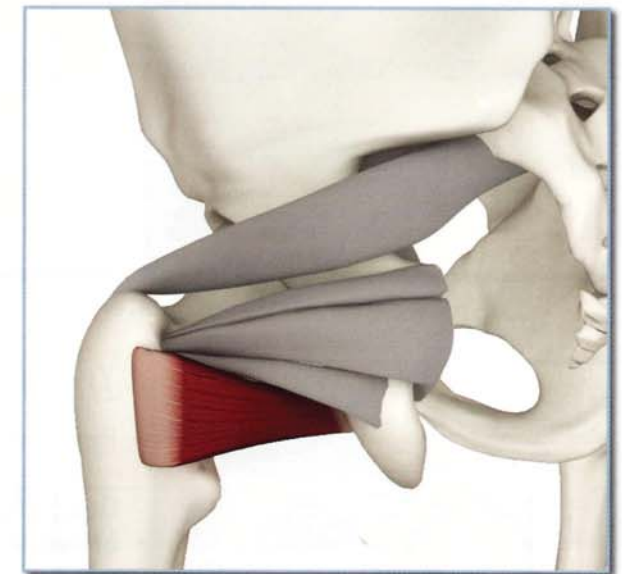
This creates a pulley effect multiplying the piriformis' force – much like what occurs with the iliopsoas as it curves over the front of the pelvis. The sciatic nerve runs behind the piriformis and can be irritated by tightness or inflammation of this muscle, a phenomenon known as “piriformis syndrome.” The piriformis acts in open and closed chain fashions. When its origin (the sacrum) is fixed, contraction produces external rotation and abduction of the femur. When the femur is fixed, contraction tilts the pelvis backward. Tightness in the piriformis limits internal rotation of the thigh in certain seated twists and in twisted standing poses.



Quadratus Femoris (KWA-drat-us fe-MOR-us):

This is the most distal of the external rotators. It is a quadrangular-shaped muscle originating from above the ischial tuberosity and inserting on the greater trochanter of the proximal femur. It is a synergist to the piriformis in external rotation of the femur. It is also an adductor of the femur and opposes the piriformis' capacity to abduct. Combined contraction of the two muscles externally rotates the thigh.

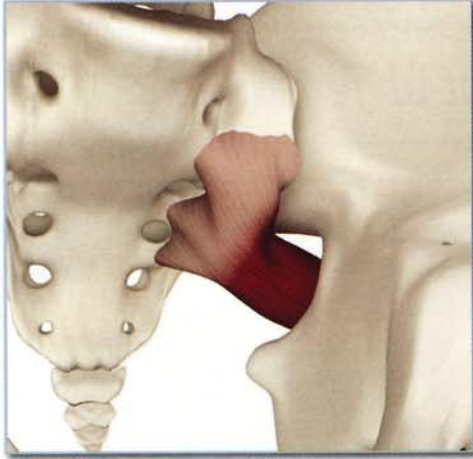
Tightness in the quadratus femoris limits internal rotation of the femur in certain seated twists and twisted standing poses. Contraction accentuates the effect of other seated twists and non-twisted standing poses. Awakening the piriformis and quadratus femoris muscles brings awareness to the neighboring gemelli and obturators (the other external rotators of the hip).



Piriformis & Quadratus Femoris

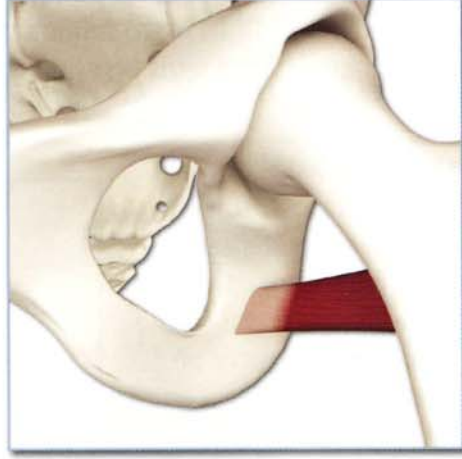
Origin-Piriformis

Inside surface of sacrum and sacrotuberous ligament.



Origin-Quadratus femoris

Lateral surface of ischial tuberosity.

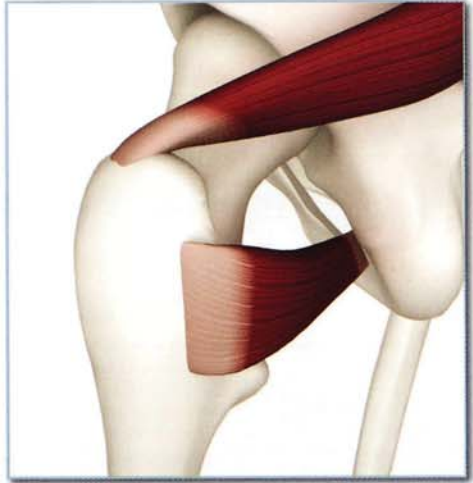
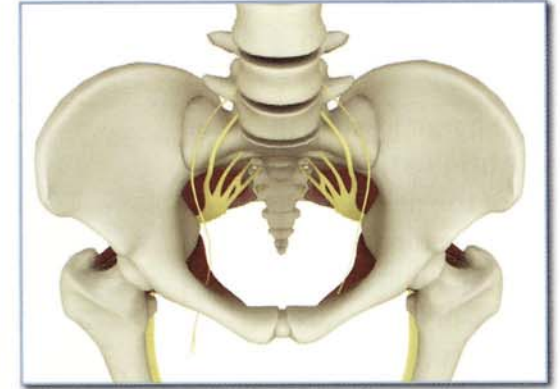
Innervation & chakra illuminated

Piriformis: Nerve to piriformis (sacral nerves 1 and 2).

Quadratus femoris: Nerve to quadratus femoris (lumbar nerves 4 and 5, and sacral nerve 1).

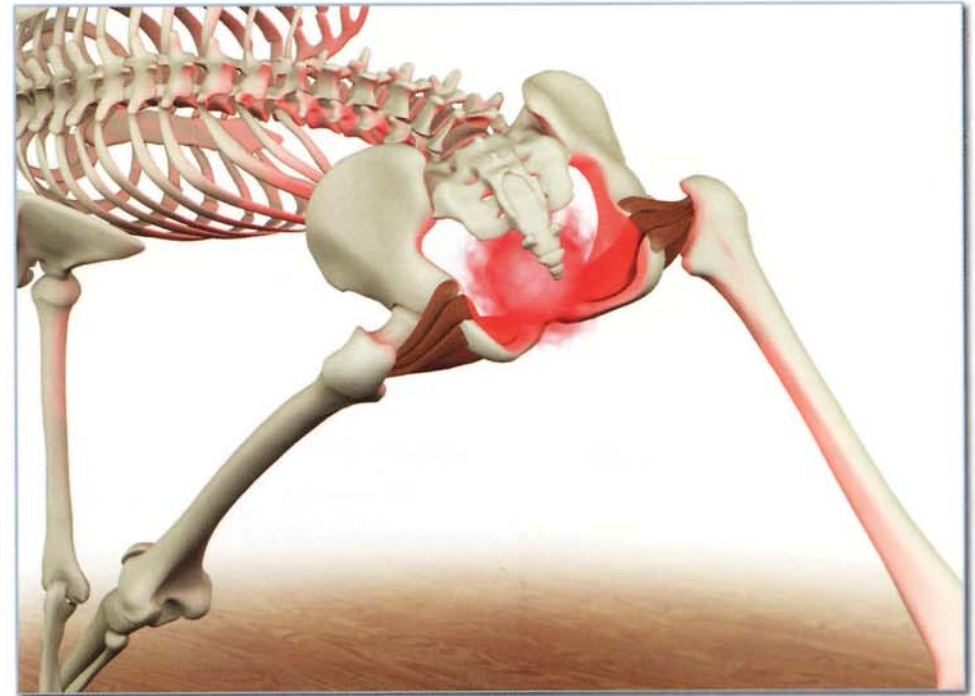
Chakra illuminated: First.



Insertion

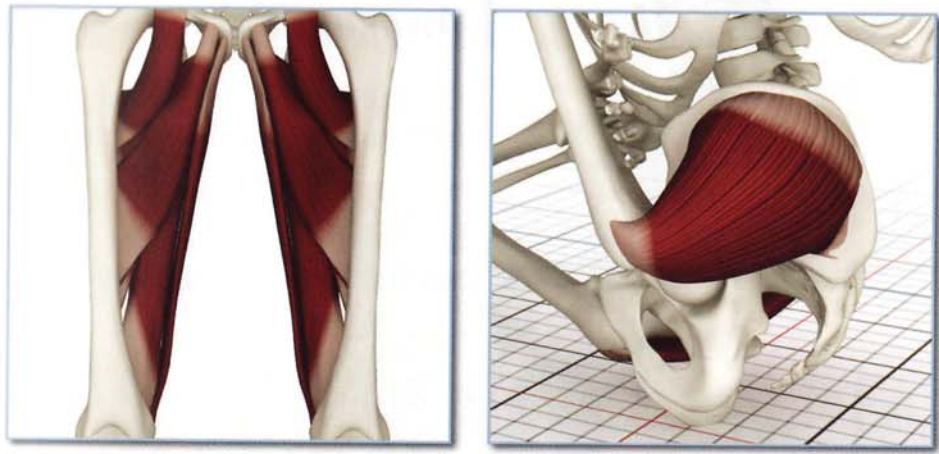
Piriformis: Tip of greater trochanter.

Quadratus femoris: Posterior surface of femur at the level of the greater trochanter.



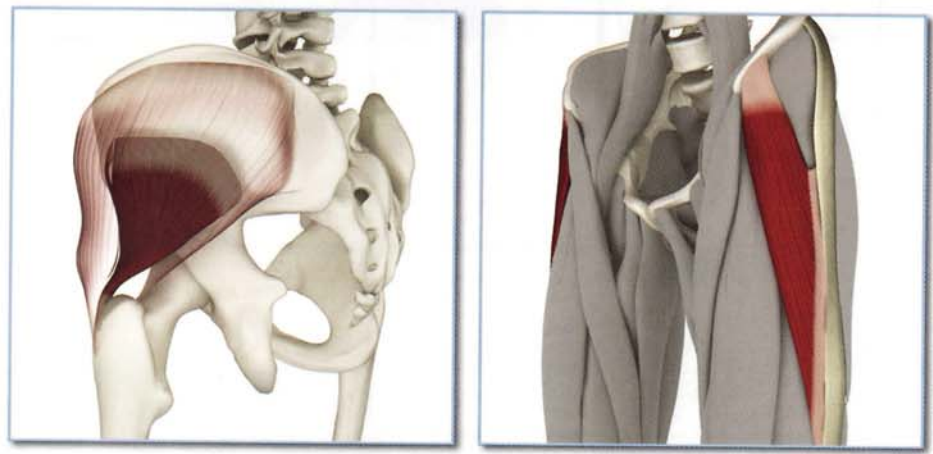
Antagonists-Piriformis

Adductor group and gluteus medius (anterior fibers).



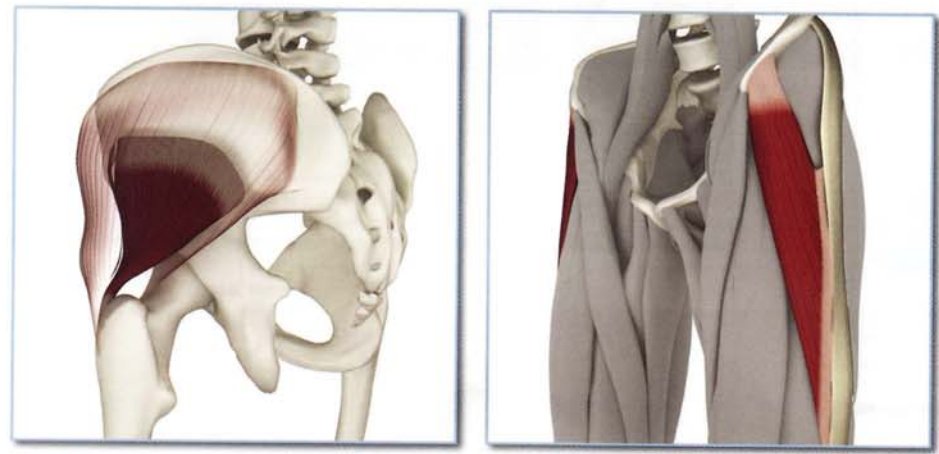
Synergists-Piriformis

Gluteus medius (lateral and posterior fibers), gluteus minimus and tensor fascia lata.



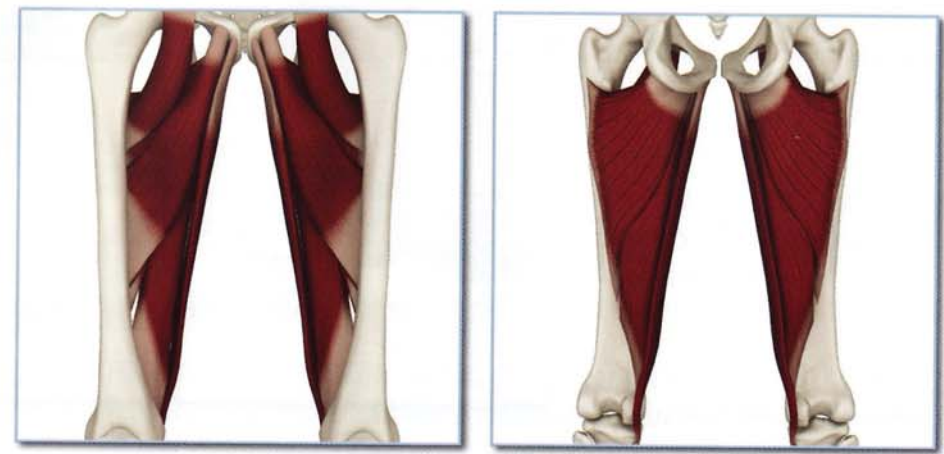
Antagonists-Quadratus femoris

Gluteus medius (anterior fibers), gluteus minimus and tensor fascia lata.

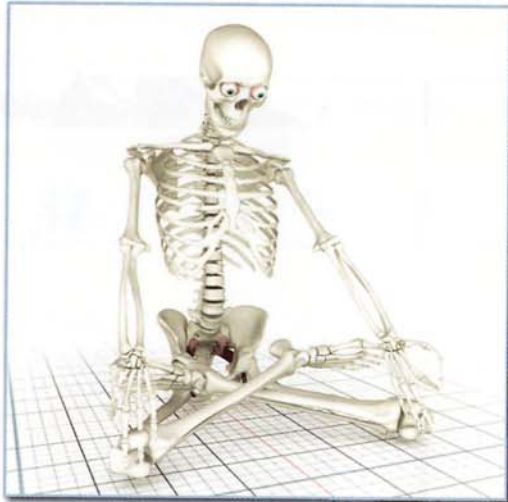

Synergists-Quadratus femoris

Adductor group.



Piriformis & Quadratus Femoris



Awakening

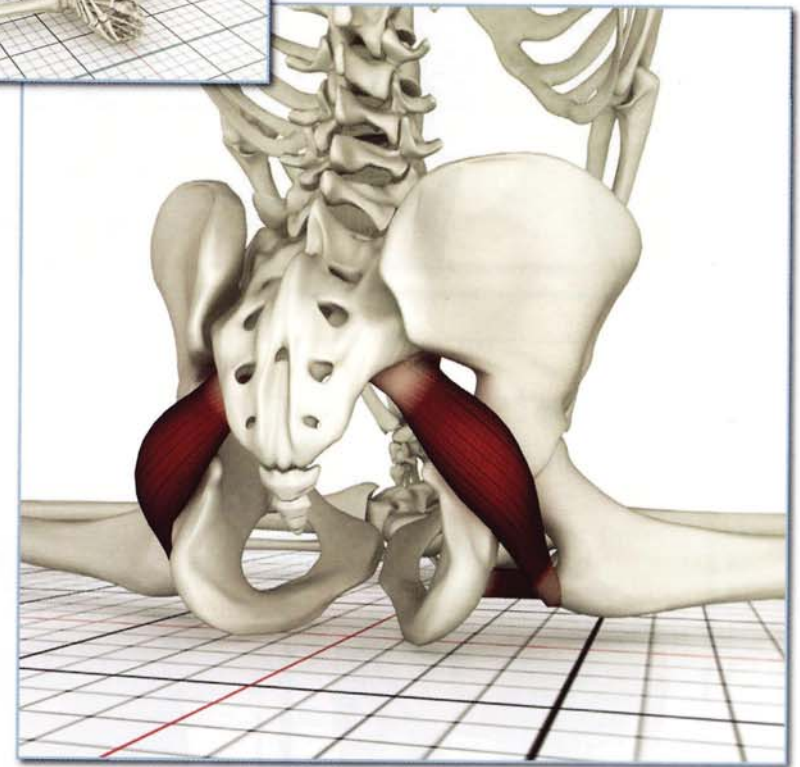
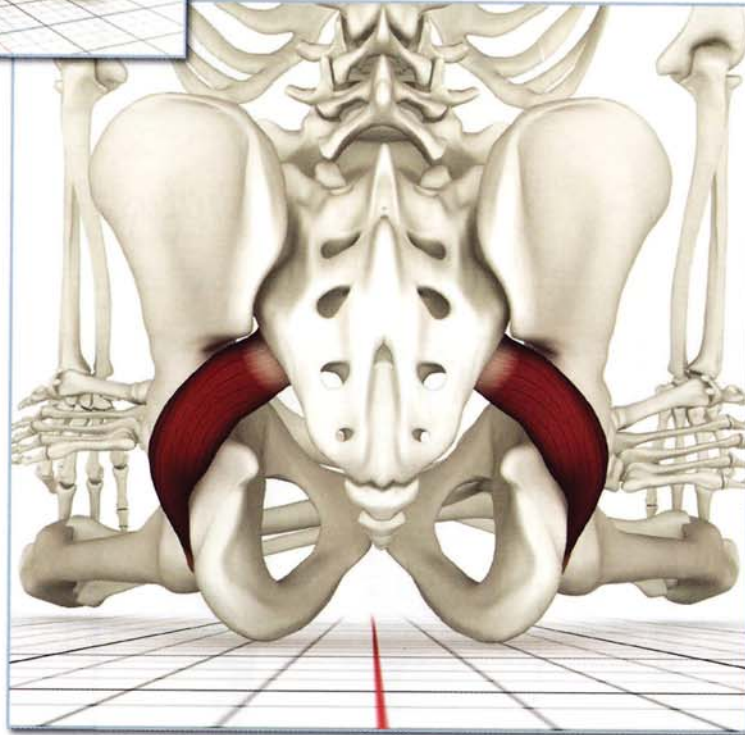
Contracting the external rotators accentuates baddhakonasana.

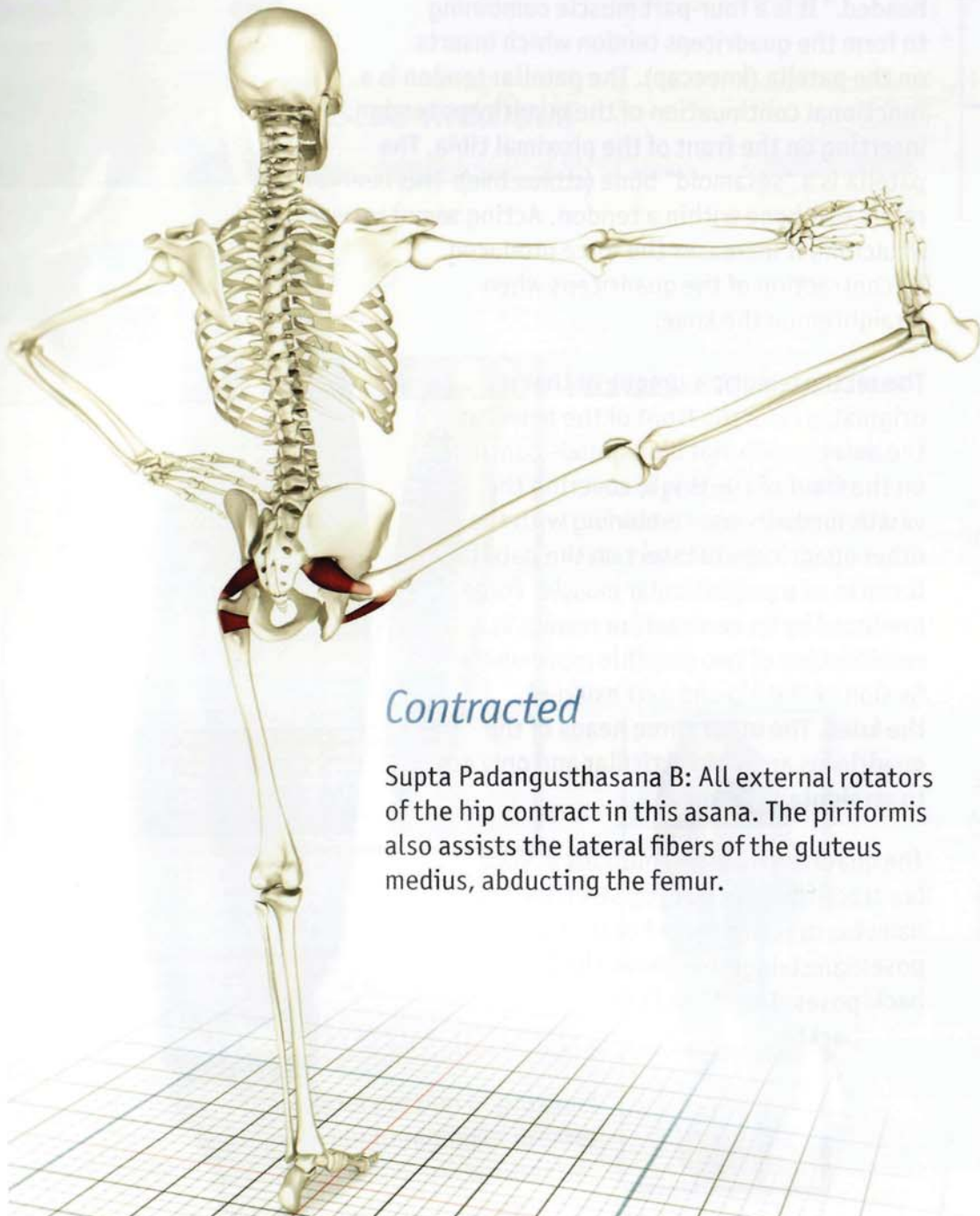
Action

The piriformis externally rotates and abducts the hip. The quadratus femoris externally rotates and adducts the hip.

Closed chain of the piriformis contraction tilts the pelvis backward.

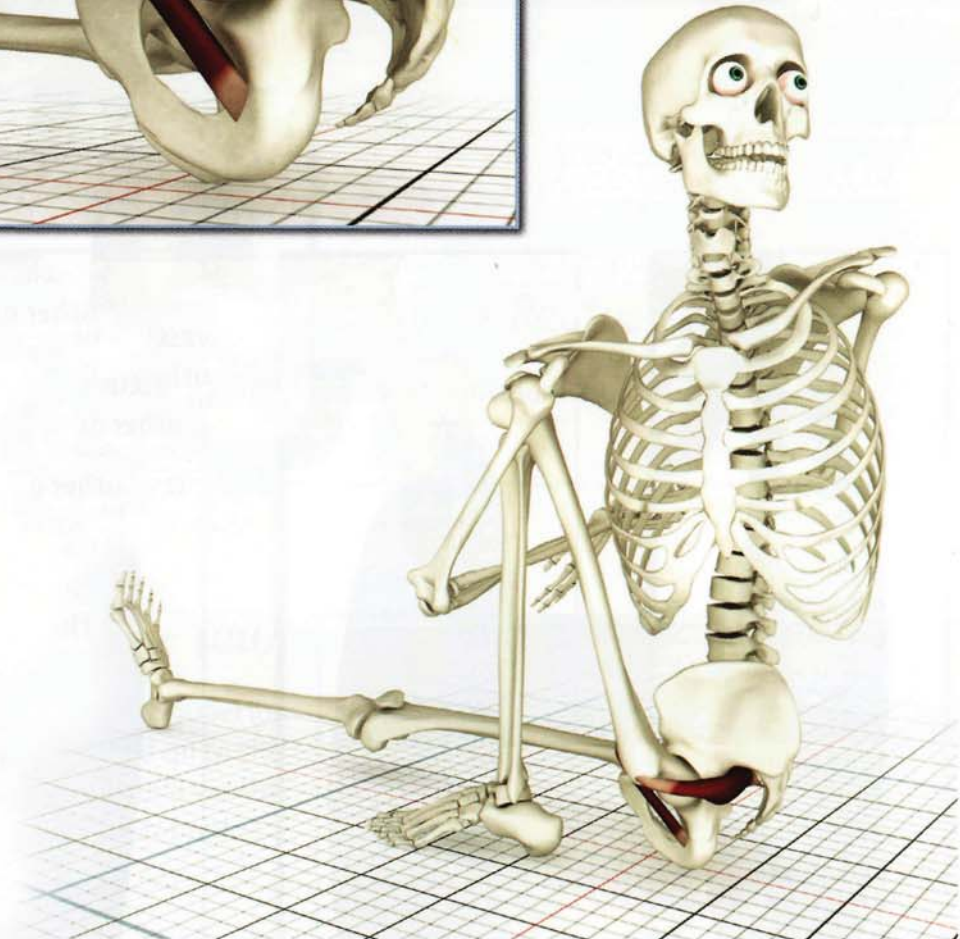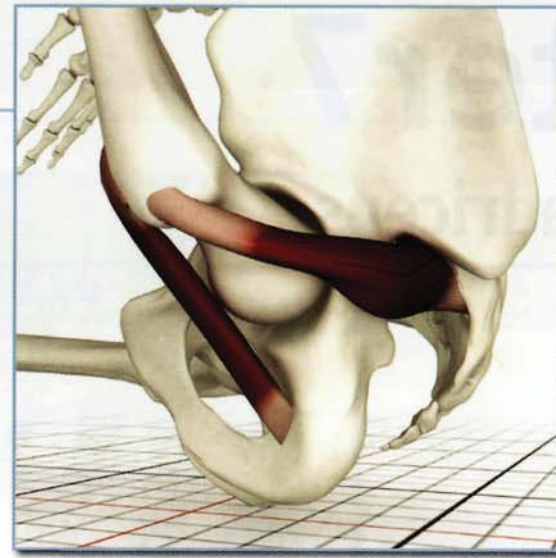
The external rotators position the hips in external rotation for padmasana.





Contracted

Supta Padangusthasana B: All external rotators of the hip contract in this asana. The piriformis also assists the lateral fibers of the gluteus medius, abducting the femur.



Stretched

Marichyasana III: Contracting the internal rotators of the hip (tensor fascia lata and anterior fibers of gluteus medius) in this asana stretches the external rotators.

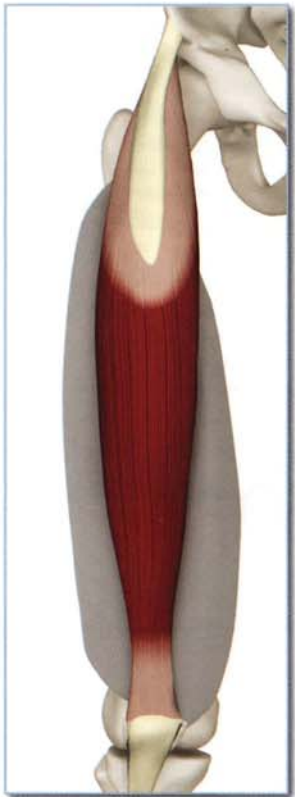
Chapter 7

Quadriceps

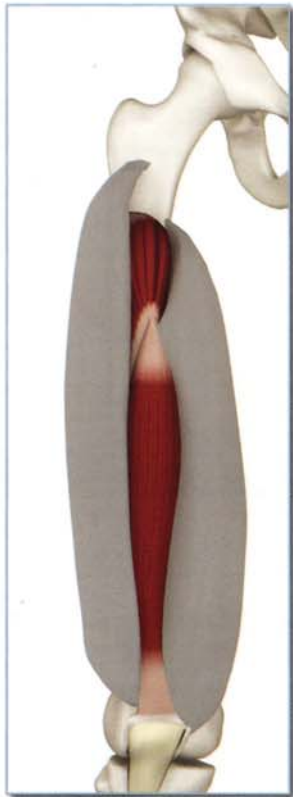
The quadriceps muscle forms the front of the thigh. Its name, derived from Latin, means “four headed.” It is a four-part muscle combining to form the quadriceps tendon which inserts on the patella (kneecap). The patellar tendon is a functional continuation of the quadriceps tendon, inserting on the front of the proximal tibia. The patella is a “sesamoid” bone (stone-like). This refers to a bone within a tendon. Acting as a fulcrum, it increases the force produced by contraction of the quadriceps when straightening the knee.

The rectus femoris – unique in that it originates from the front of the pelvis at the anterior-inferior iliac spine – continues on the front of the thigh, covering the vastus medialis and combining with the other quadriceps to insert on the patella. It works as a polyarticular muscle. Force produced by its contraction results in a combination of two possible movements: flexion of the hip and extension of the knee. The other three heads of the quadriceps are monoarticular and only act to straighten the knee.

The quadriceps are key muscles in yoga. Contracting them directly stretches the hamstrings when seated or in standing poses. They also straighten the knees in backbends, lifting the body.




rectus femoris



vastus intermedius

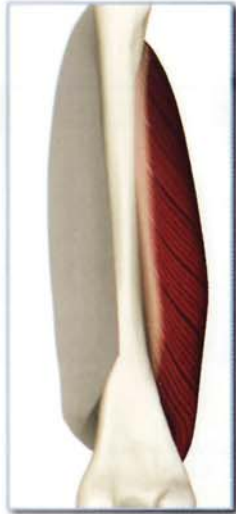

vastus medialis
vastus lateralis



Quadriceps (KWA-dra-seps)

Origin



Vastus medialis

Proximal two-thirds of the anterior femur.



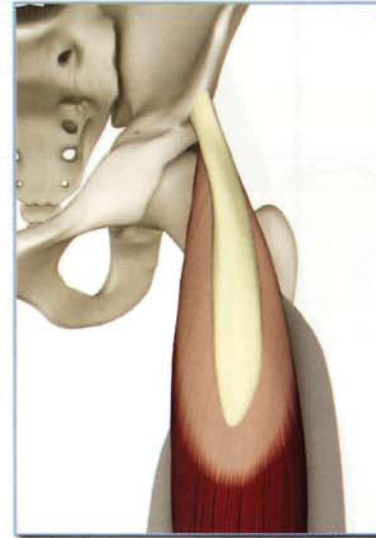
Vastus intermedius

Lateral portion of proximal femur in region of greater trochanter (seen through the vastus lateralis).



Vastus lateralis

Lateral portion of proximal femur in region of greater trochanter.

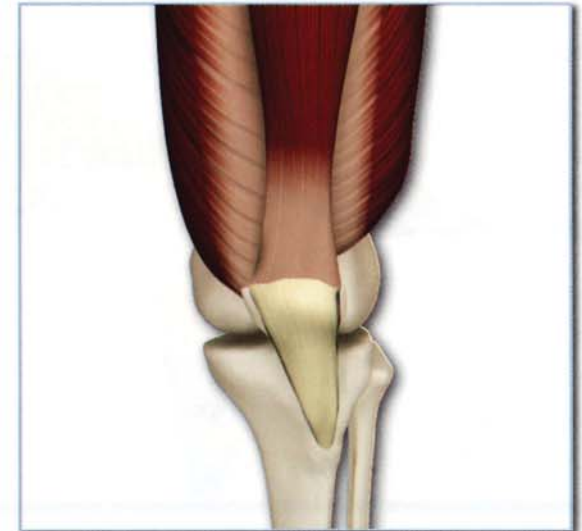


Origin - Rectus femoris

Anterior inferior iliac spine.

Insertion - (all)

Quadriceps tendon: Superior surface of patella (and on to the anterior proximal tibia via the patellar tendon).



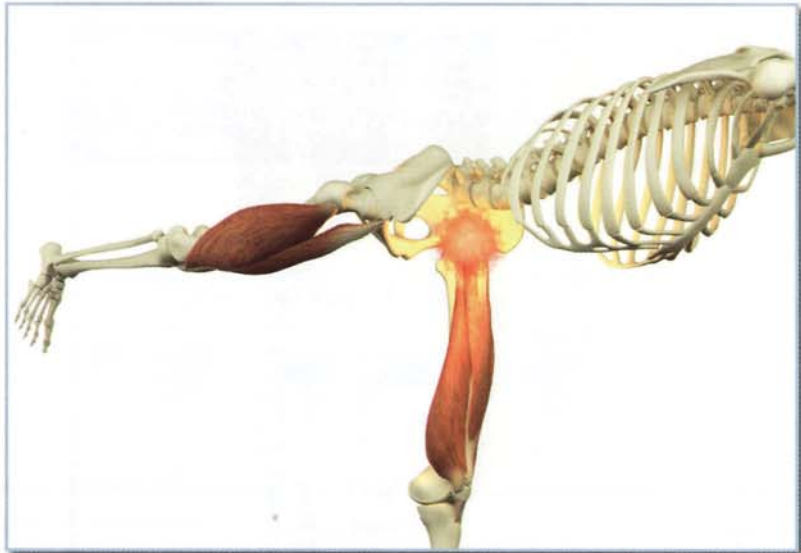
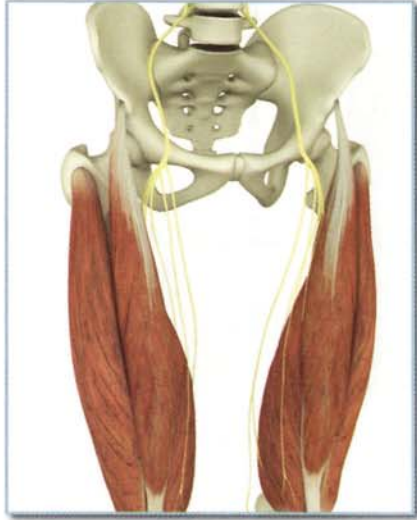Quadriceps

Innervation & chakra illuminated

Femoral nerve (lumbar nerves 2, 3 and 4).

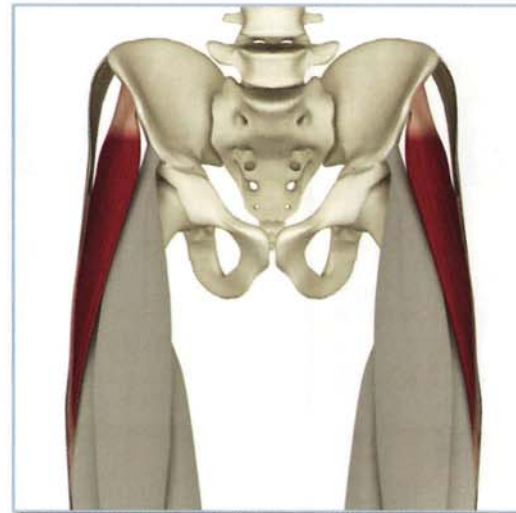
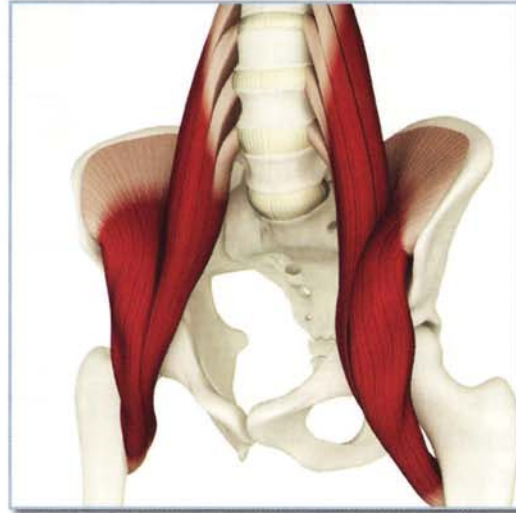Chakra illuminated:

Second.



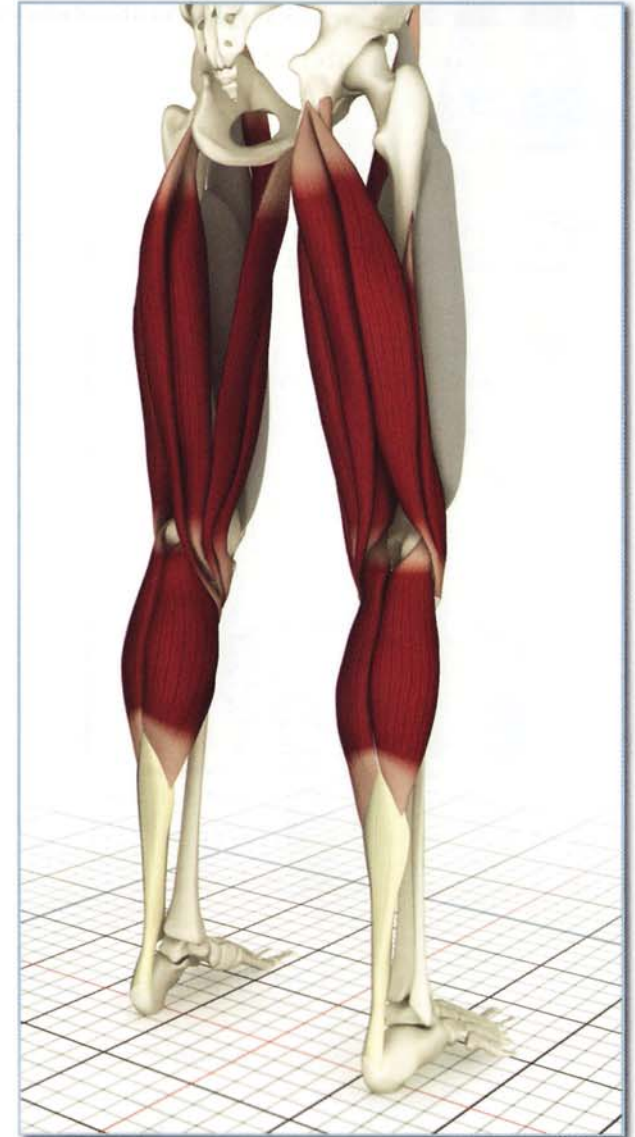Synergists

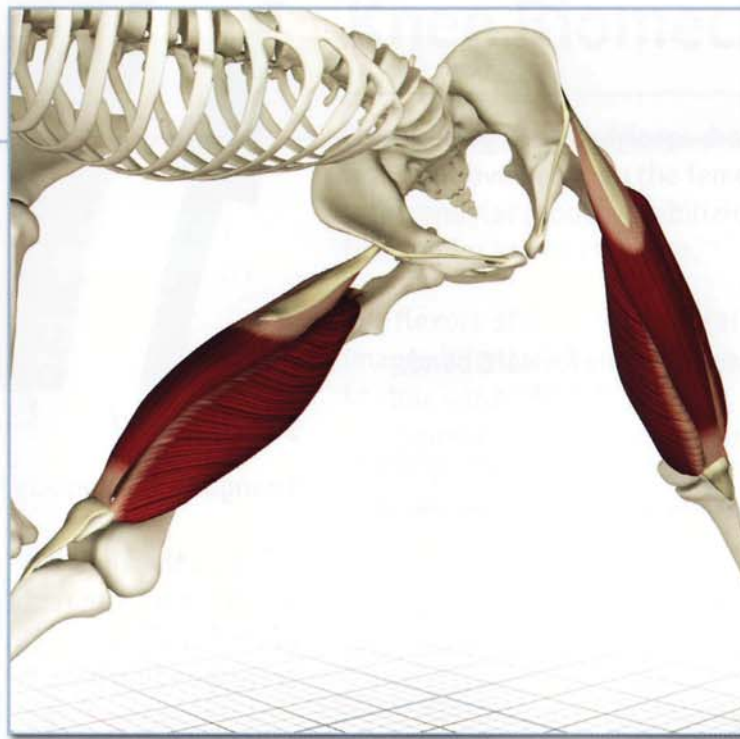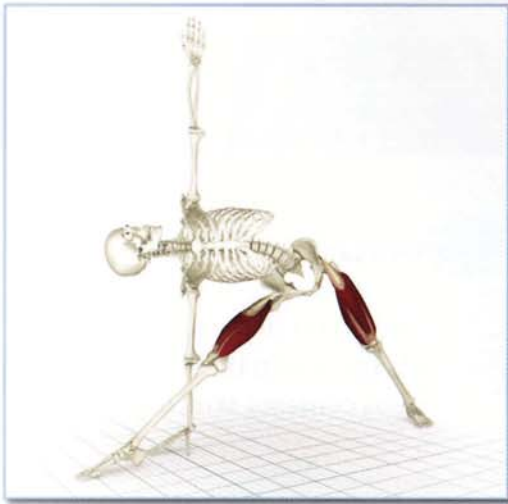Iliopsoas, tensor fascia lata.



Antagonists

Hamstrings, gastrocnemius, sartorius and gracilis.

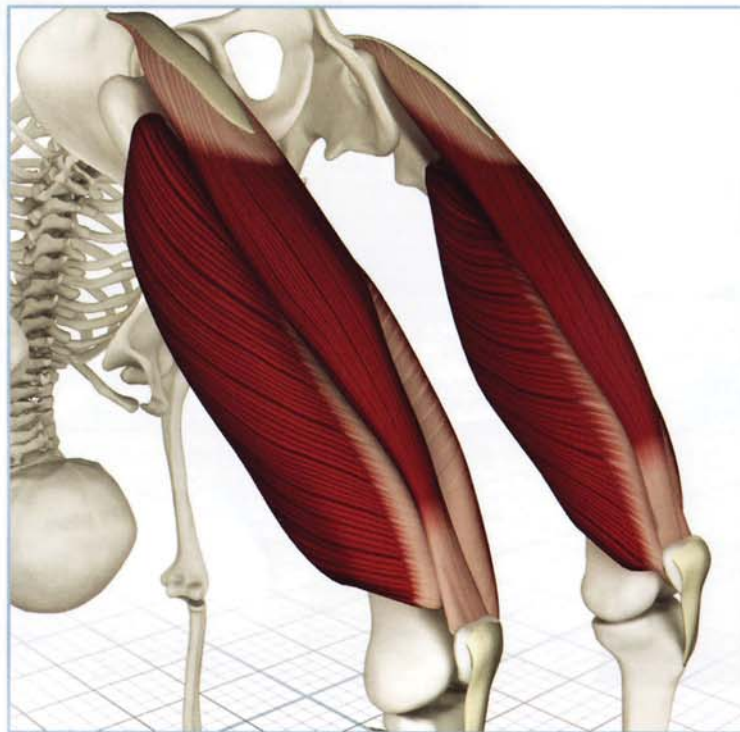
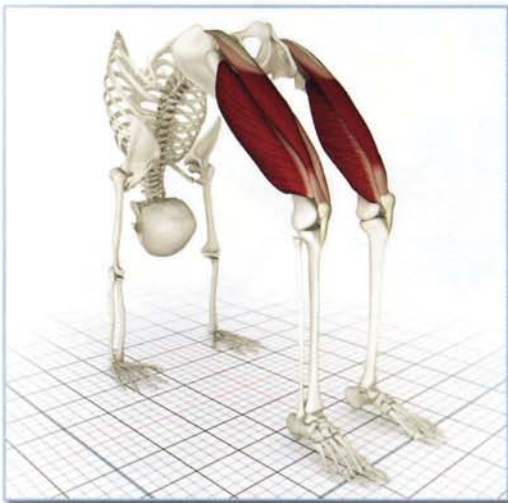


Action

Extends knee.

Rectus femoris also flexes hip.
The quadriceps contract, extending the knee and flexing the hip (rectus femoris) in utthita trikonasana.



Awakening

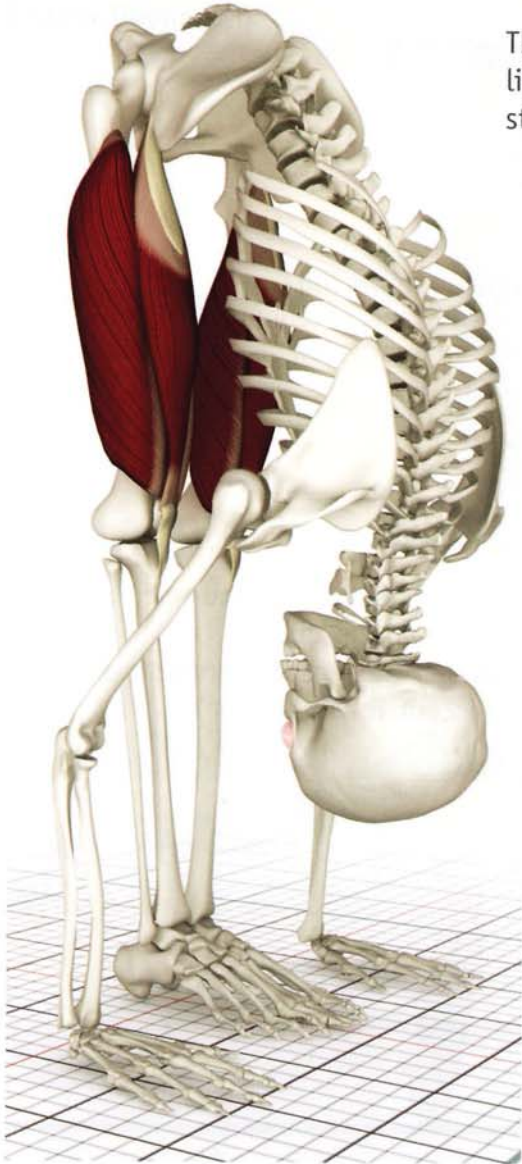
The vastus lateralis, medialis and intermedius contract straightening the knee in urdhvadhanurasana. The rectus femoris stretches and contracts (eccentric contraction).

Quadriceps

Contracted

Utthanasana:

The quadriceps contract in this forward bend, lifting the patella, straightening the knee and stretching their antagonists (the hamstrings).



Stretched

Trianga Mukhaikapada Paschimottanasana:

Bending the knee stretches the vastus lateralis, medialis and intermedius. The rectus femoris relaxes due to the flexed position of the hip. The straight leg quadriceps contract stretching the corresponding hamstrings.



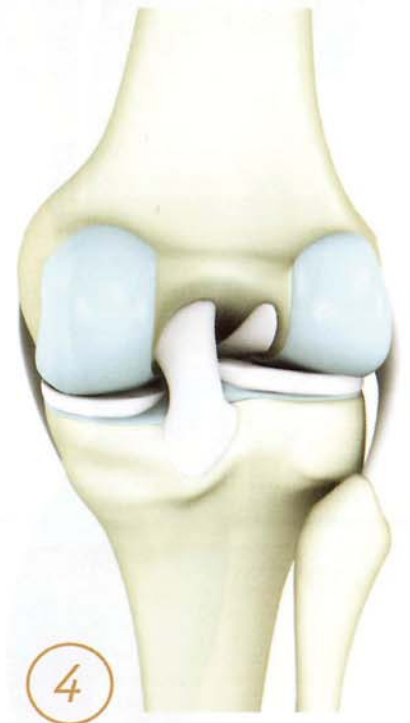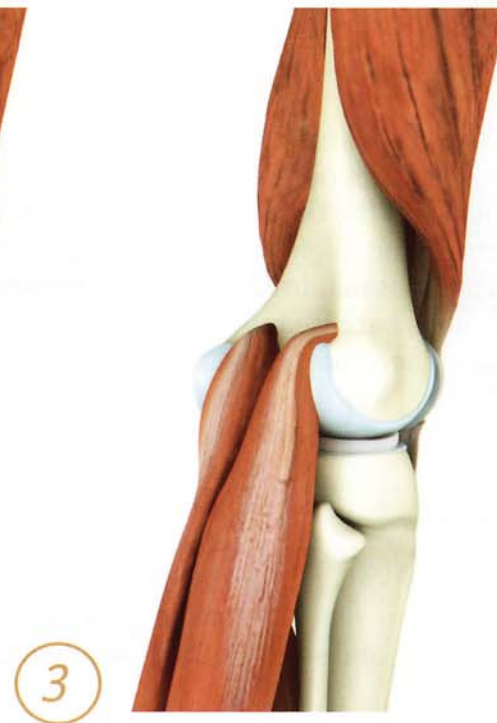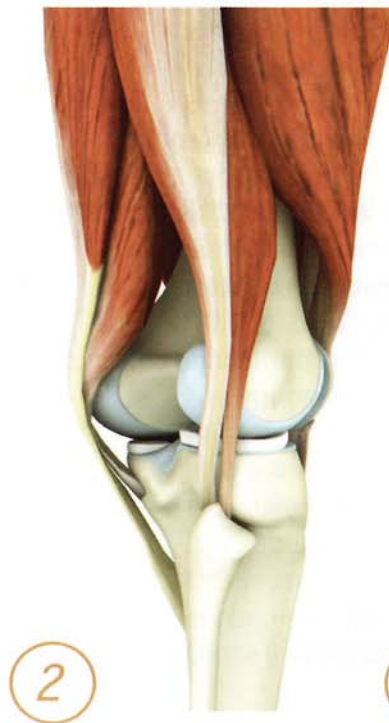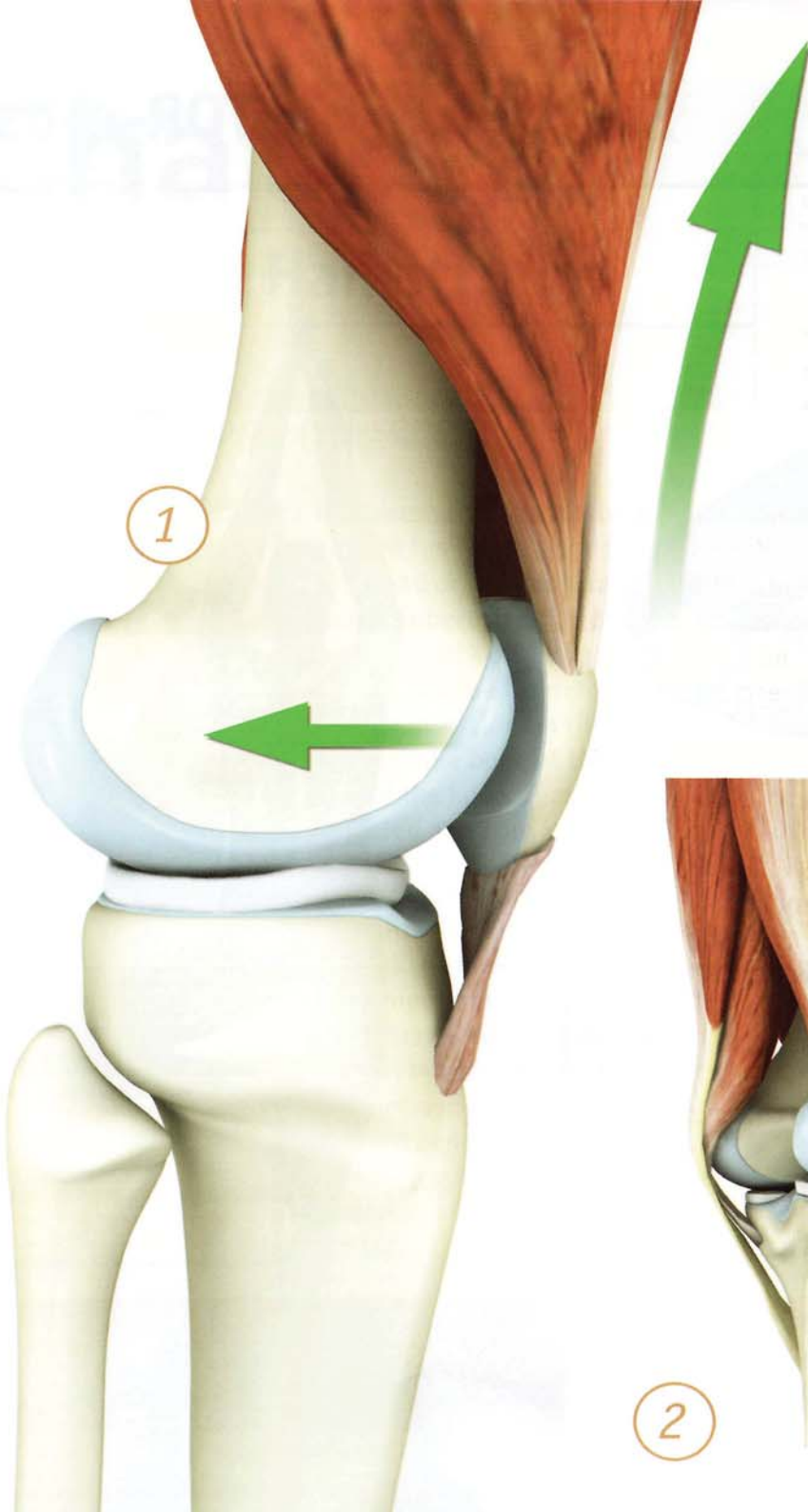
Knee Biomechanics

Contracting the quadriceps draws the patella upward and against the anterior femur into a groove between the femoral condyles. The patella fits congruently into the intercondylar groove, stabilizing the standing leg. In this way the patella acts as a fulcrum for knee extension.

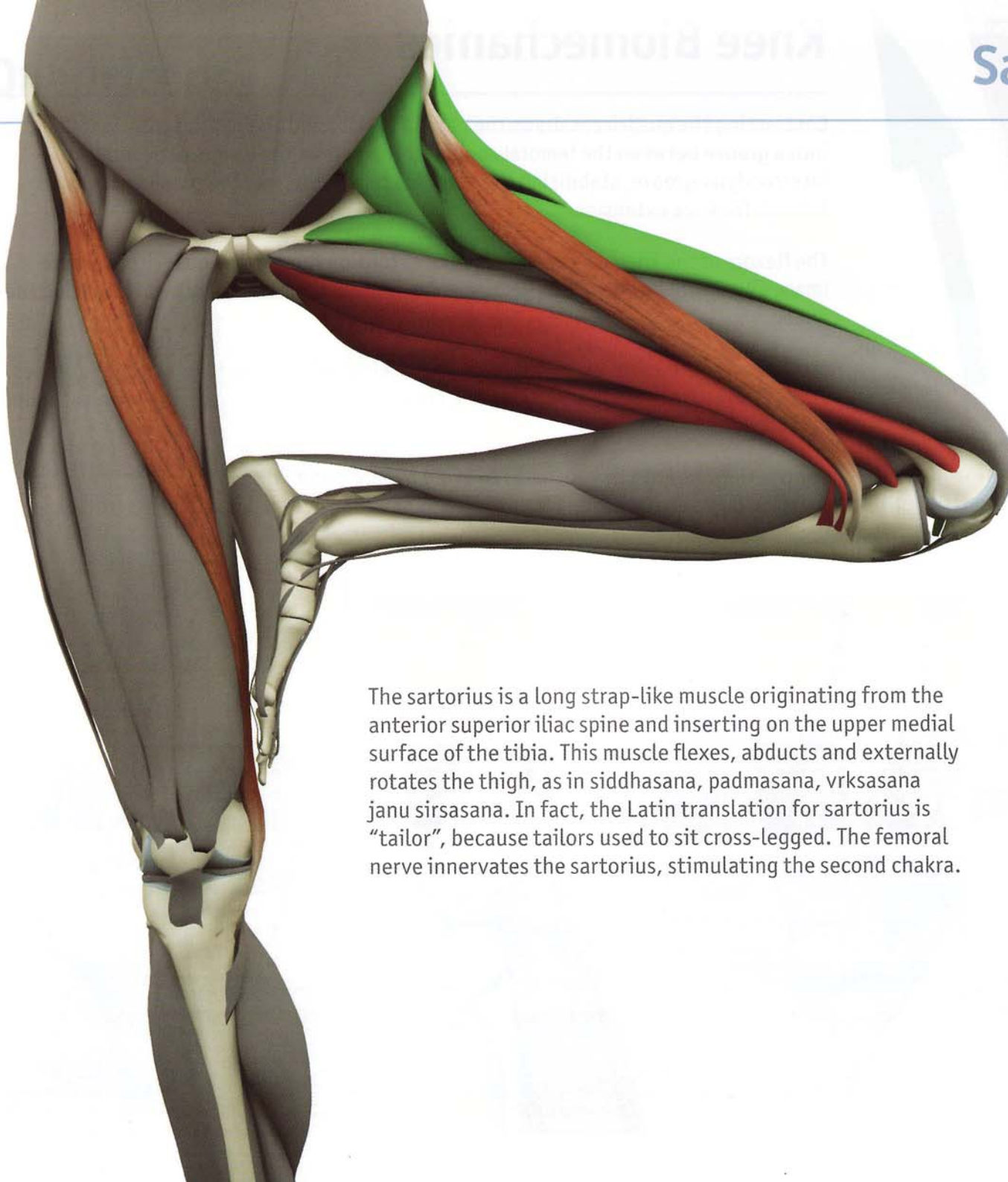
The flexors of the knee counterbalance the extension force of the quadriceps. These images illustrate how the knee flexors and extensors oppose each other, stabilizing the knee.

It is important to avoid hyperextension or “locking” of the knee during standing poses. This can overstretch the hamstrings and creates unhealthy stress on the knee’s articular cartilage.

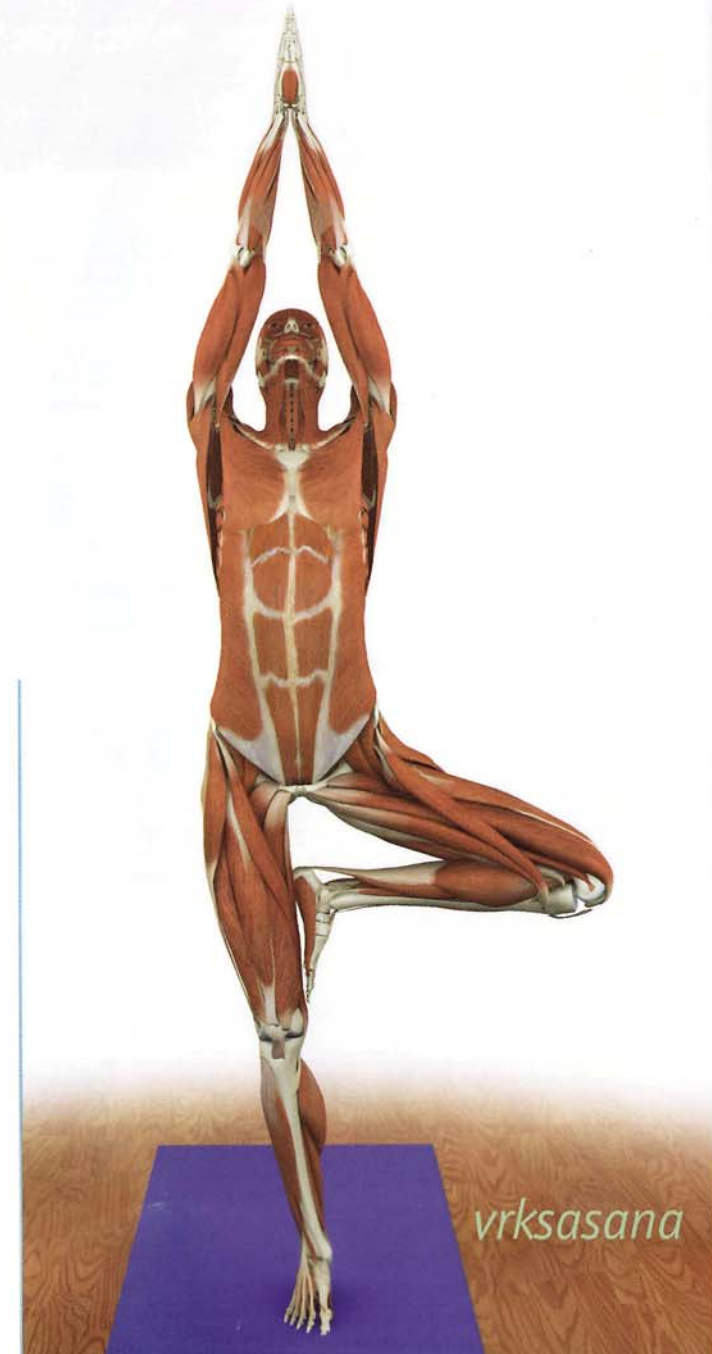
Contracting the knee flexors helps to avoid hyperextending the knee. For example, pressing down the ball of the foot contracts the gastrocnemius, stabilizing the knee.



Sartorius (sar-TOR-e-us)



The sartorius is a long strap-like muscle originating from the anterior superior iliac spine and inserting on the upper medial surface of the tibia. This muscle flexes, abducts and externally rotates the thigh, as in siddhasana, padmasana, vrksasana janu sirsasana. In fact, the Latin translation for sartorius is "tailor", because tailors used to sit cross-legged. The femoral nerve innervates the sartorius, stimulating the second chakra.



vrksasana

Chapter 8

Hamstrings

Biceps Femoris (BI-seps fe-MOR-us)



The biceps femoris is a two-headed fusiform-shaped muscle. One head originates from the ischial tuberosity, the other from the back of the femur. Both heads combine forming a single tendon insertion on the head of the fibula bone at the lateral side of the knee. It can be palpated as a cord in this region.


The biceps femoris flexes the straight knee and outwardly rotates the lower leg (in the bent knee). Its rotary action accentuates twisting postures such as marichyasana III. Tightness in this muscle limits forward bends and certain standing poses, especially those involving internal rotation of the leg.

Semitendinosus (sem-e-ten-di-NO-sus)

Semimembranosus (sem-e-mem-bruh-NO-sus)

These two muscles make up the inner hamstrings. The semimembranosus has a flattened wide belly. The semitendinosus is fusiform in shape (tapered at both ends) with the distal end forming a long tendon. Both muscles originate from the ischial tuberosity. They have separate insertions on the proximal tibia, one on the inside of the back of the tibia (semimembranosus) and one on the inside of the front of the tibia (semitendinosus). The semitendinosus insertion combines with the sartorius and gracilis muscles to form a broad duckfoot-like insertion on the anterior tibia called the pes anserinus.

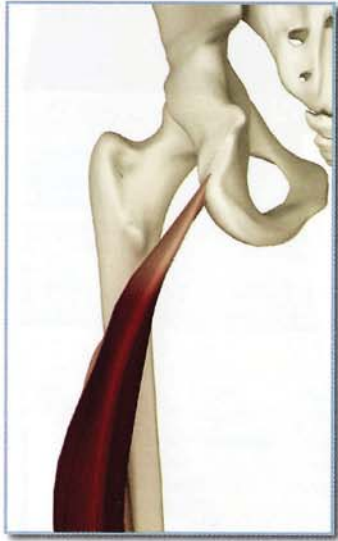
The semimembranosus and semitendinosus flex the straight knee, inwardly rotating the lower leg in the bent knee. This rotary component accentuates seated twists, but in the opposite direction of the biceps femoris. Contraction of these muscles also assists the gluteus maximus in extension of the thigh at the hip, as in virabhadrasana III. Tightness in this muscle limits forward bends and certain standing poses, especially those involving external rotation of the leg.



Semitendinosus Semimembranosus

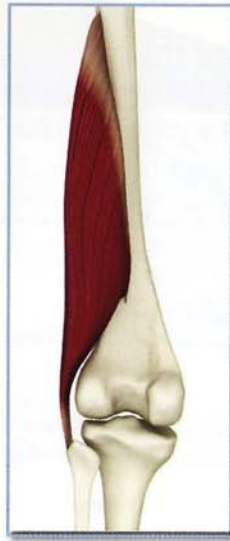
Hamstrings

Origin-Biceps femoris



Long head:

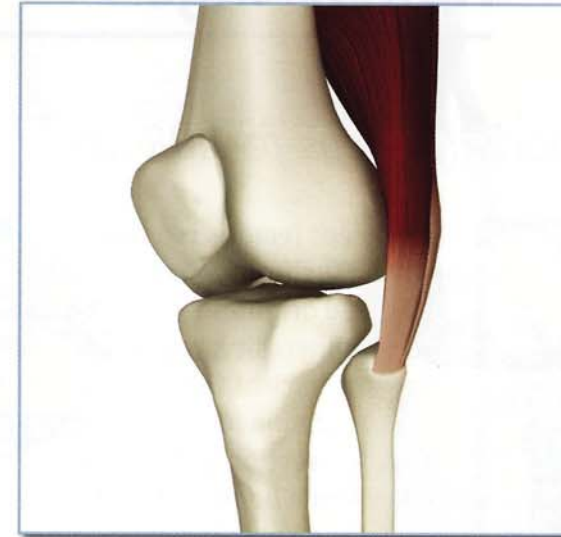Ischial tuberosity
(Long head origin
is shared with the
semitendinosus.)



Short head:

Linea aspera on upper two
thirds of posterior femur.

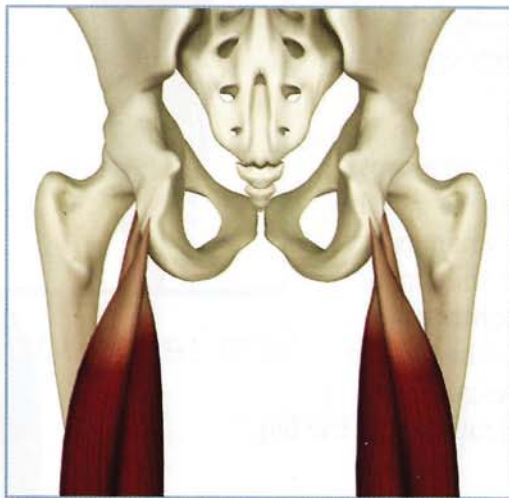
Insertion-Biceps femoris



Head of fibula.

Origin-Semimebranosus & Semitendinosus

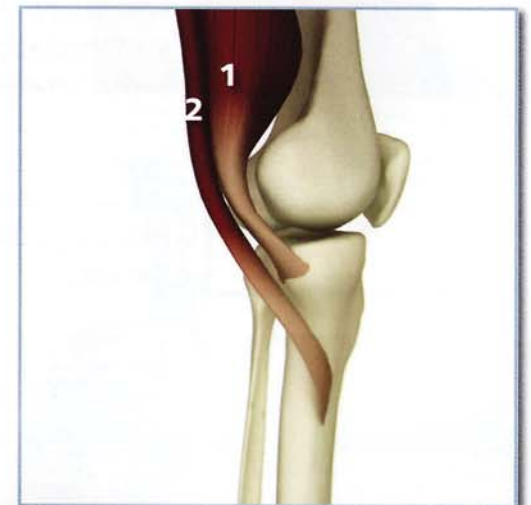Ischial tuberosity:
(Semitendinosus origin is
shared with the long head of
biceps femoris).



Insertion-Semimebranosus & Semitendinosus

1) Semimembranosus:
Posteromedial surface of proximal
tibia. Some fibers join to form
oblique popliteal ligament and attach
to posterior medial meniscus.

2) Semitendinosus:
Upper inner surface of proximal tibia
(contributes to pes anserinus).



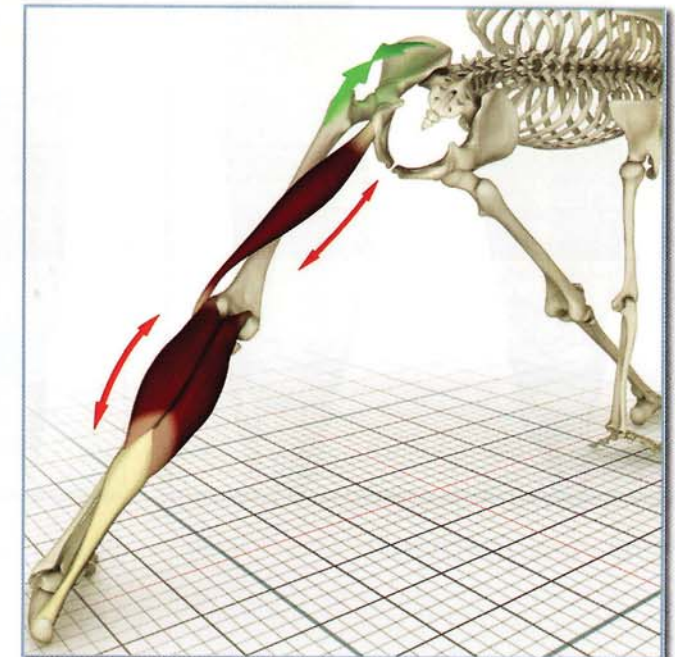
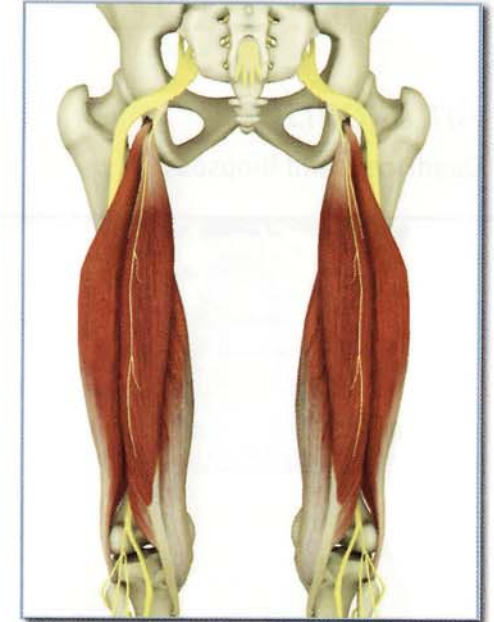
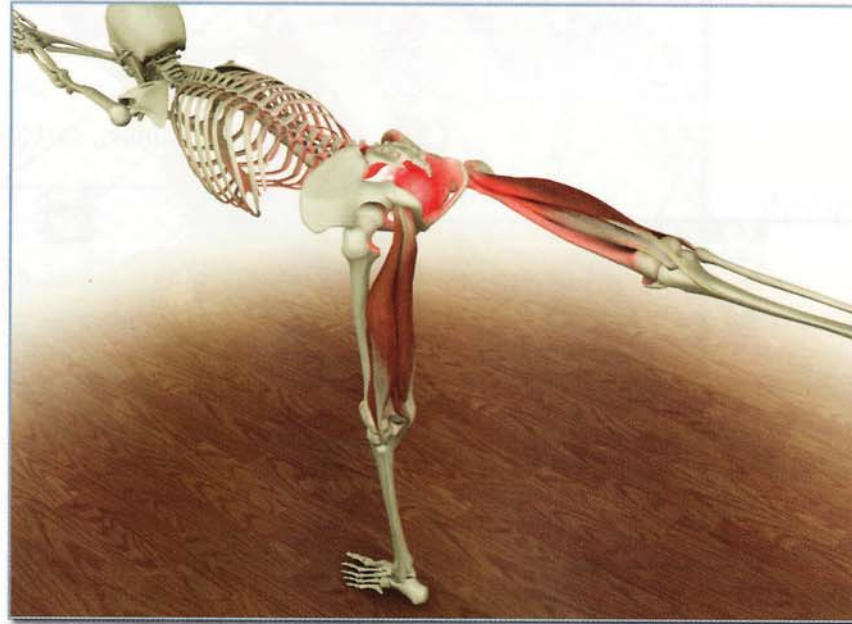
Innervation & chakra illuminated

Biceps femoris

- 1) Long head: Tibial portion of sciatic nerve (sacral nerves 1 and 2).
- 2) Short head: Fibular portion of sciatic nerve (lumbar nerve 5, and sacral nerves 1 and 2)

Semimebranosus & Semitendinosus Tibial nerve (lumbar nerve 5 and sacral nerve 1).

Chakra illuminated: First.

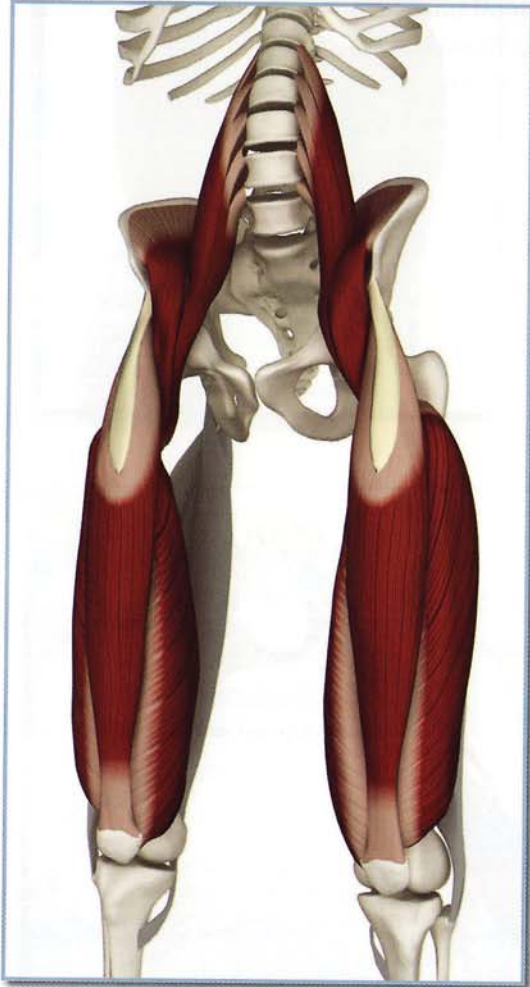

Gluteus maximus (illustrated by green arrow) extending hip and knee, stretching long head of the biceps femoris (and gastrocnemius).

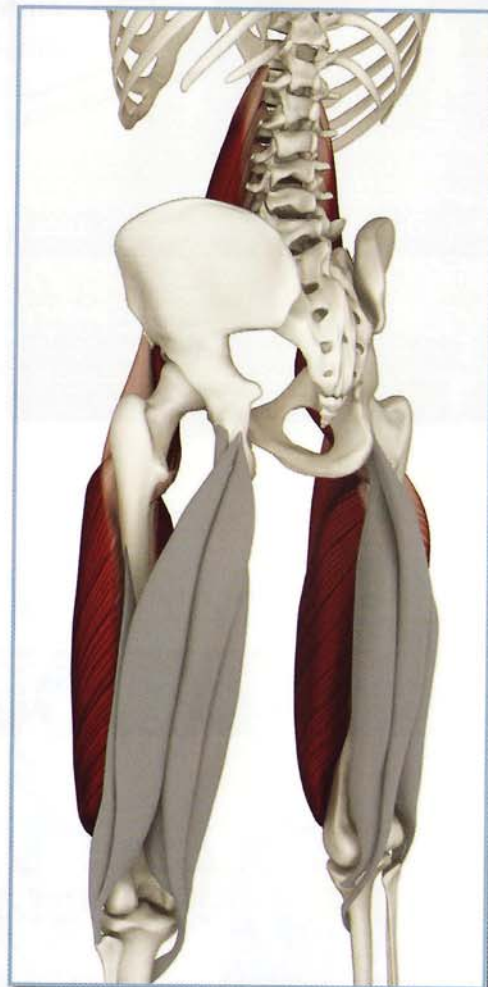
Hamstrings

Antagonists

Quadriceps and iliopsoas.



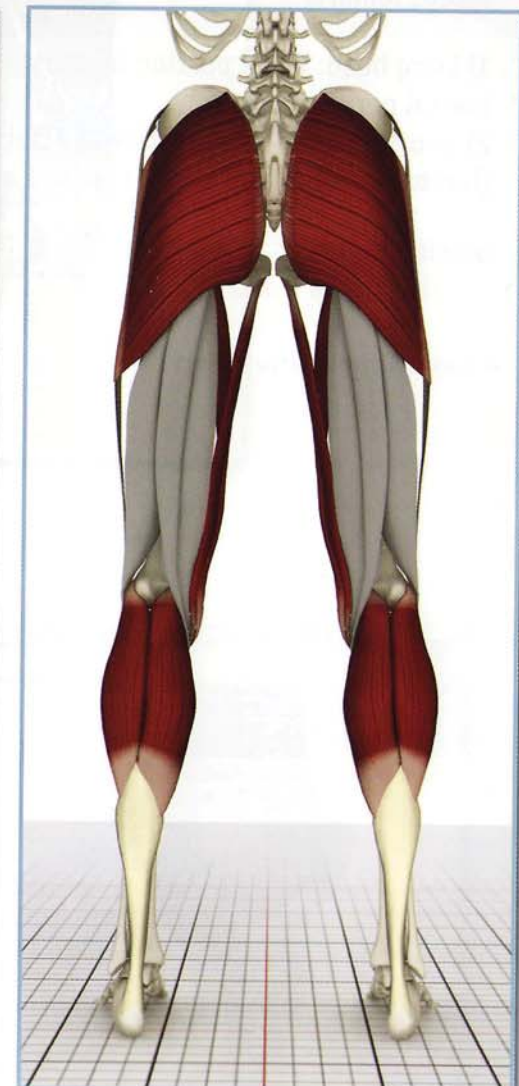
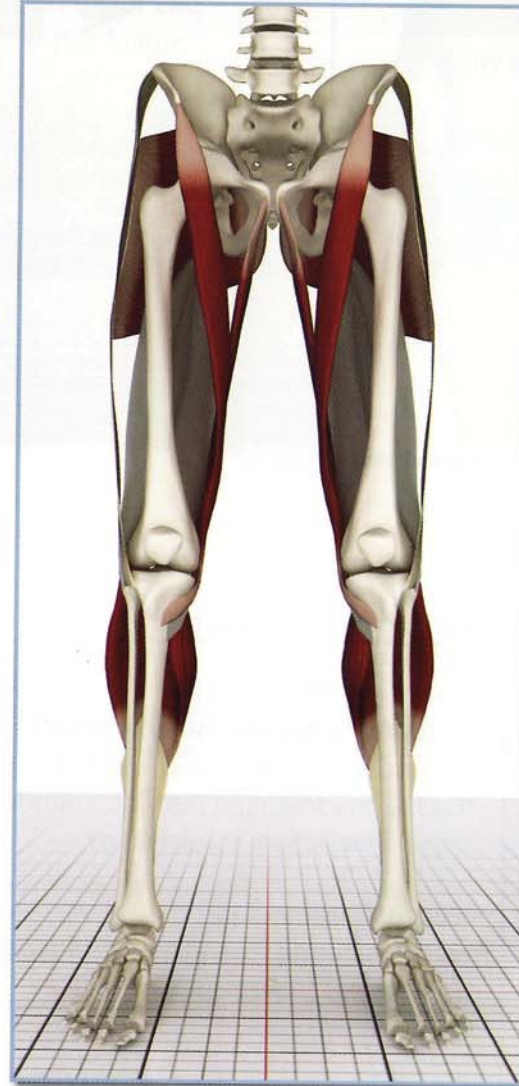
Front view (anterior)



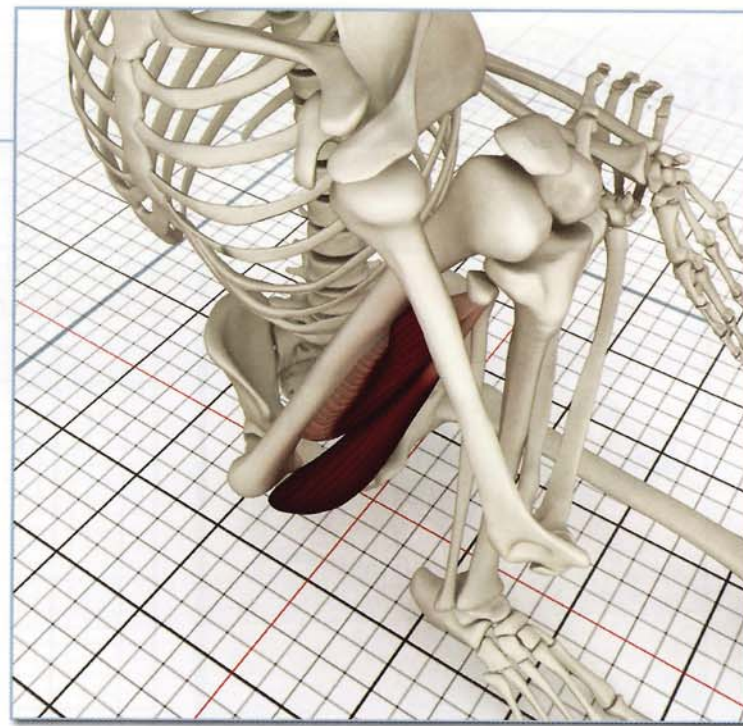
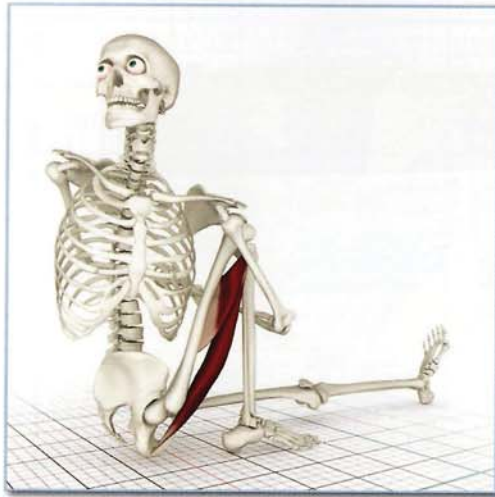Back view (posterior)

Synergists

Gluteus maximus, sartorius, gracilis and gastrocnemius.



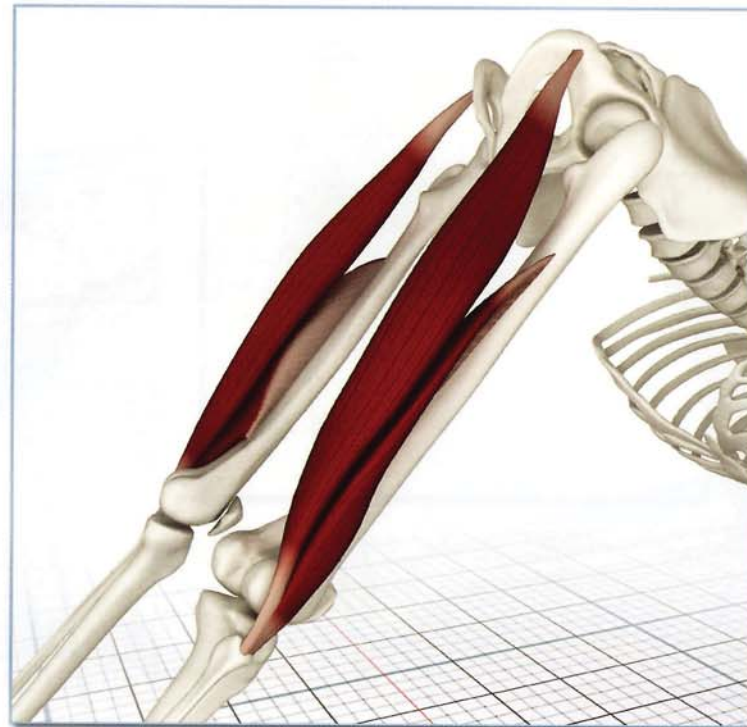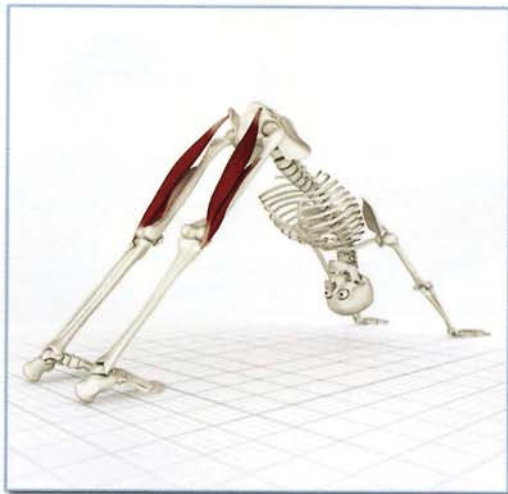Biceps femoris



Action

Flexes knee and extends hip (long head).
Externally rotates tibia in flexed knee.

The biceps femoris contracts, flexing the knee and externally rotating the tibia in marichyasana III. This external rotation manifests as internal rotation of the hip, accentuating the twist of the trunk.



Awakening

Adho Mukha Svanasana stretches and awakens the biceps femoris.

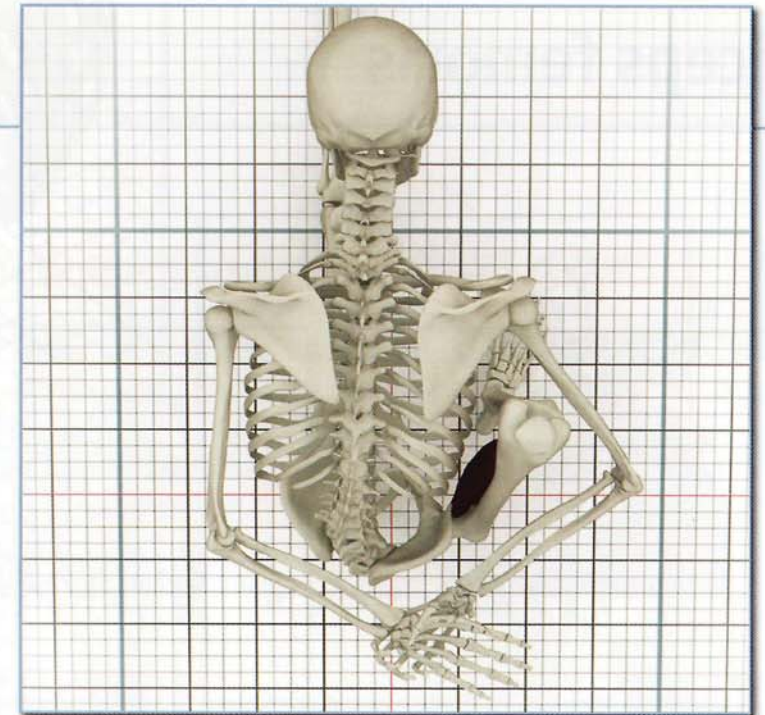

Semimebranosus & Semitendonosus

Antagonists
Quadriceps and Gluteus

Action

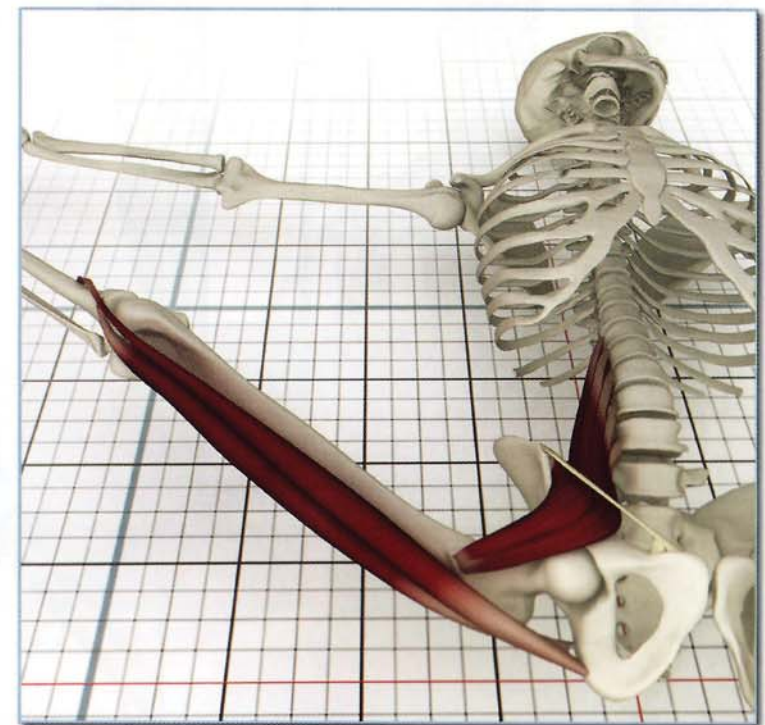
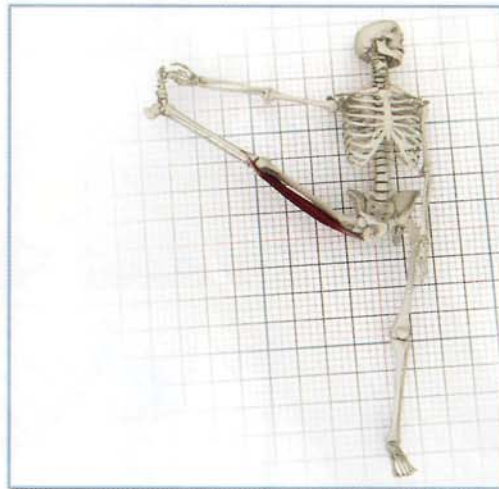
Flexes knee and extends hip.
Internally rotates the tibia in the flexed knee.

The semimembranosus and semitendonosus contract, bending the knee and internally rotating the tibia in marichyasana I. This internal rotation manifests as external rotation of the hip, accentuating the twist of the trunk.



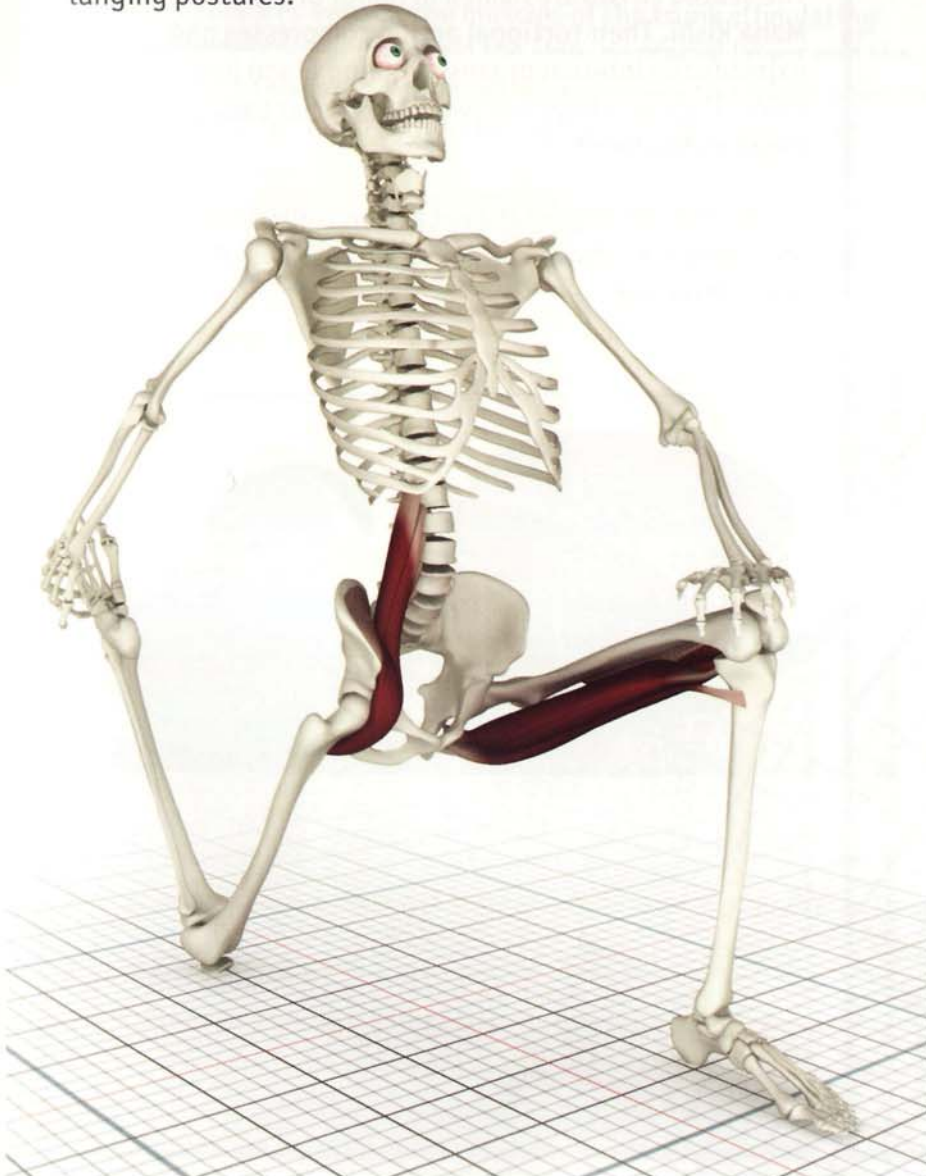Awakening

The semimembranosus and semitendonosus stretch and awaken in supta padangusthasana B.



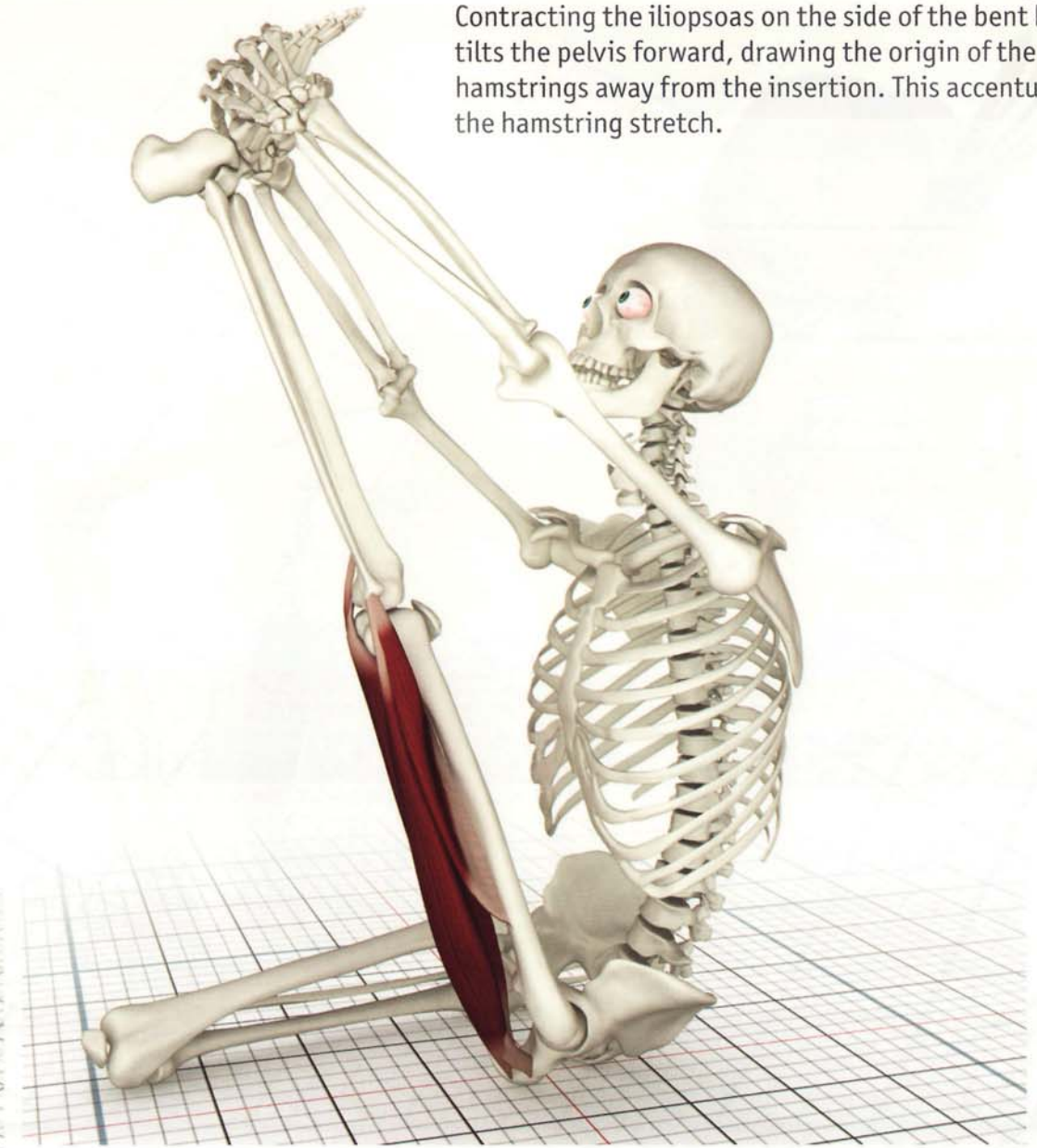
Contracted

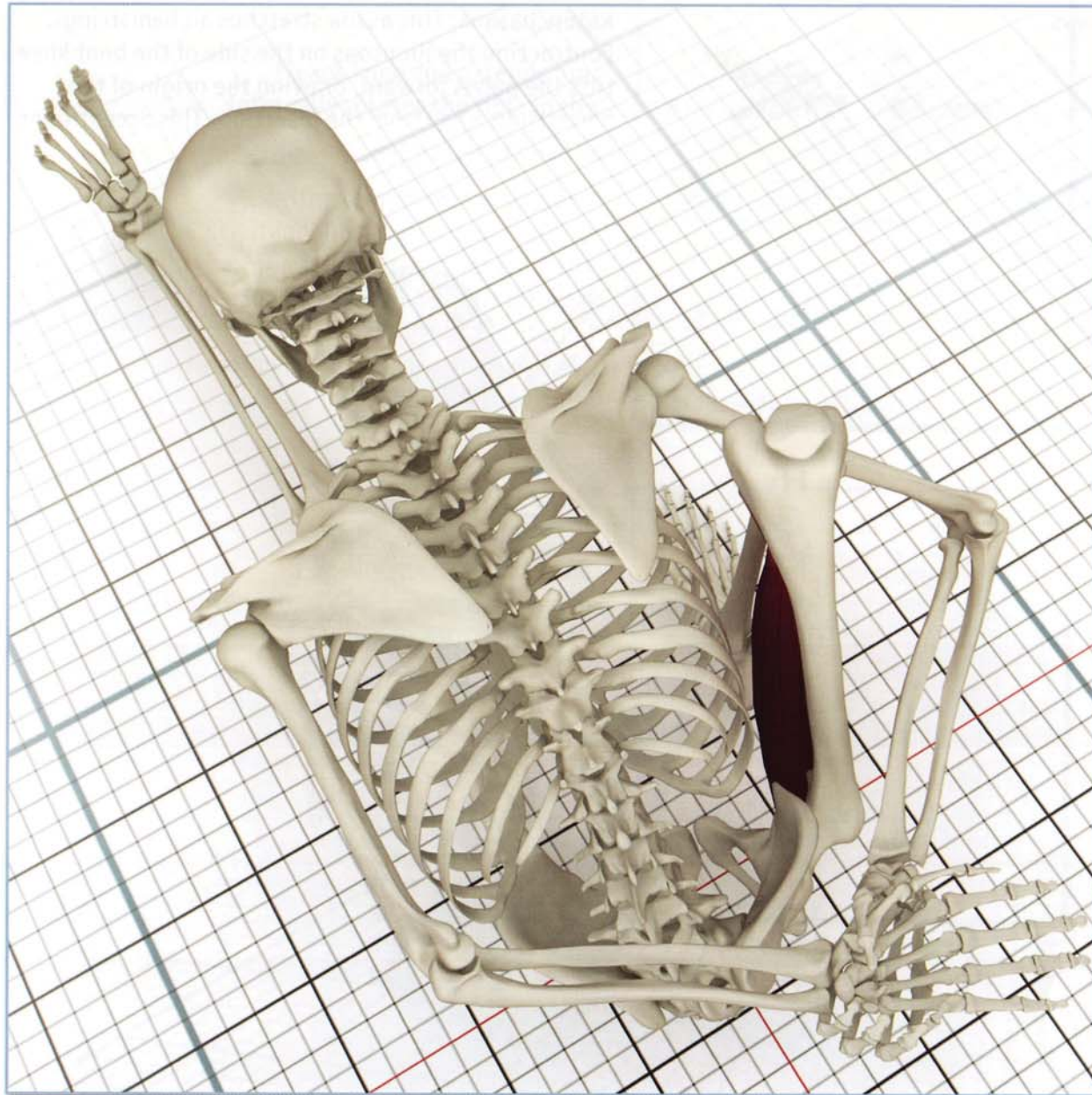
Iliopsoas lunge: Contracting the hamstrings of the front leg draws the body forward, accentuating the stretch of the iliopsoas in lunging postures.



Stretched

Krounchasana: This asana stretches all hamstrings. Contracting the iliopsoas on the side of the bent knee tilts the pelvis forward, drawing the origin of the hamstrings away from the insertion. This accentuates the hamstring stretch.






Marichyasana I

The seated twists are named in honor of the great sage Maha Rishi. Their torsional action compresses and expands the internal organs, flushing blood into the veins. The veins have one-way valves that then direct this blood to the heart.



All muscles having rotational action contribute to twists including the rotator cuff, external rotators of the hip and the hamstrings.



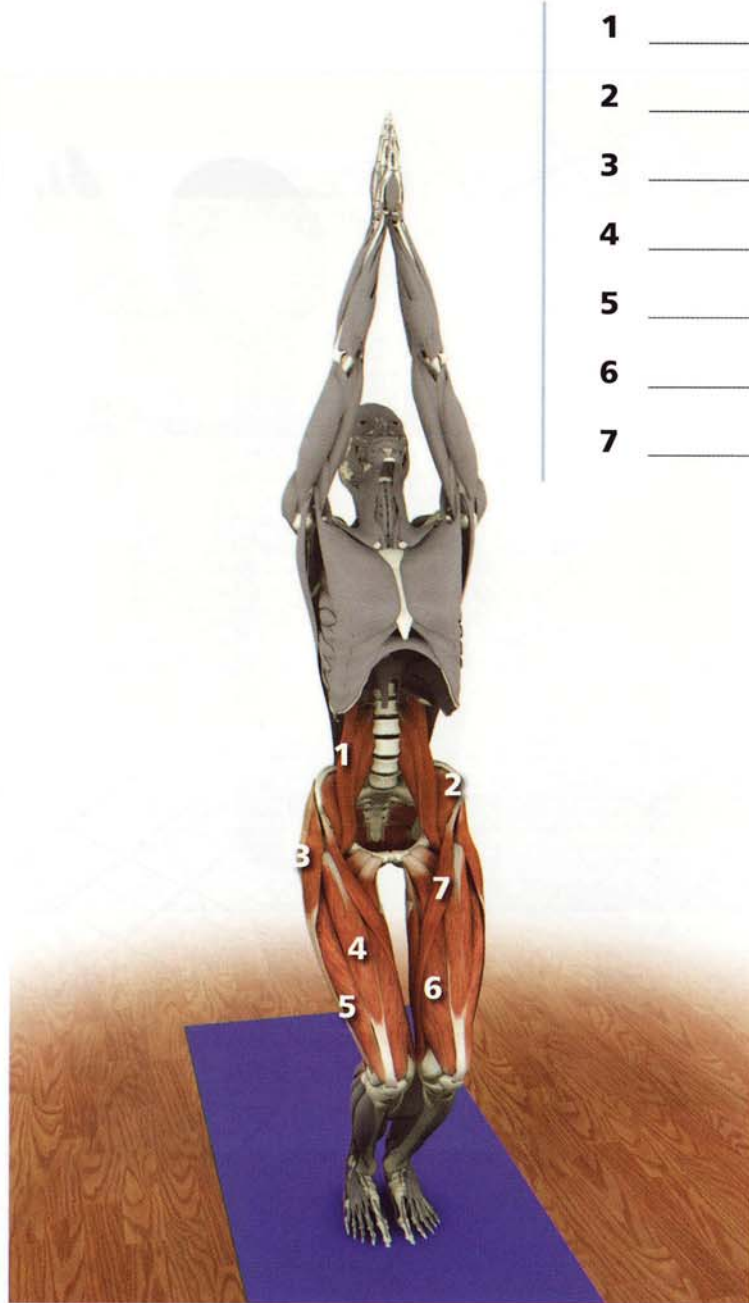Marichyasana III

Twisting postures awaken the muscles of the trunk stimulating sensory nerve conduction from the skin, myofascial layers and the muscles themselves. This illuminates and drives the subtle energies of the chakras upward through the sushumna nadi (spinal cord).


The semimembranosus and semitendinosus contract in marichyasana I. The biceps femoris contracts in marichyasana III.



Test your anatomy*



- 1 _____
- 2 _____
- 3 _____
- 4 _____
- 5 _____
- 6 _____
- 7 _____



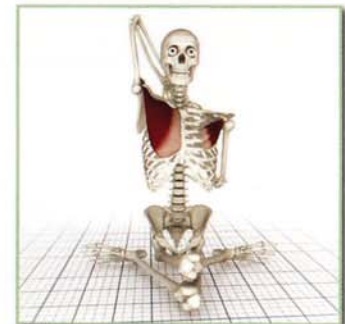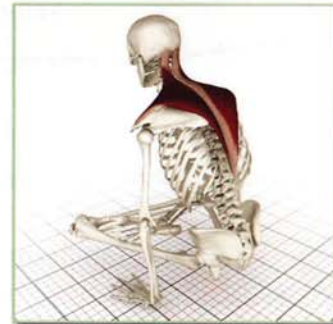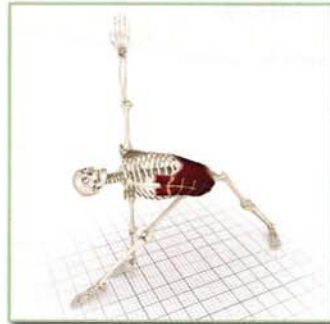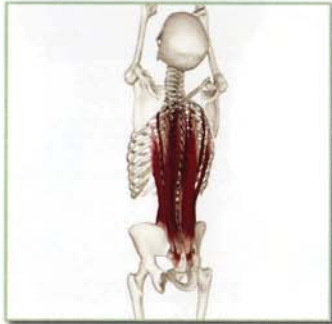- 1 _____
- 2 _____
- 3 _____
- 4 _____
- 5 _____

*Please see www.bandhayoga.com for answers...

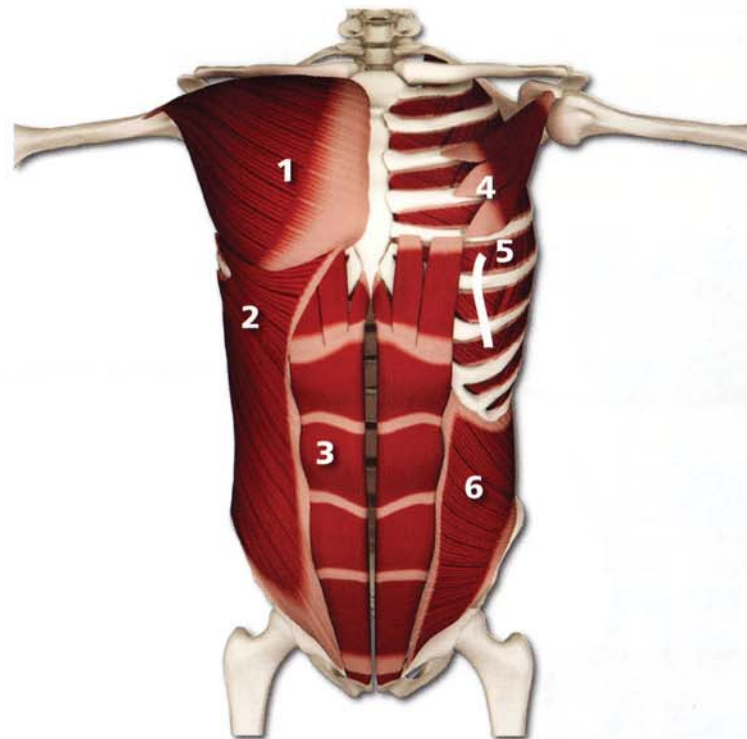
Part Two

The Trunk

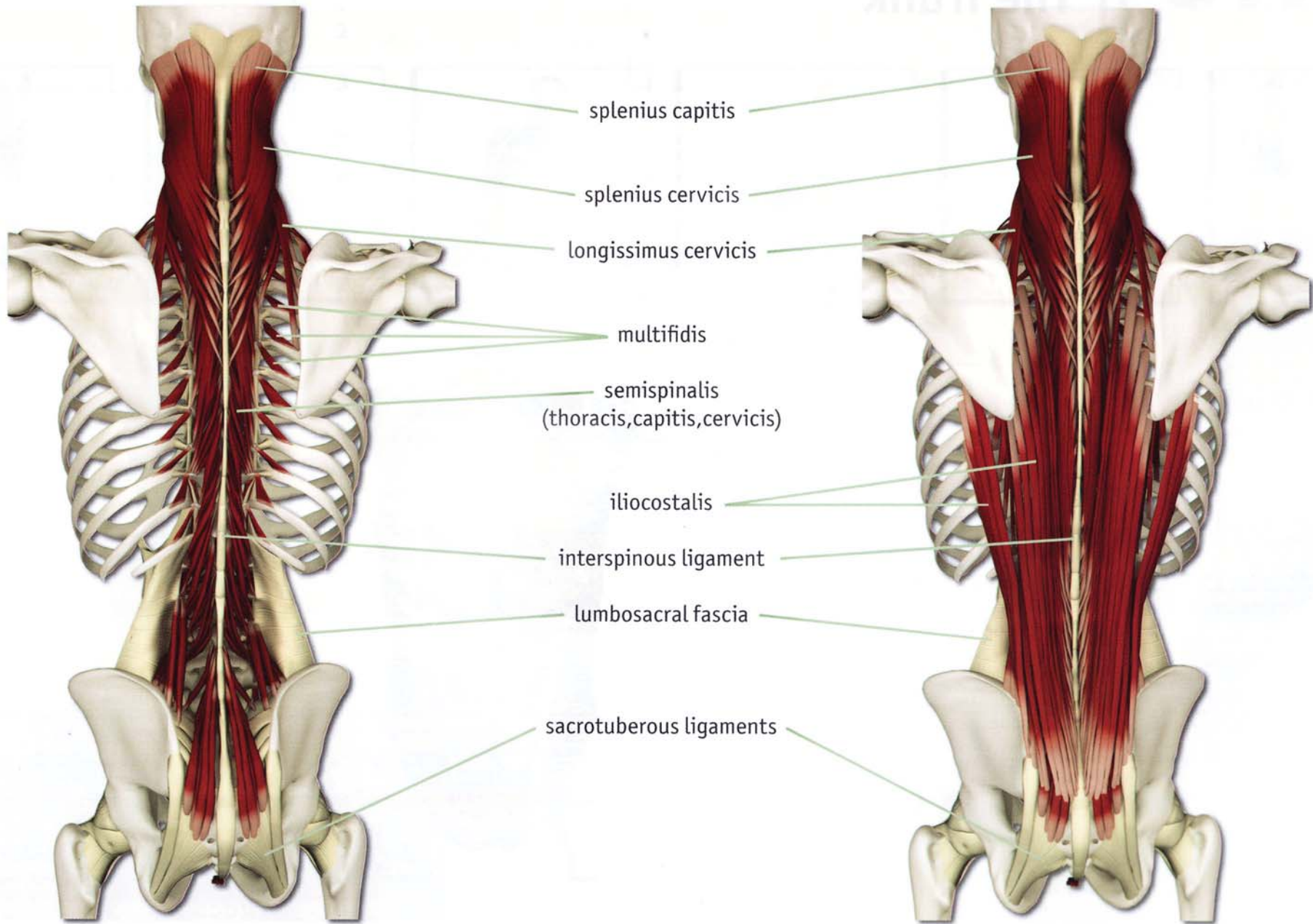
The Trunk

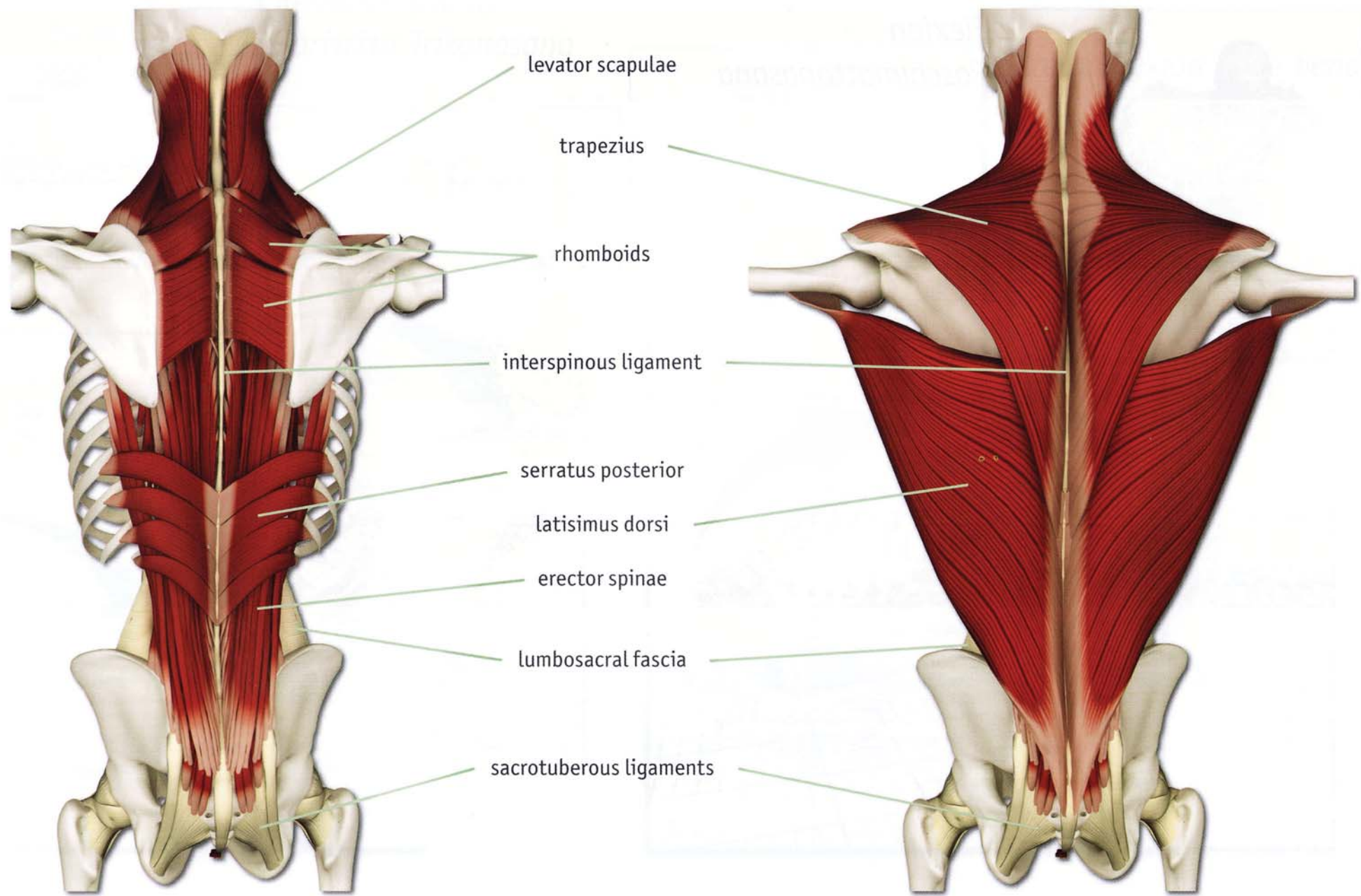


- 1 pectoralis major
- 2 external oblique
- 3 rectus abdominus
- 4 pectoralis minor
- 5 intercostals
- 6 internal oblique



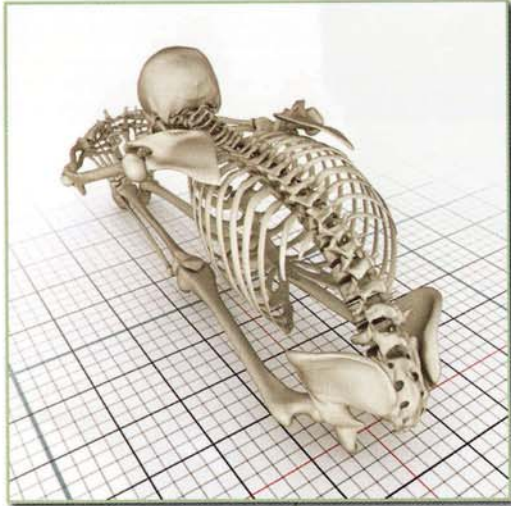Left to right illustrates the muscles of the back from deep to superficial



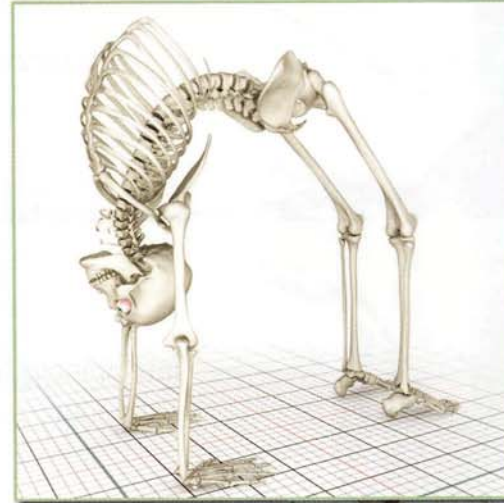


Movement: Trunk

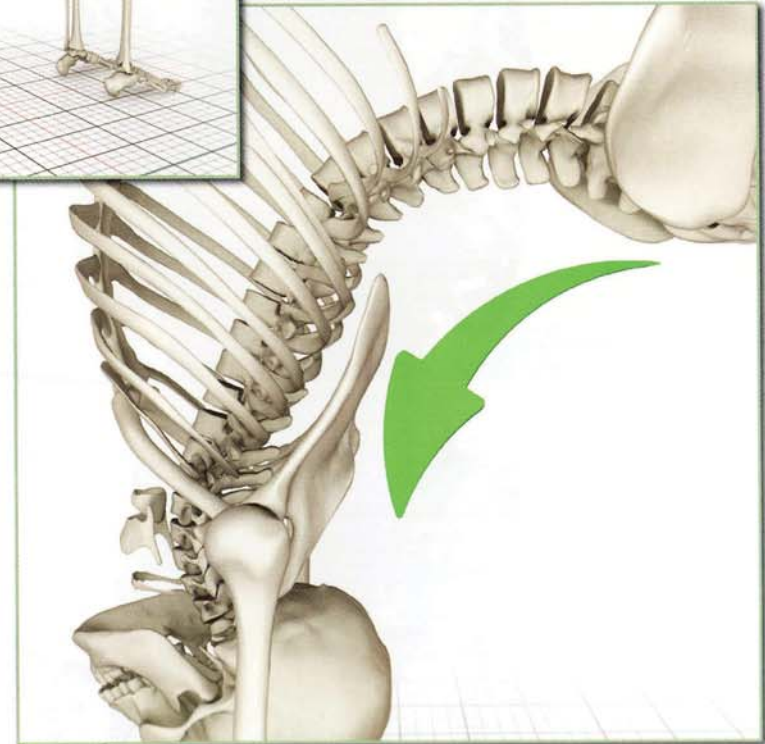
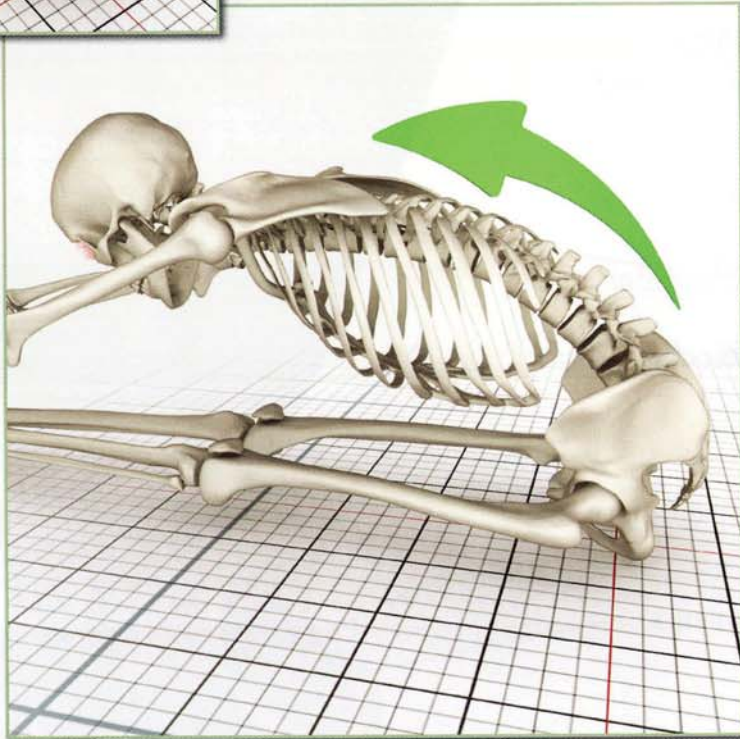
Left to right illustrates the muscles of the back from deep to superficial

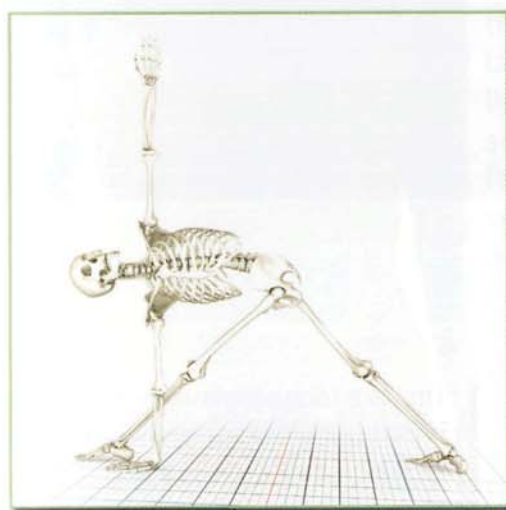


Flexion
Paschimottonasana

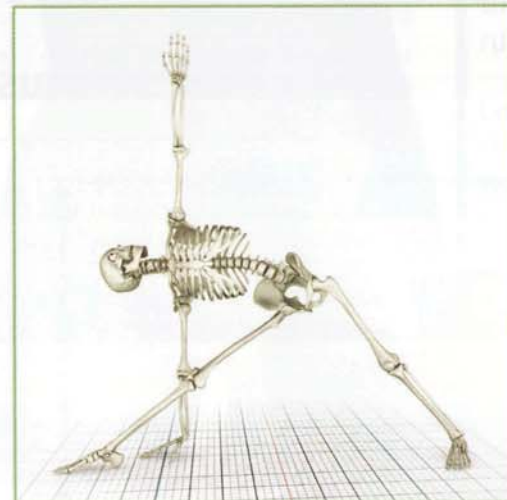
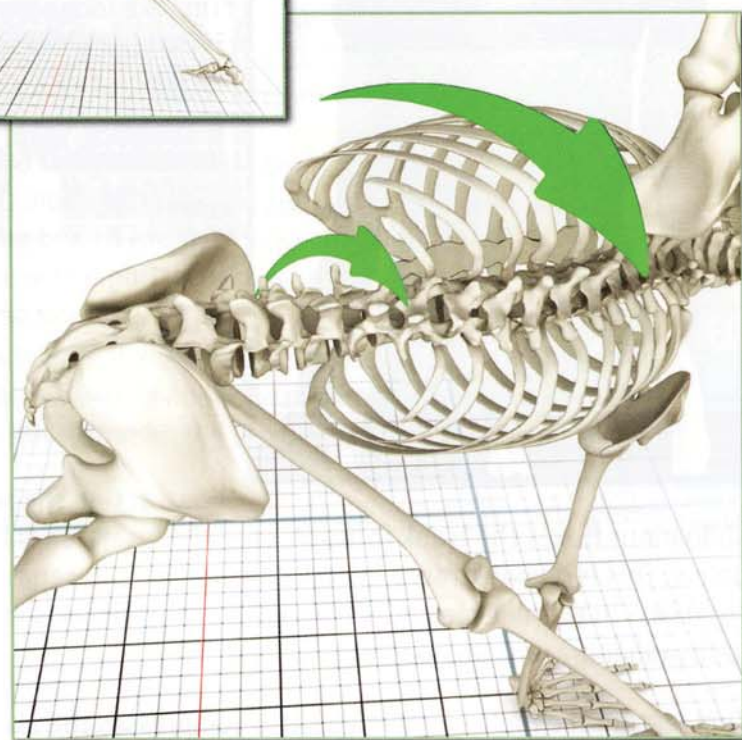


Extension
Urdhavadhanurasana

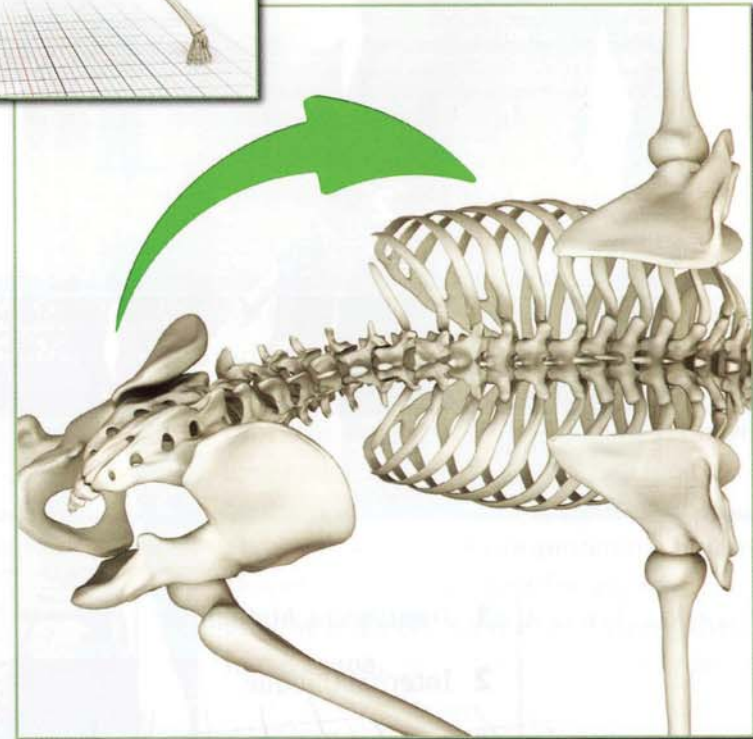




Rotation (twist)
Parivrtta Trikonasana



Lateral Flexion (side bend)
Utthita Trikonasana



Chapter 9

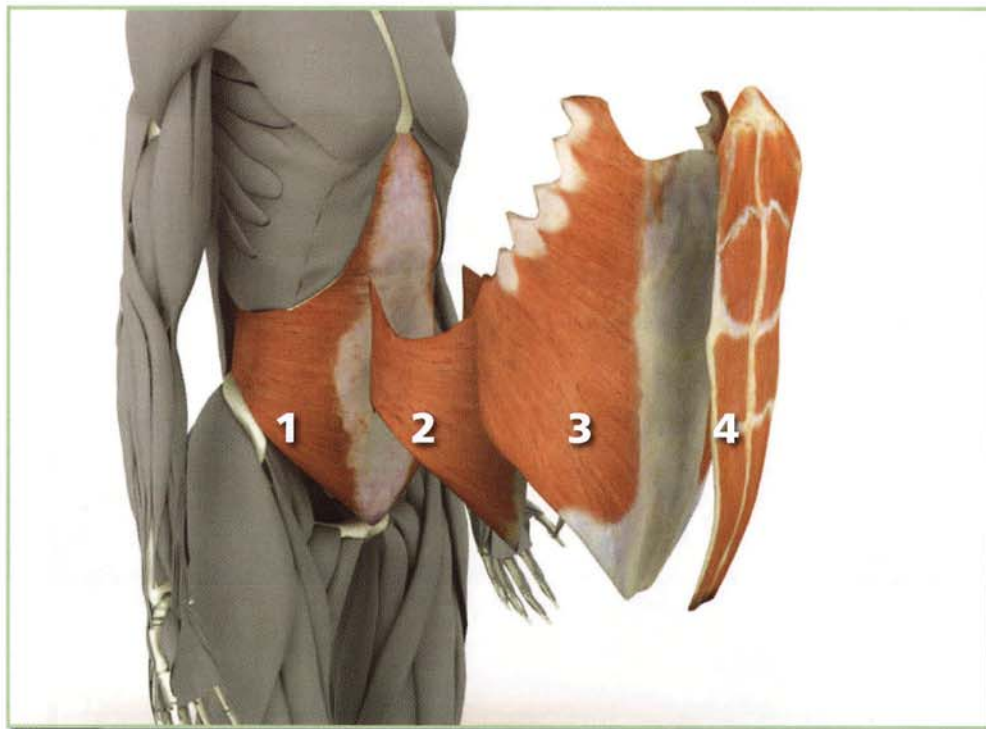
Abdominals

Rectus abdominus (REK-tus ab-DOM-i-nus)

Internal oblique (o-BLEEK)

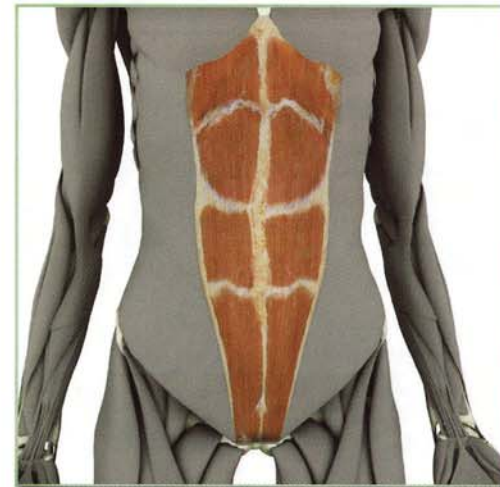External oblique (o-BLEEK)

Transversus abdominus



- 1 Transversus Abdominis
- 2 Internal Oblique
- 3 External Oblique
- 4 Rectus Abdominus

Rectus Abdominus



This is a long flat muscle that is divided into four bellies by horizontal fibrous bands, giving it a “washboard” appearance. It originates bilaterally from the pubic symphysis and pubic crest, inserting on the xyphoid process (at the bottom of the sternum) and, more laterally, the cartilage of the fifth, sixth and seventh ribs.

Contracting the rectus abdominus flexes the trunk forward, or, if the insertion is fixed, lifts the pelvis. This is demonstrated in utthanasana and tolasana respectively. Tightness in this muscle limits the depth of backbends such as urdhvadhanurasana and purvottonasana.

Contracting the rectus abdominus also compresses the abdominal contents, producing an “air bag” effect, which is thought to prevent hyperextension of the lumbar spine, protecting it when extended (as in backbends).

External Oblique

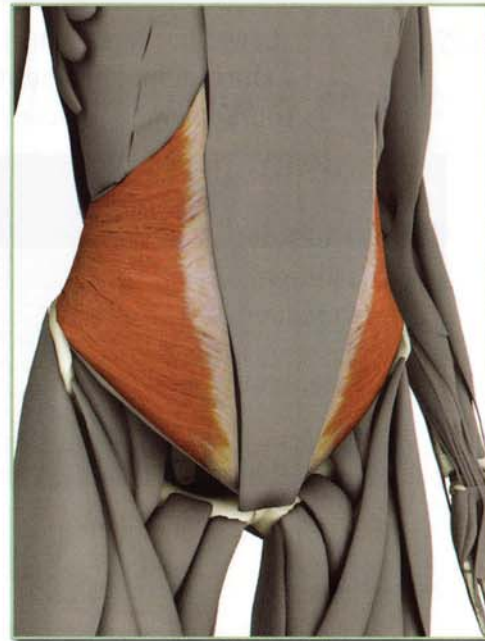

This is also a sheet-like muscle with fibers running opposite to the internal oblique. It is the larger of the two obliques and lies superficial. Its anterior fibers are more superior, originating from the front of the ribs, crossing diagonally forward and downward and inserting on the linea alba. Its lateral fibers are more posterior, originating from the back of the ribs, crossing downward and forward and inserting on the structures at the front of the pelvis.

Contraction of the external oblique draws the same side shoulder forward. This action combines with contraction of the

contralateral (other side) internal oblique, accentuating twisting poses. Tightness in this muscle limits these postures. Contraction assists in compressing the abdominal contents and contributes to the “air bag” effect, protecting the lumbar spine.

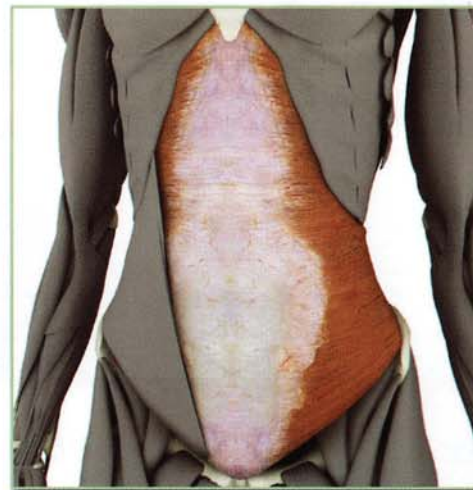
Internal Oblique



This is a thin sheet-like muscle located on the side of the trunk. Its fibers cross diagonally upward and forward from the iliac crest, inserting on the lower ribs and the linea alba (a band of fibrous tissue running down the front of the abdomen).

Contraction of the internal oblique draws the opposite shoulder forward and bends the trunk laterally. This action accentuates twisting postures such as parivrtta trikonasana. Contracting the internal oblique also contributes to the “air bag” effect described for the rectus abdominus.

Transversus Abdominus

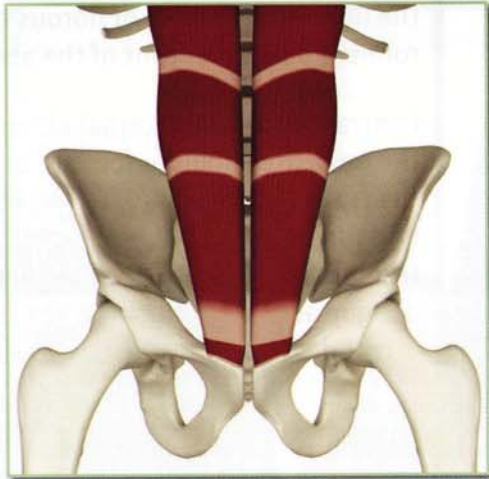


The transversus abdominus is the deepest of the abdominal muscles. Its fibers run horizontally, originating from the iliac crest, the inguinal ligament and the thoracolumbar fascia and inserting on the lower costal cartilages. Contracting the transversus abdominus compresses the abdomen and tones the abdominal organs. This muscle is important for udyana bandha and nali. Awaken and strengthen it in navasana.

Abdominals

Origin-Rectus Abdominus

Symphysis pubis and pubic crest.

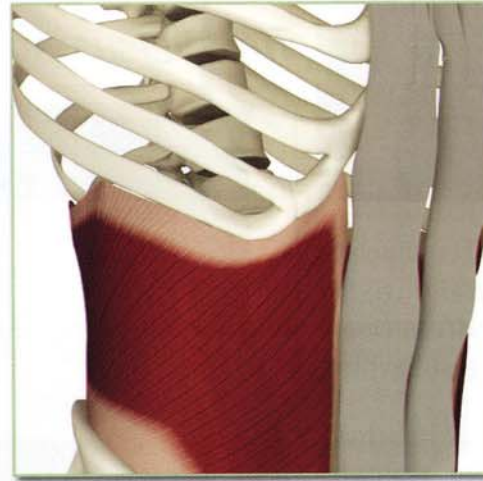
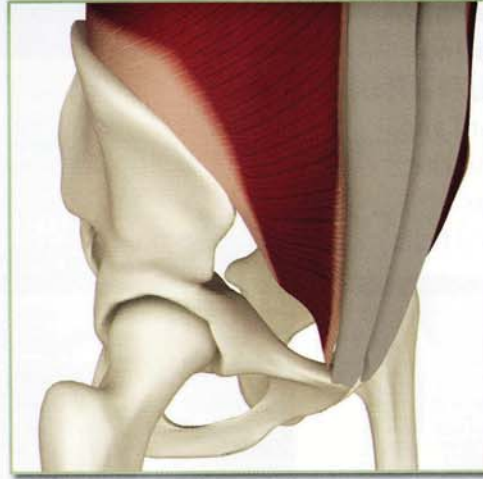

Insertion-Rectus Abdominus

Zyphoid process, costal cartilages 5, 6 and 7.

Origin-Internal Oblique

Lower borders of the lateral 1/3 of the inguinal ligament, iliac crest, thoracolumbar fascia and linea alba.

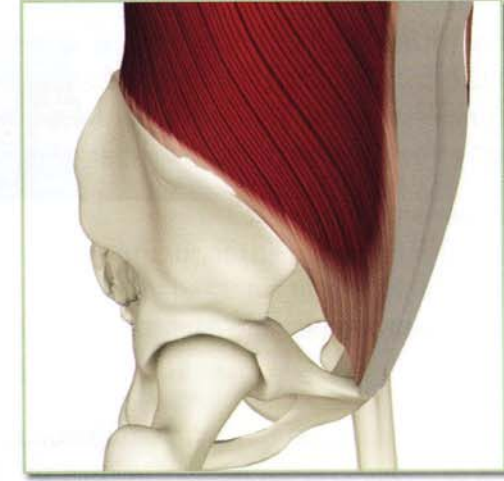
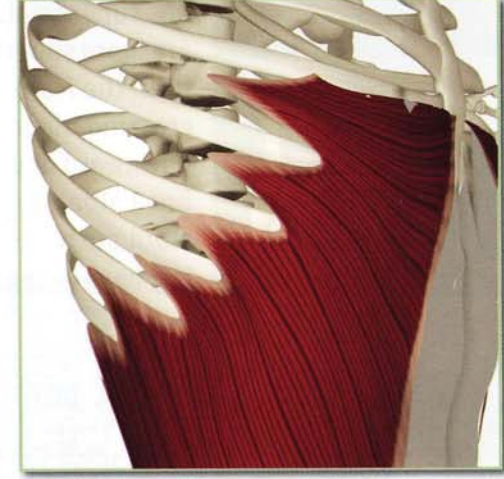
Insertion-Internal Oblique

Linea alba and ribs 9 through 12.

Origin-External Oblique

Ribs 5 through 12 and lower section of latissimus dorsi.

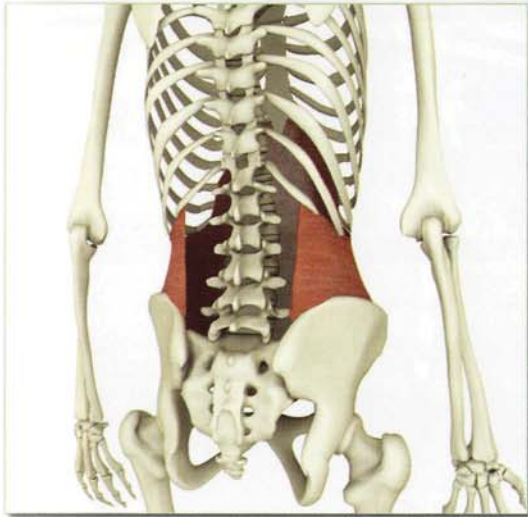

Insertion-External Oblique

Linea alba, inguinal ligament and anterior half of iliac crest.

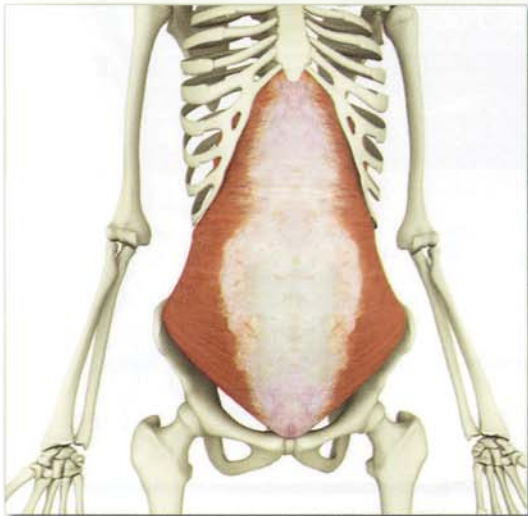
Rectus Abdominus

Transversus Abdominus Origin Insertion



Origin: iliac crest,
inguinal ligament and
thoracolumbar fascia;

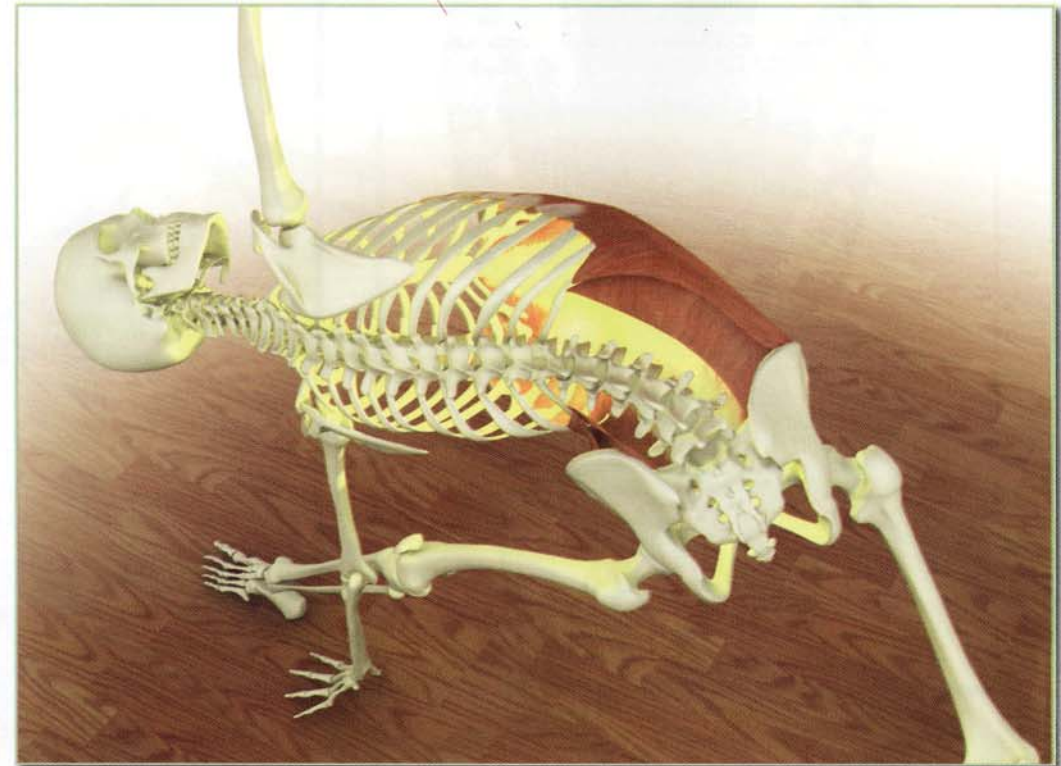
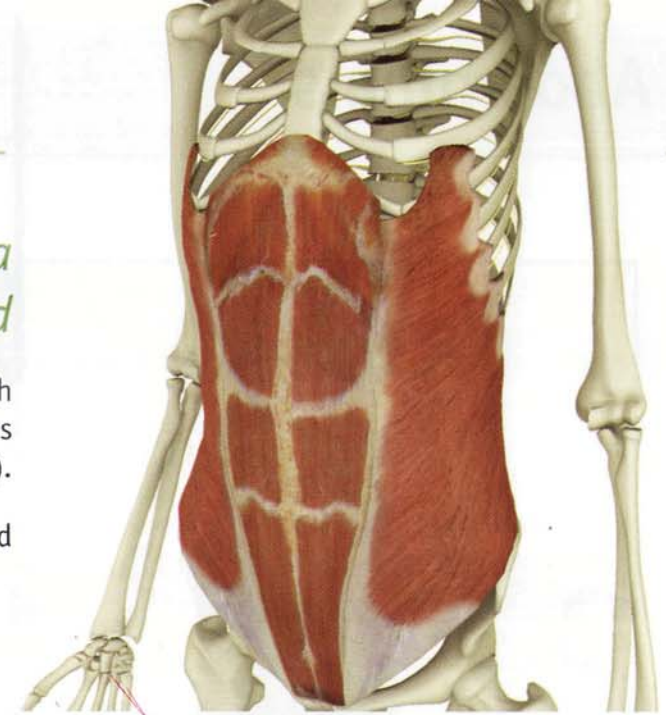
Insertion: lower costal
cartilages



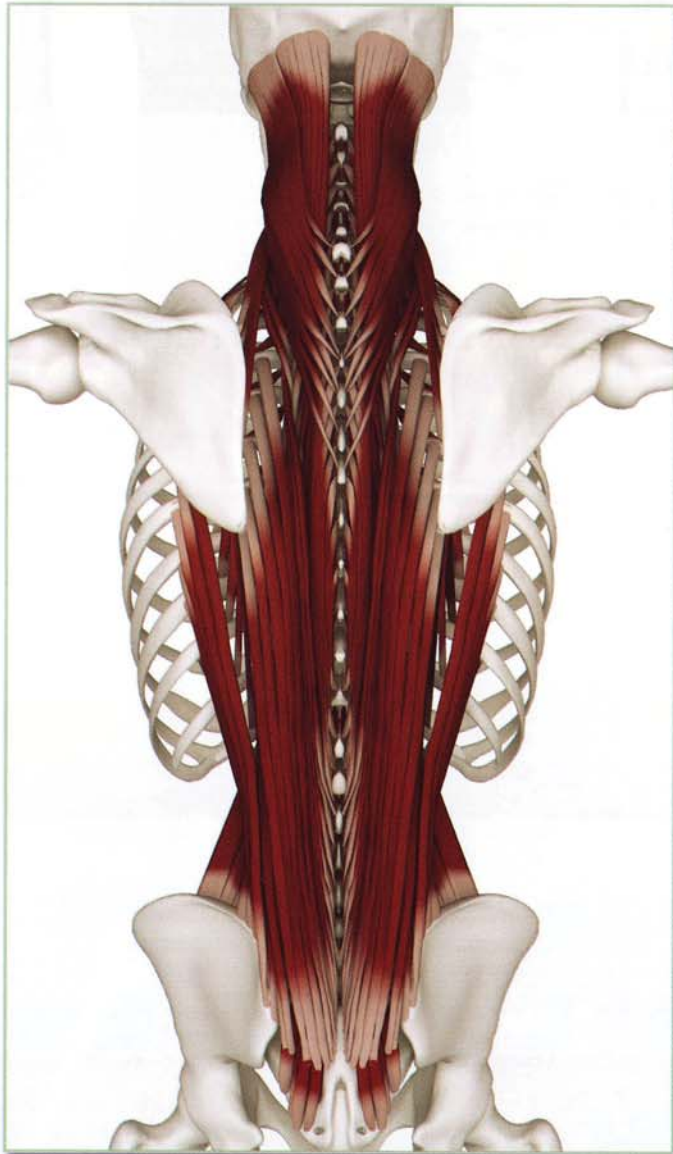Innervation & chakra illuminated

Intercostal nerves (thoracic nerves 7 through 12), iliohypogastric and ilioinguinal nerves (thoracic nerve 12 and lumbar nerve 1).

Chakra illuminated: Third



Abdominals



Abdominals Antagonists

Erector spinae and quadratus lumborum.

Obliques Antagonists

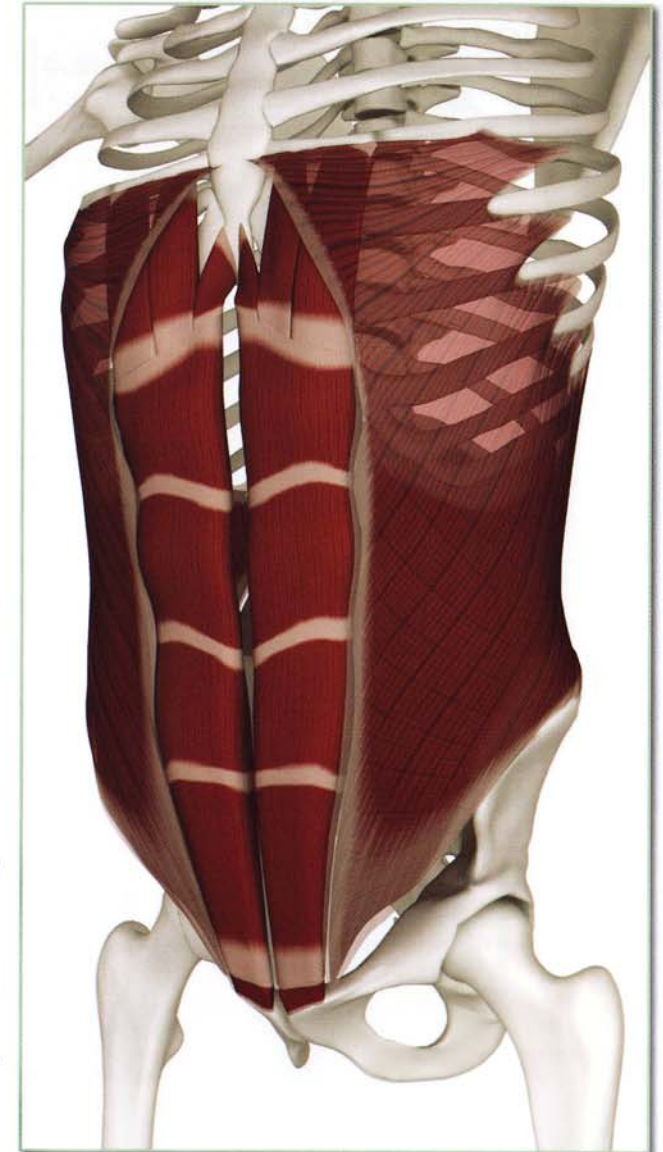Same side muscles are rotational antagonists.

Abdominals Synergists

Each other (for abdominal compression).

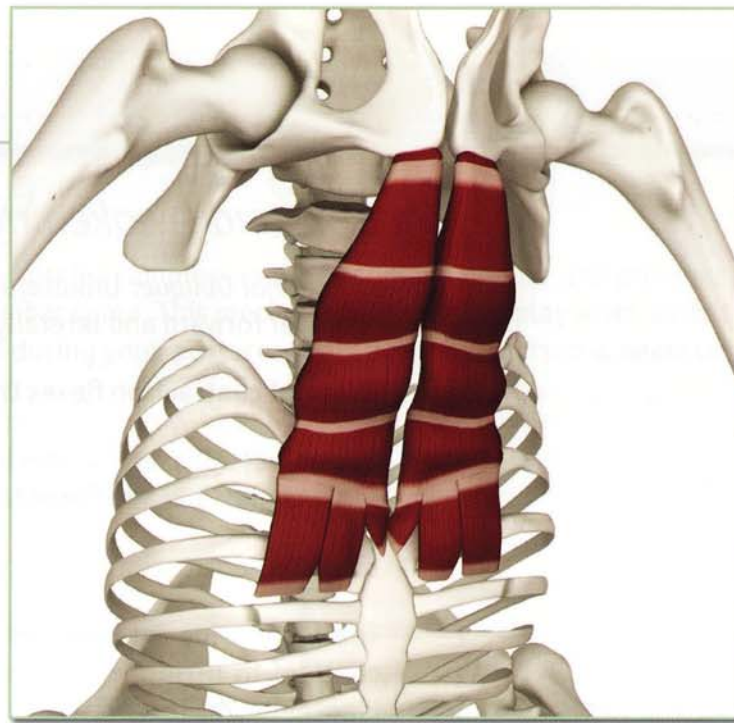
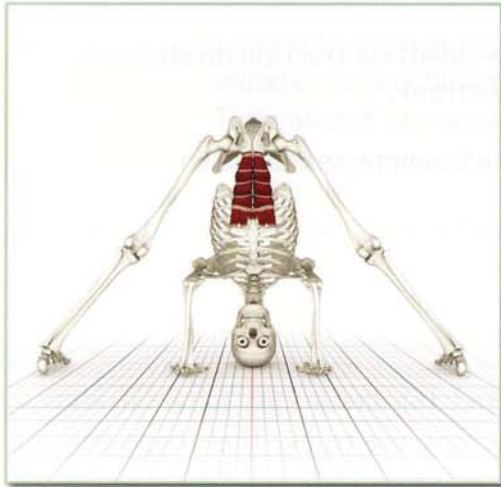
Obliques Synergists

Opposite side muscles are rotational synergists. They can assist each other, turning the body.



Rectus Abdominus

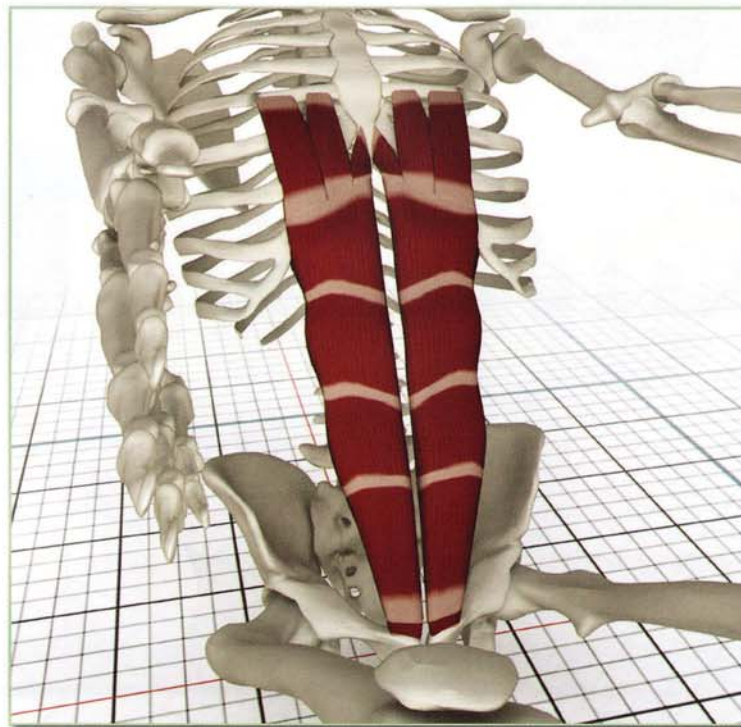
Obliquus



Action

Flexes trunk and compresses abdomen.

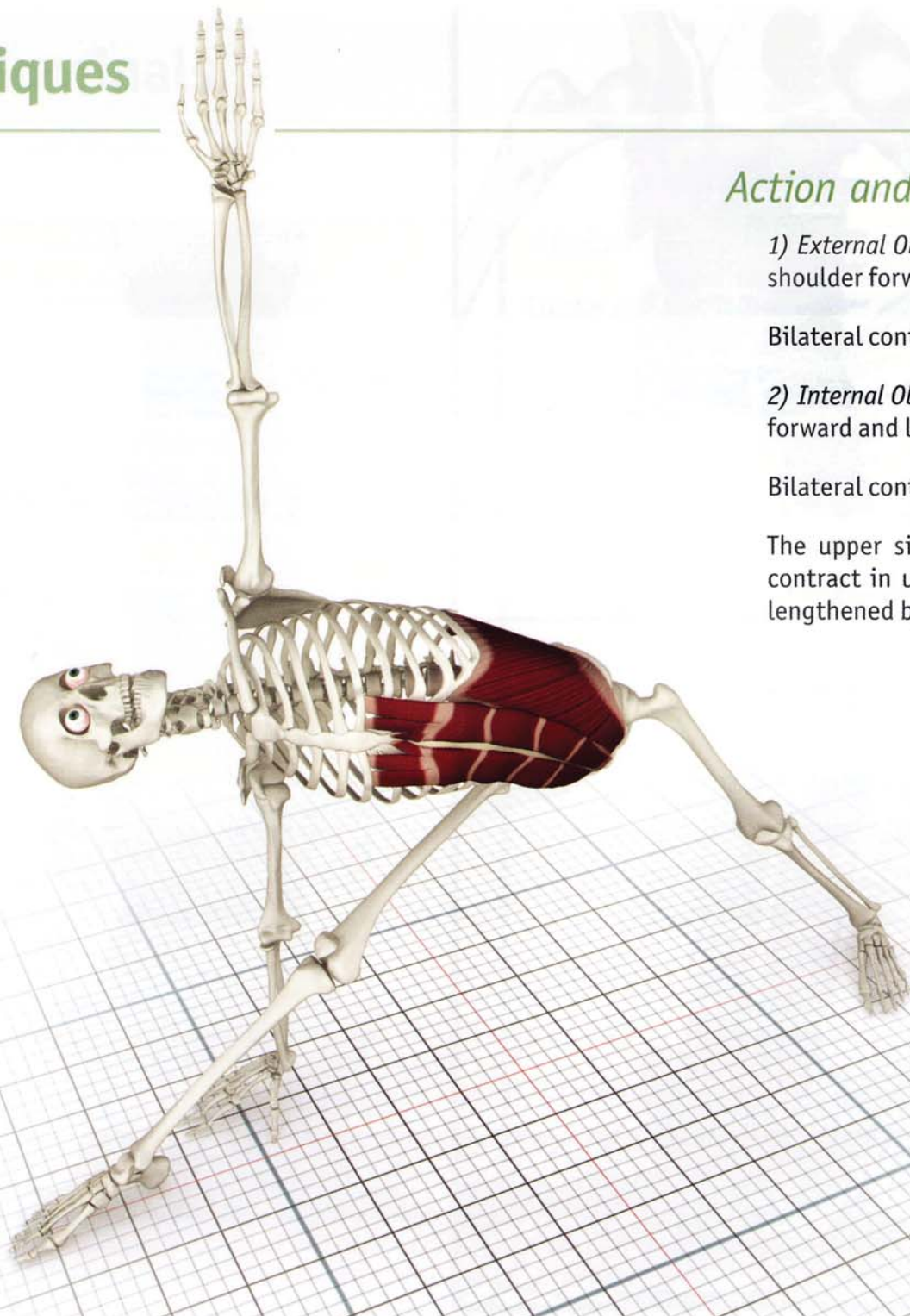
Contracting the rectus abdominus draws the trunk forward and deepens prasarita padottanasana. Contracting the iliopsoas and quadriceps accentuates this action.



Awakening

The rectus abdominus awakens in navasana.

Obliques



Action and Awakening

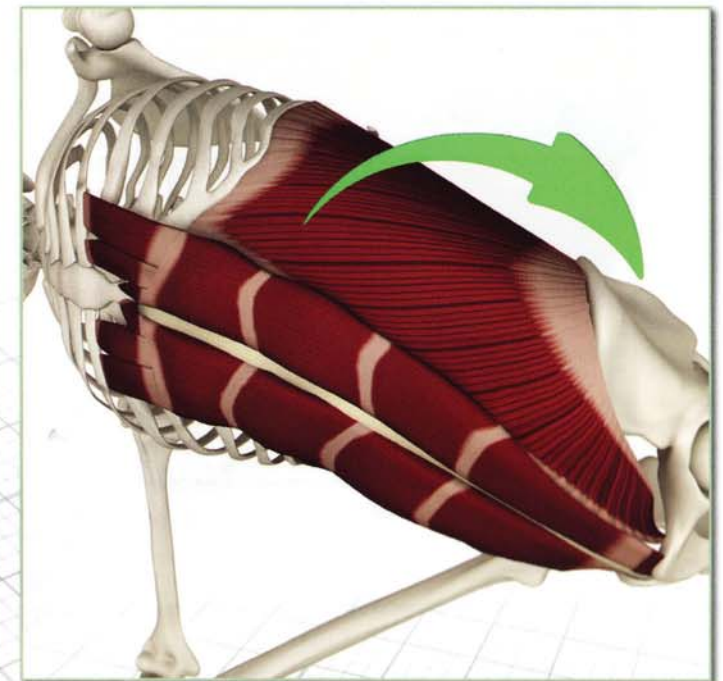
1) *External Oblique*: Unilateral (one-sided) contraction rotates same side shoulder forward and laterally flexes trunk.

Bilateral contraction flexes trunk and compresses abdomen.

2) *Internal Oblique*: Unilateral contraction rotates opposite side shoulder forward and laterally flexes trunk.

Bilateral contraction flexes trunk and compresses abdomen.

The upper side internal oblique and the lower side external oblique contract in *utthita trikonasana* turning the trunk. Their opposites are lengthened by this action.

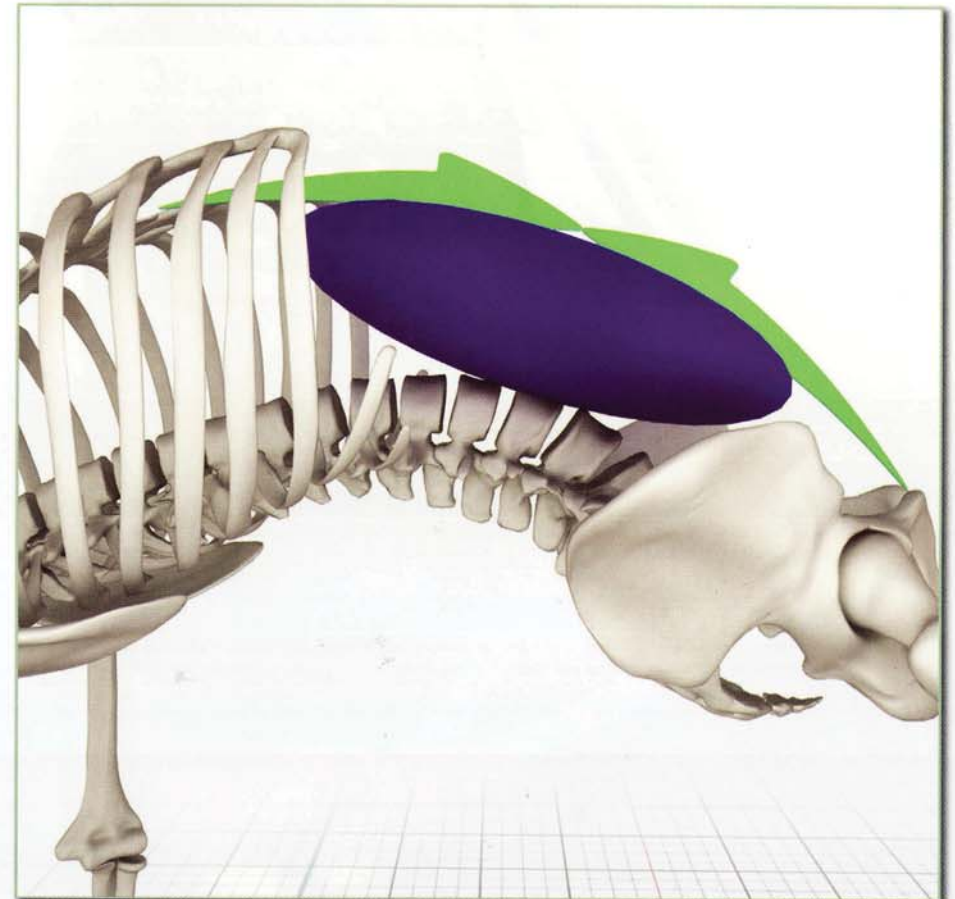
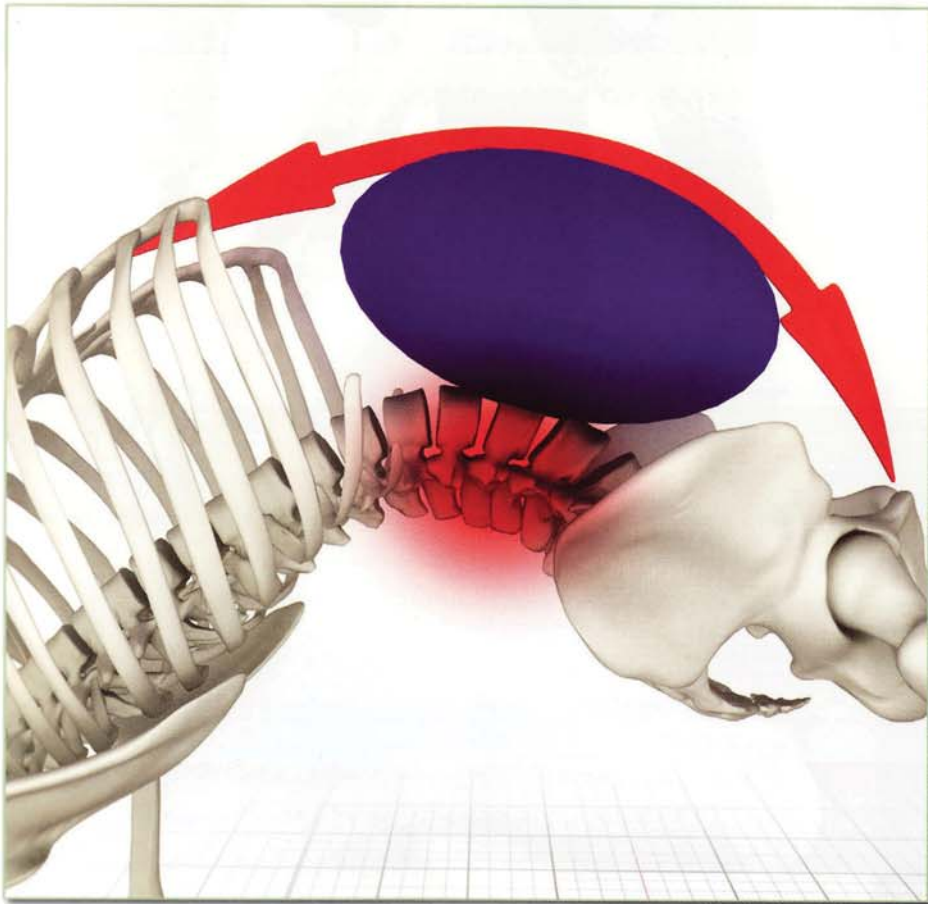


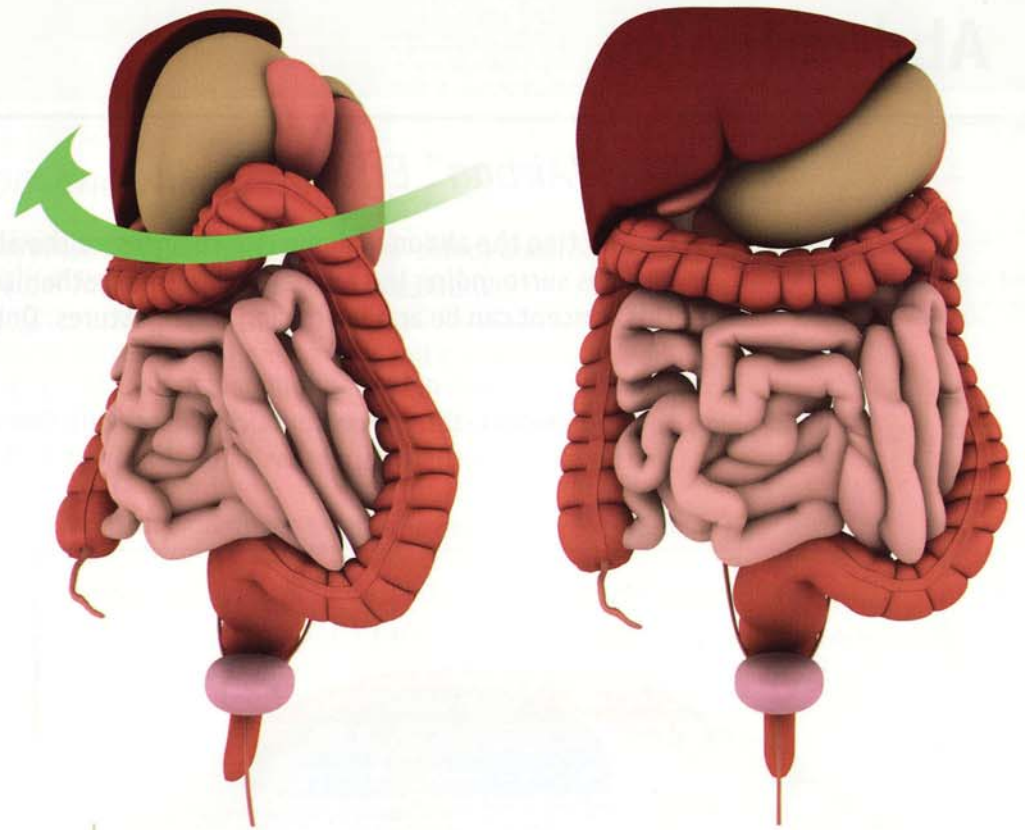
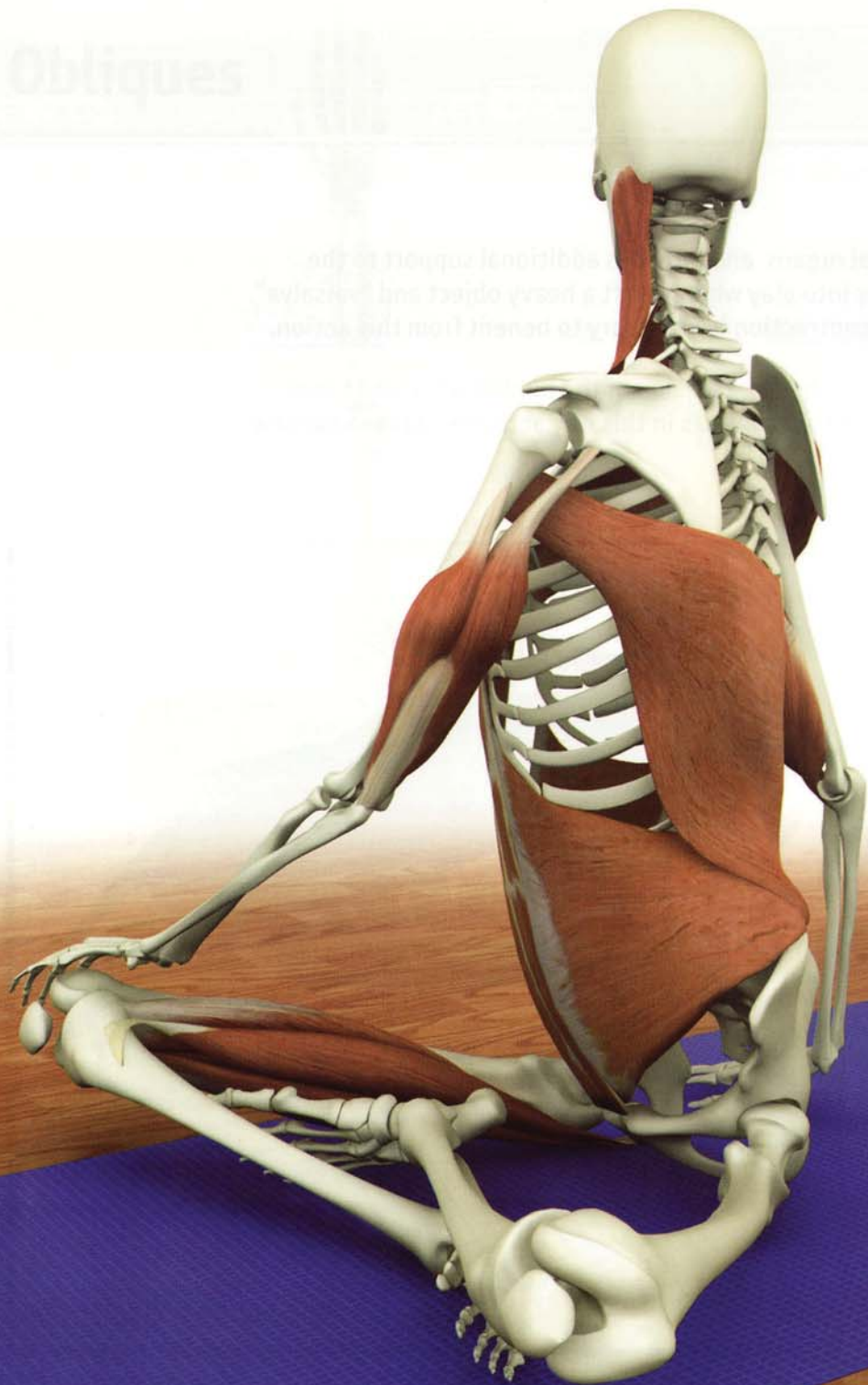Abdominals

The “Airbag” Effect

Contracting the abdominal muscles compresses the abdominal organs and provides additional support to the muscles surrounding the lumbar spine. This mechanism comes into play when we lift a heavy object and “valsalva”. This concept can be applied during yoga postures. Only light contraction is necessary to benefit from this action.

Light contraction of the abdominals in back bends also opposes hyperextension of the lumbar spine and tones the abdominals (through eccentric contraction). Contracting the abdominals in this way activates udyana bandha (in the region of the solar plexus), illuminating the third chakra.





Twisting and Detoxification

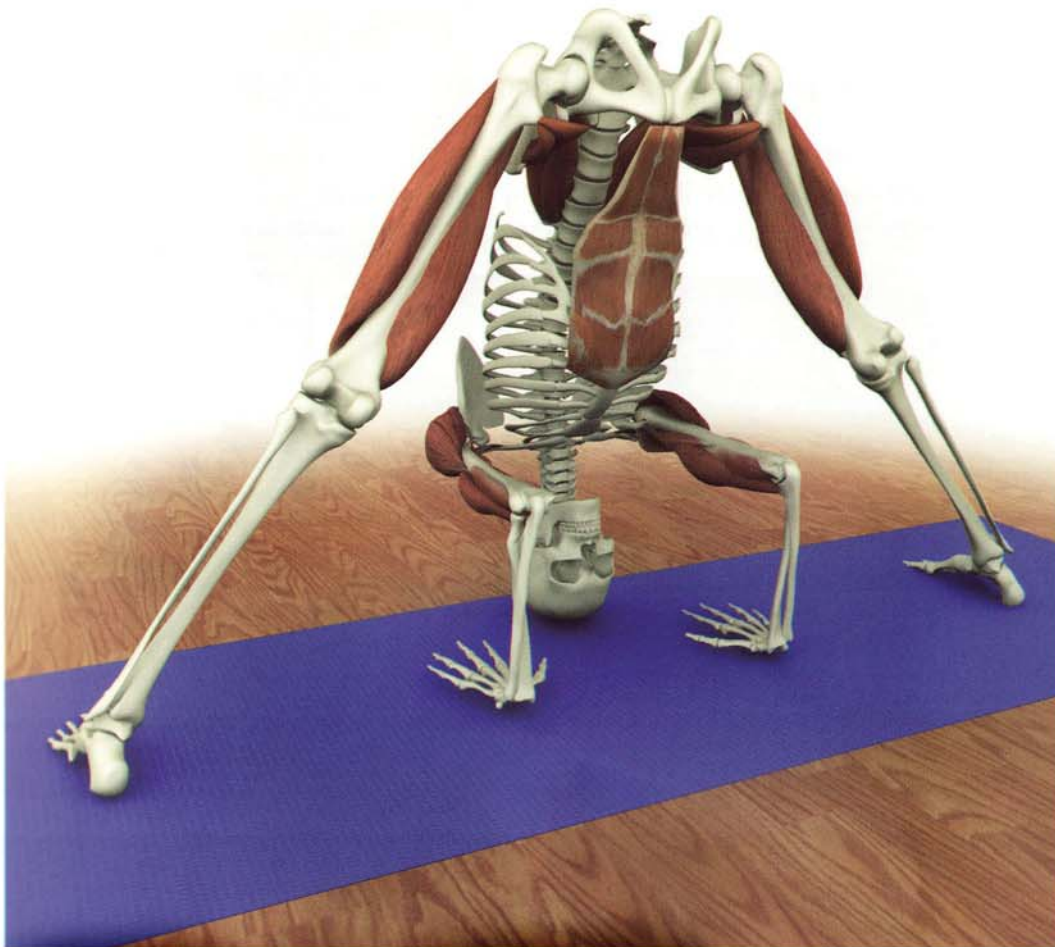Twisting postures create a “wringing” effect on the abdominal organs. This helps to flush the liver and other organs, directing blood and lymphatic fluid into the larger vessels of the cardiovascular system, eliminating toxins.

The abdominal muscles are the core prime movers in the twisting postures. Combine them with other muscular synergists of the twist. For example, in twisting siddhasana, the sternocleidomastoid, latissimus dorsi and triceps of one side assist the biceps and hamstrings of the other side to accentuate the twist.

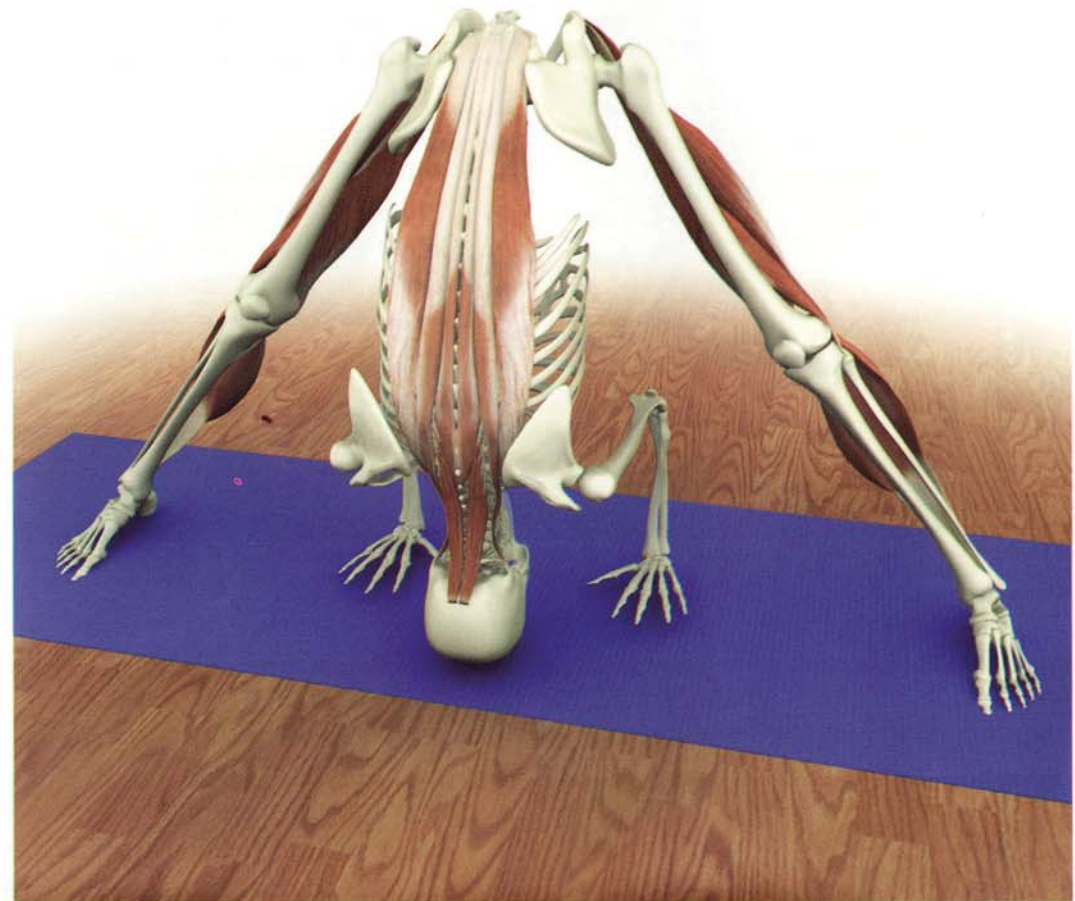
Synergy

Combine the actions of various muscles to create synergy in your posture. Contract the posture's synergists to lengthen the antagonists.

These illustrations demonstrate that contracting the rectus abdominus, iliopsoas, quadriceps, deltoids and biceps in prasarita padottanasana stretch the erector spinae, hamstring and gastrocnemius muscles.



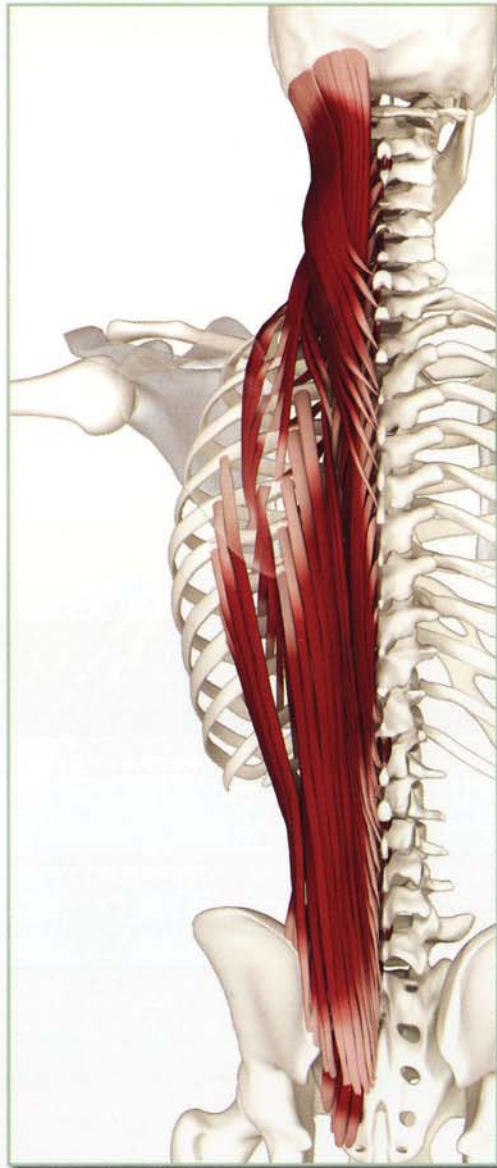
prasarita padotanasana - synergists



prasarita padotanasana - antagonists

Chapter 10

Back Muscles



Erector Spinae (EE-rec-tor SPEE-neh)

This group has three sets of muscles running parallel to the vertebral column. The spinalis runs up the center of the back from one vertebral spinous process to the next. The longissimus are more lateral and run from one vertebral transverse process to the next. The iliocostalis are the most lateral and run from one rib to the next. Contracting these muscles straightens the spine, as in tadanasa. Contracting the laterally placed longissimus and iliocostalis produces lateral bending as in utthita trikonasana. Contracting one side or the other produces a rotational effect in twisting postures.

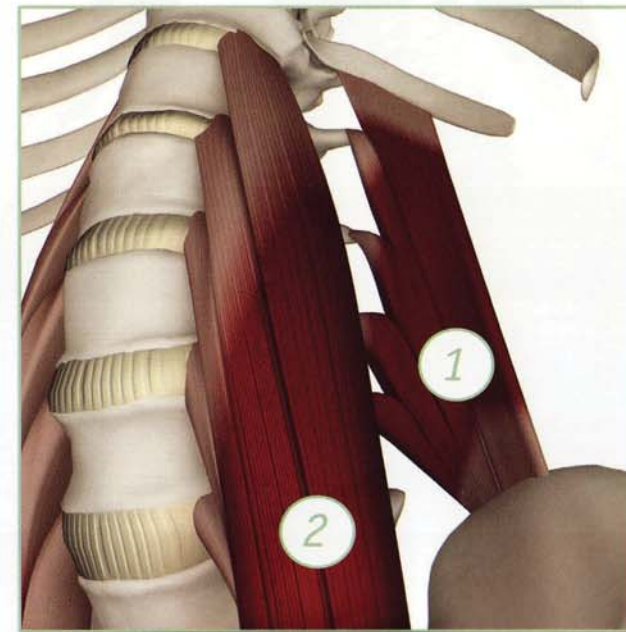
Forward bends such as utthanasana and kurmasana stretch these muscles. When they reach full length they tilt the pelvis forward by pulling on the back of the ilium. This tilt draws the ischial tuberosity upward and stretches the hamstrings. Backbends such as urdhvadhanurasana strengthen these muscles.

Quadratus Lumborum (quad-RA-tus lum-BOR-um)

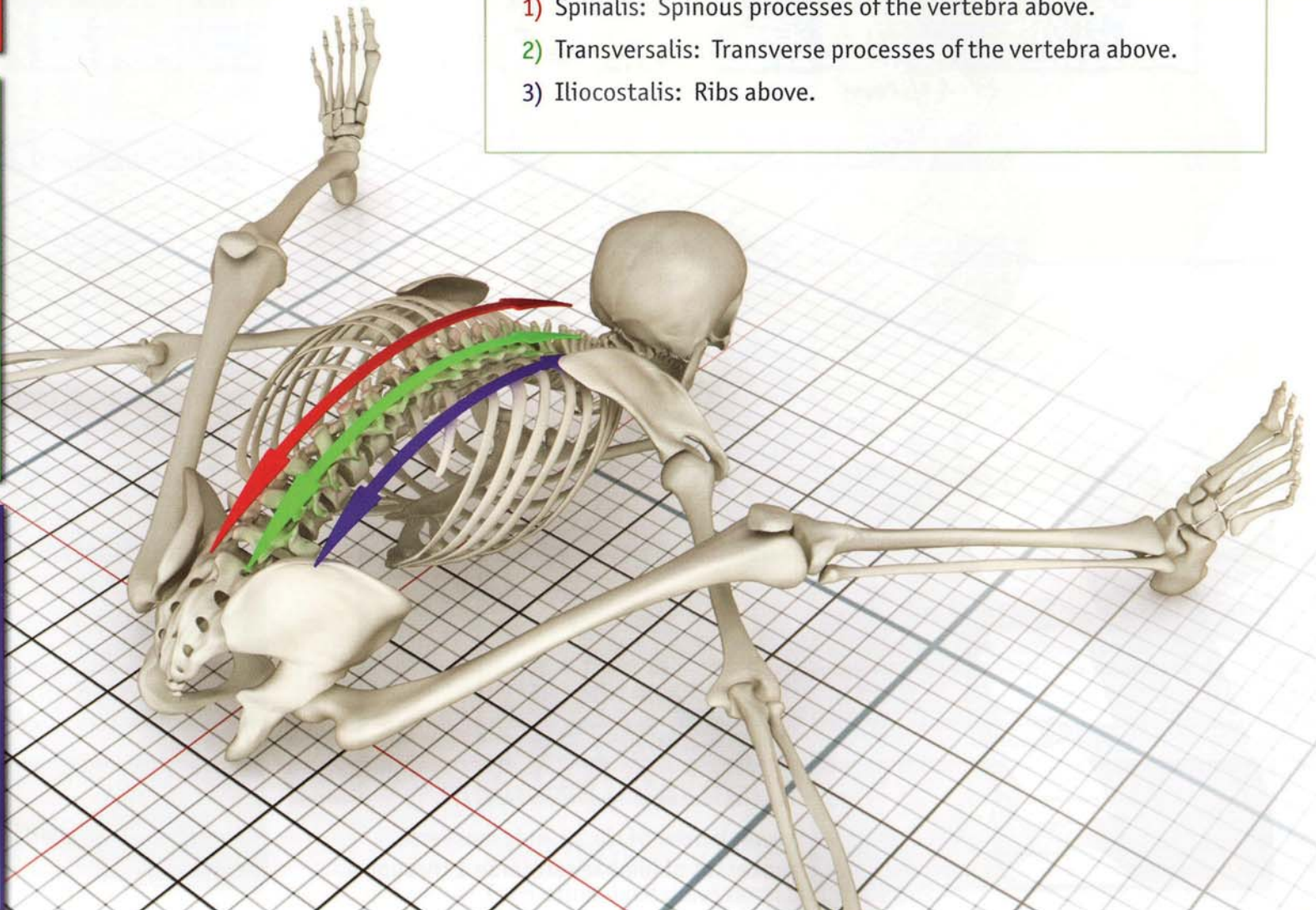
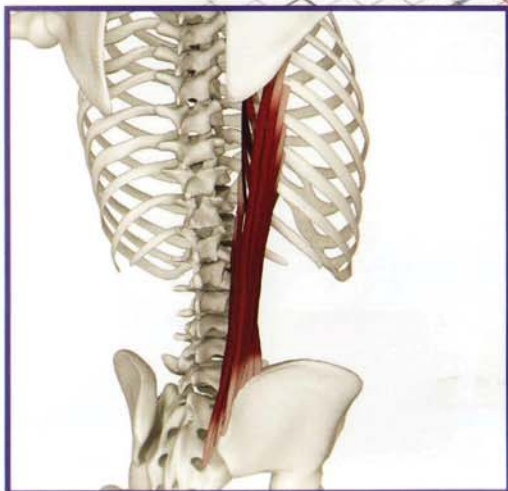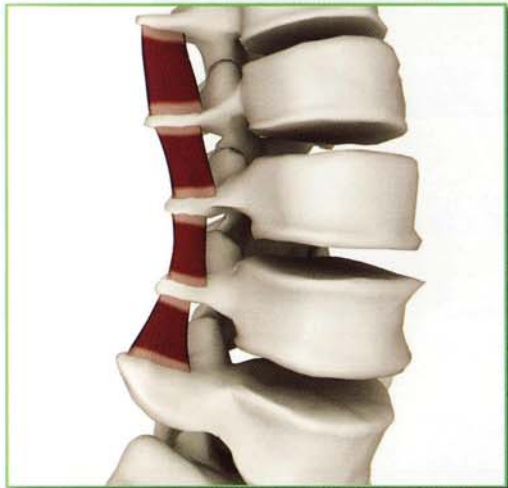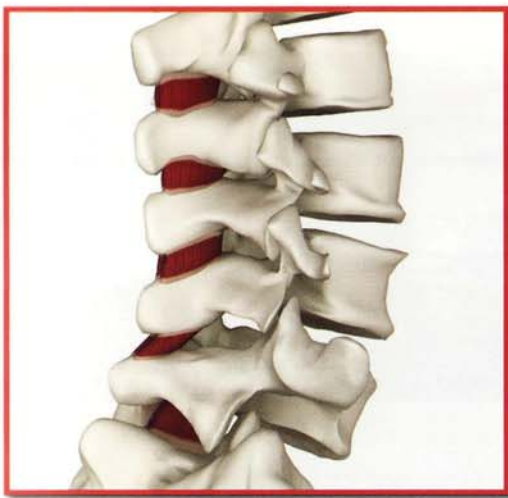Deep to the erector spinae lies the quadratus lumborum, a combination of five heads that form a square-shaped muscle. They have a common origin from the posterior iliac crest, dividing into four parts, inserting on the transverse processes of the lumbar vertebrae and the posterior section of rib twelve. Contracting the quadratus lumborum unilaterally flexes the trunk to the side in utthita trikonasana. Contracting both sides extends the lumbar spine in urdhvadhanurasana.

When the pelvis is fixed, contracting the quadratus lumborum draws the ribcage downward. This action can be used to deepen respiration.

The quadratus lumborum and psoas major wrap around the lumbar spine and stabilize it. Contracting the quadratus lumborum, psoas major and rectus abdominus protects the lumbar spine in backbends.



- 1) Quadratus Lumborum
- 2) Psoas major



Origin:

- 1) Spinalis: Spinous processes of the vertebrae.
- 2) Transversalis: Transverse processes of the vertebrae.
- 3) Iliocostalis: Sacrum and ribs.

Insertion:

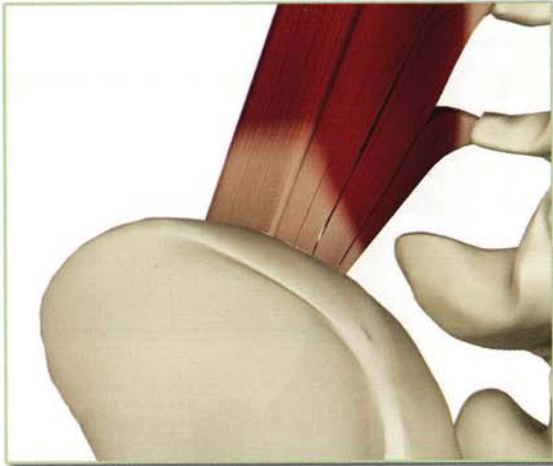
- 1) Spinalis: Spinous processes of the vertebra above.
- 2) Transversalis: Transverse processes of the vertebra above.
- 3) Iliocostalis: Ribs above.

Back Muscles

Innervation & chakra illuminated

Lower thoracic and upper lumbar nerves.

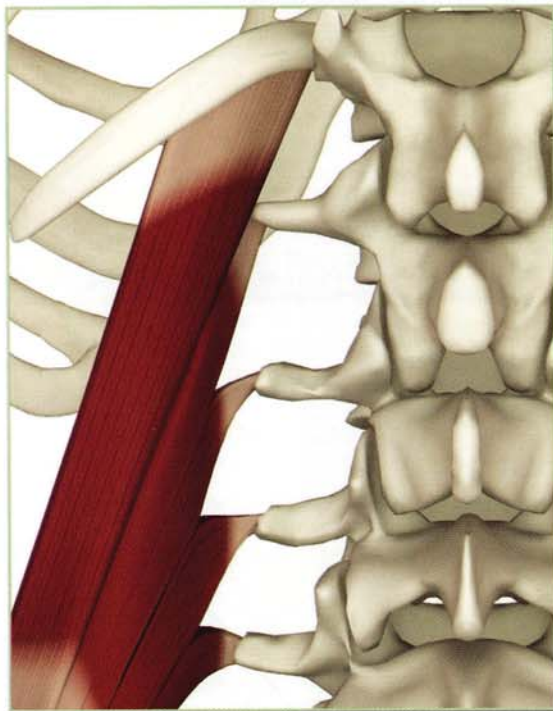
Chakra illuminated: Third and fourth



Origin

Quadratus Lumborum

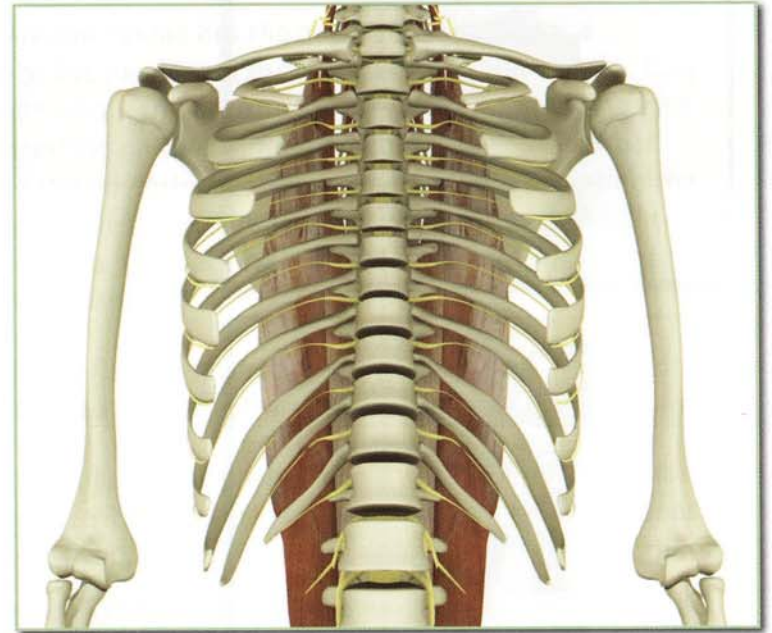
Medial iliac crest.

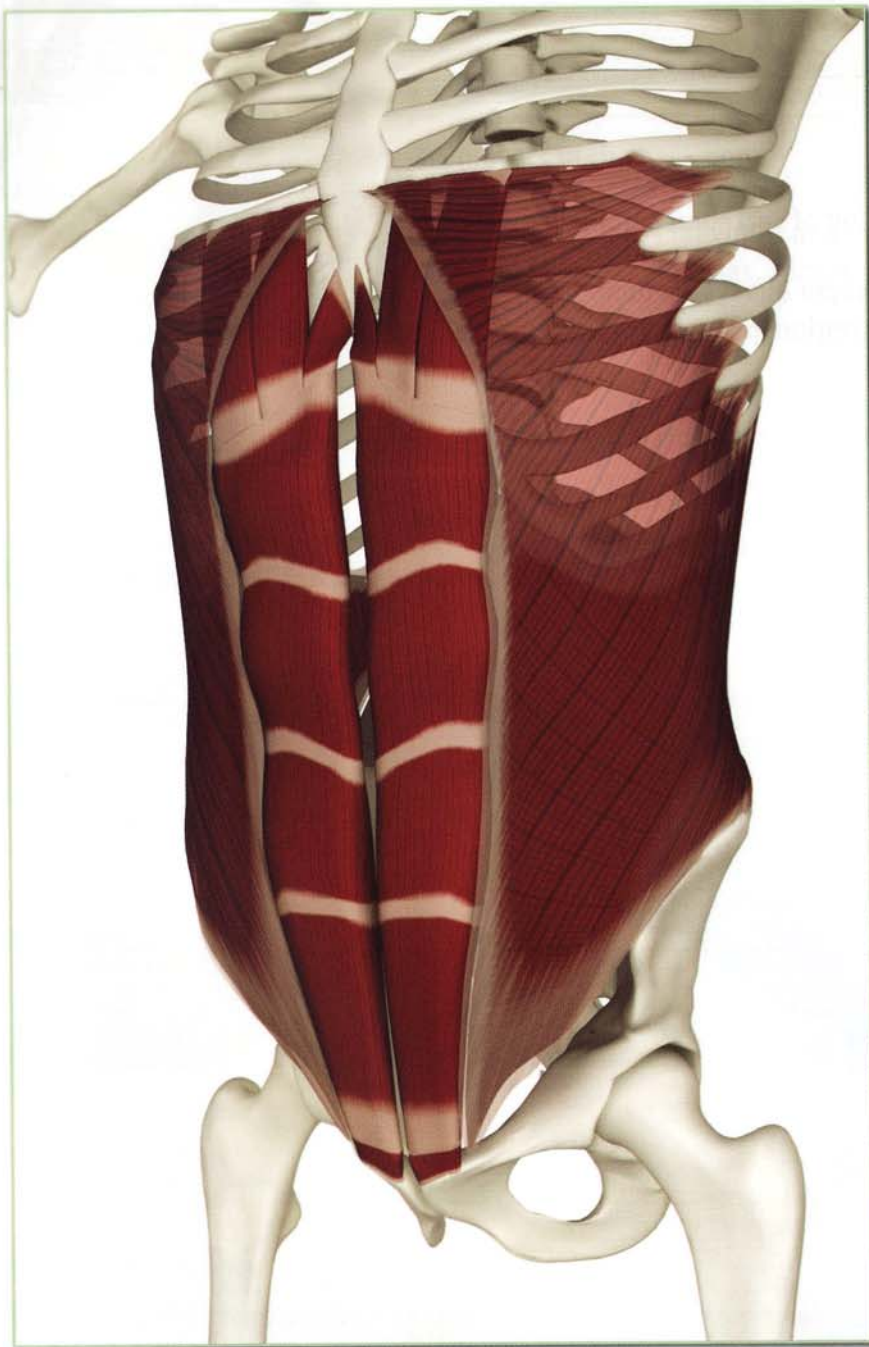


Insertion

Quadratus Lumborum

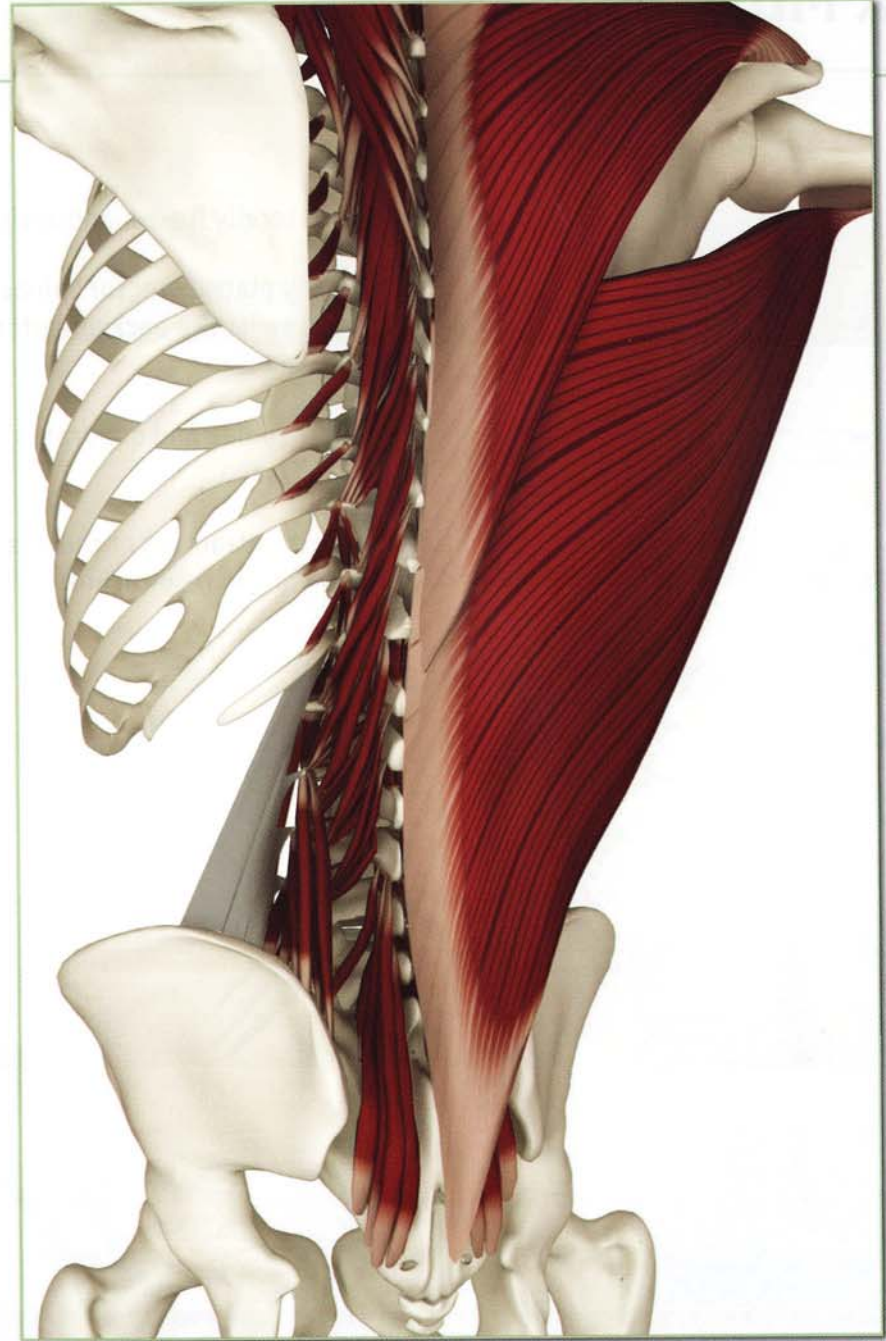
Lower border of rib 12 and transverse processes of lumbar vertebrae 1 through 4.





Antagonists

Abdominals.



Synergists

Each other, latissimus dorsi and trapezius.

Back Muscles

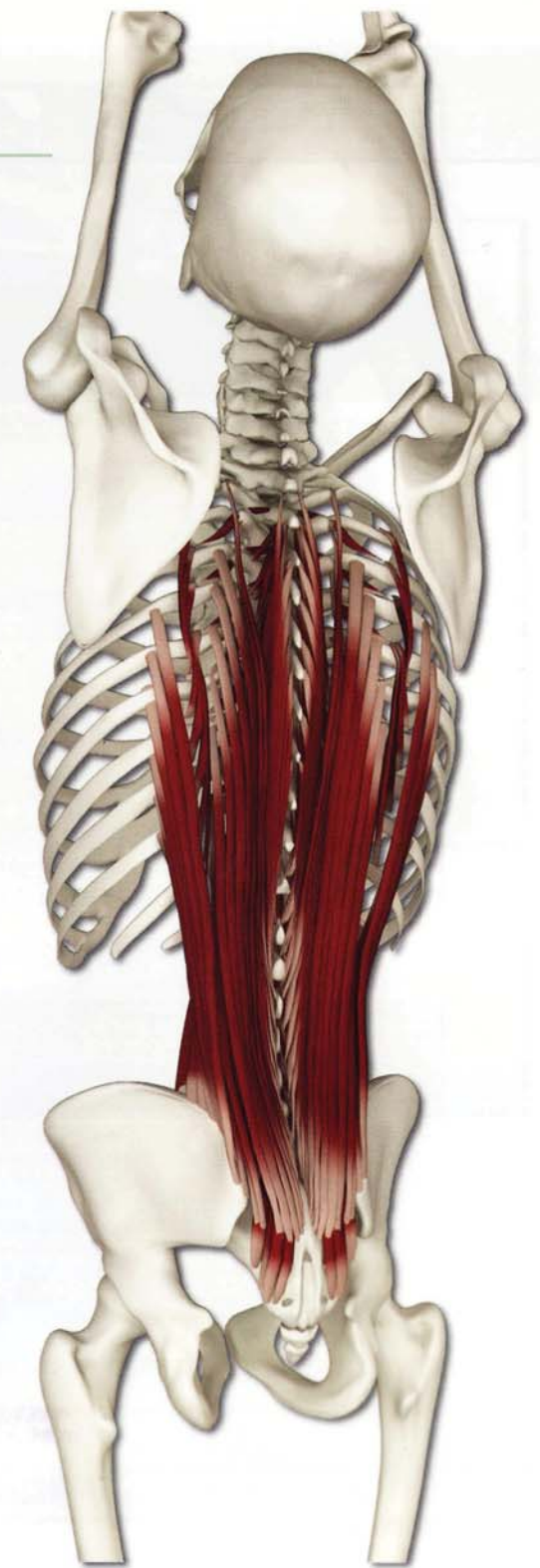
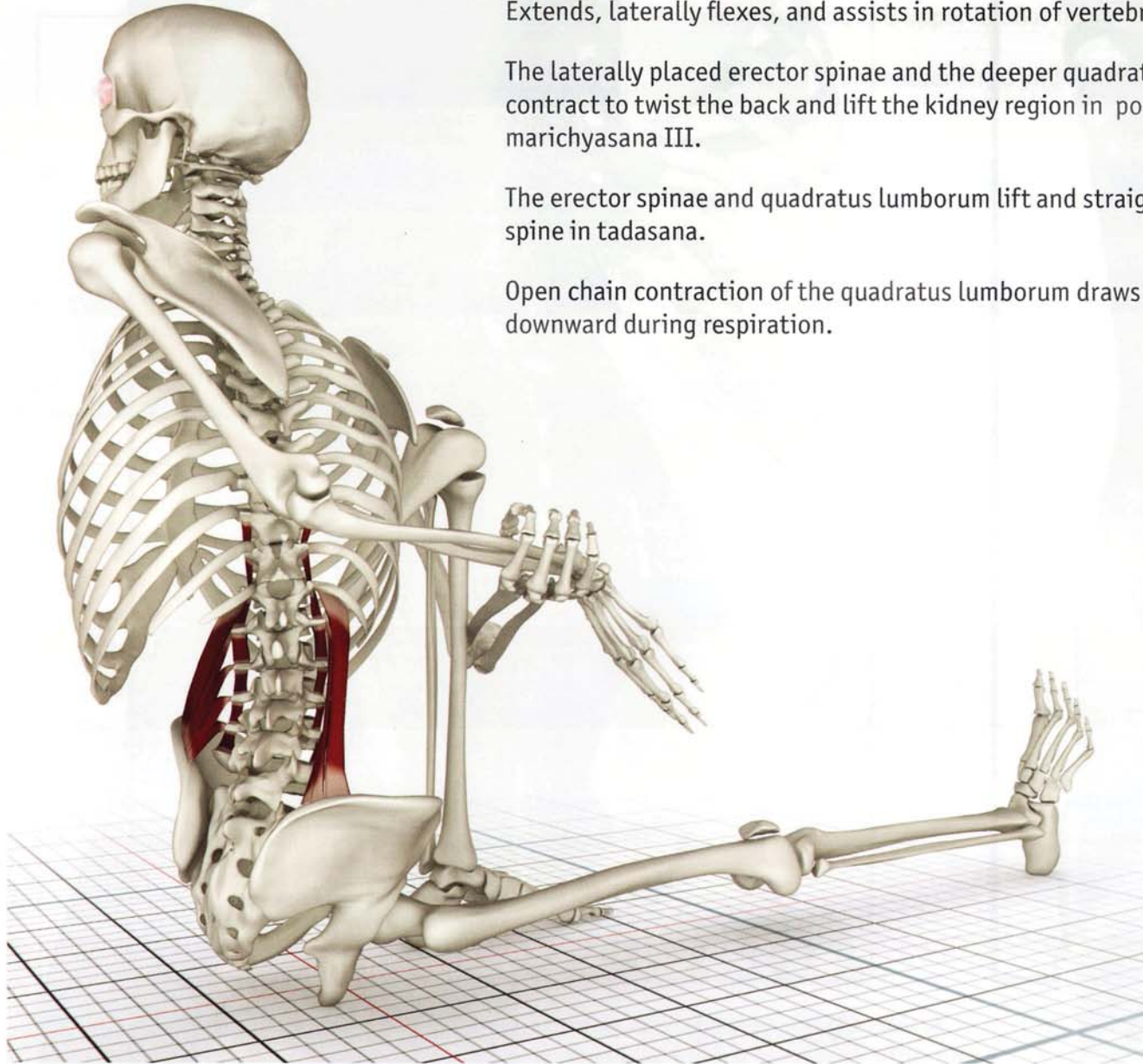
Action

Extends, laterally flexes, and assists in rotation of vertebral column.

The laterally placed erector spinae and the deeper quadratus lumborum contract to twist the back and lift the kidney region in poses such as marichyasana III.

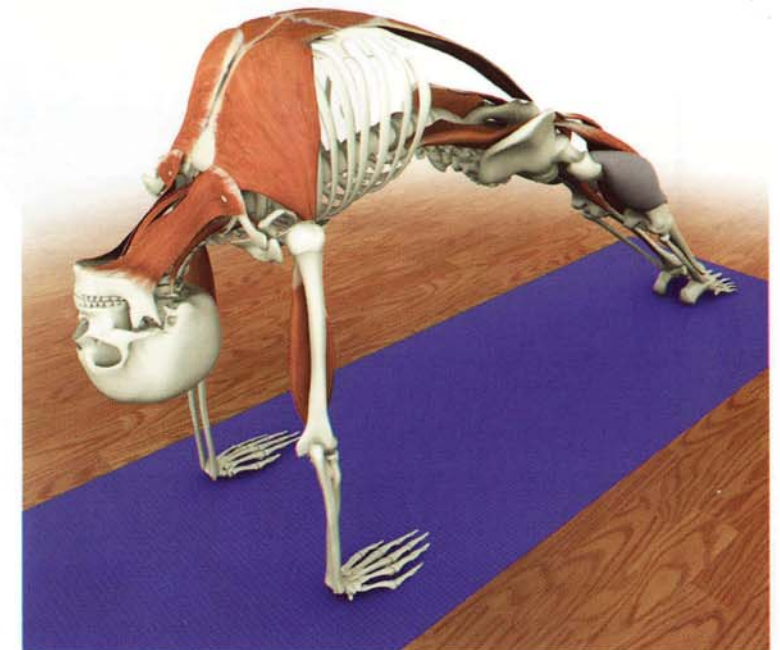
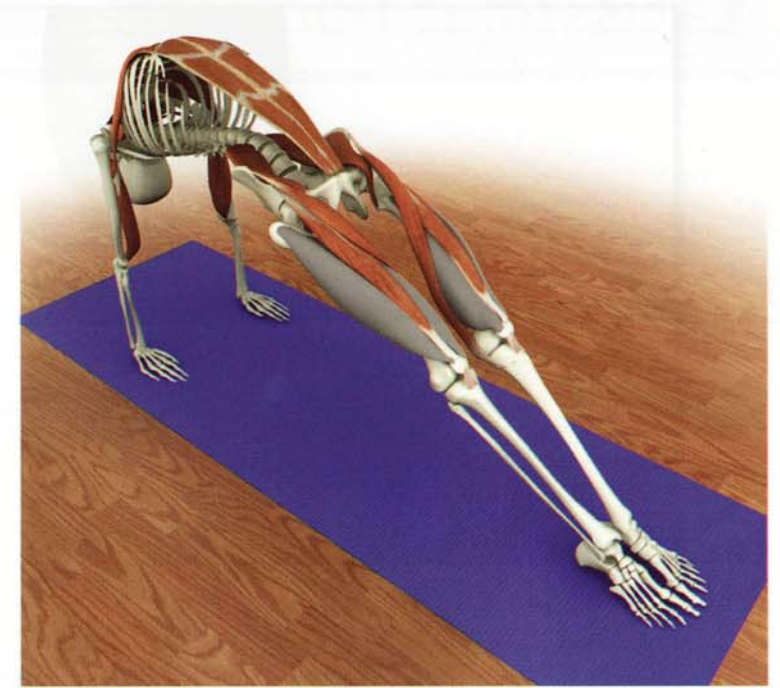
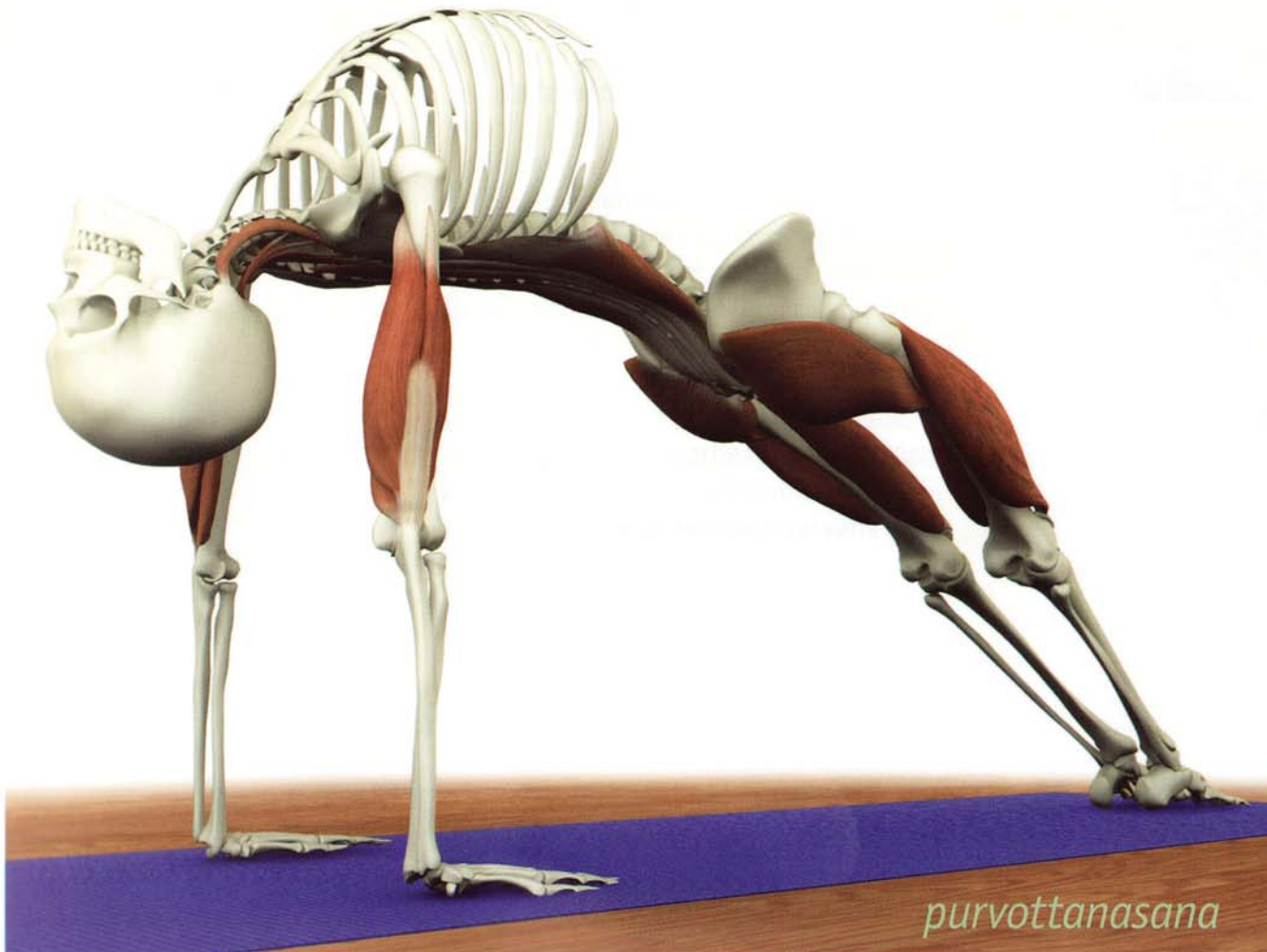The erector spinae and quadratus lumborum lift and straighten the spine in tadasana.

Open chain contraction of the quadratus lumborum draws the ribs downward during respiration.



Synergy Chapter 11

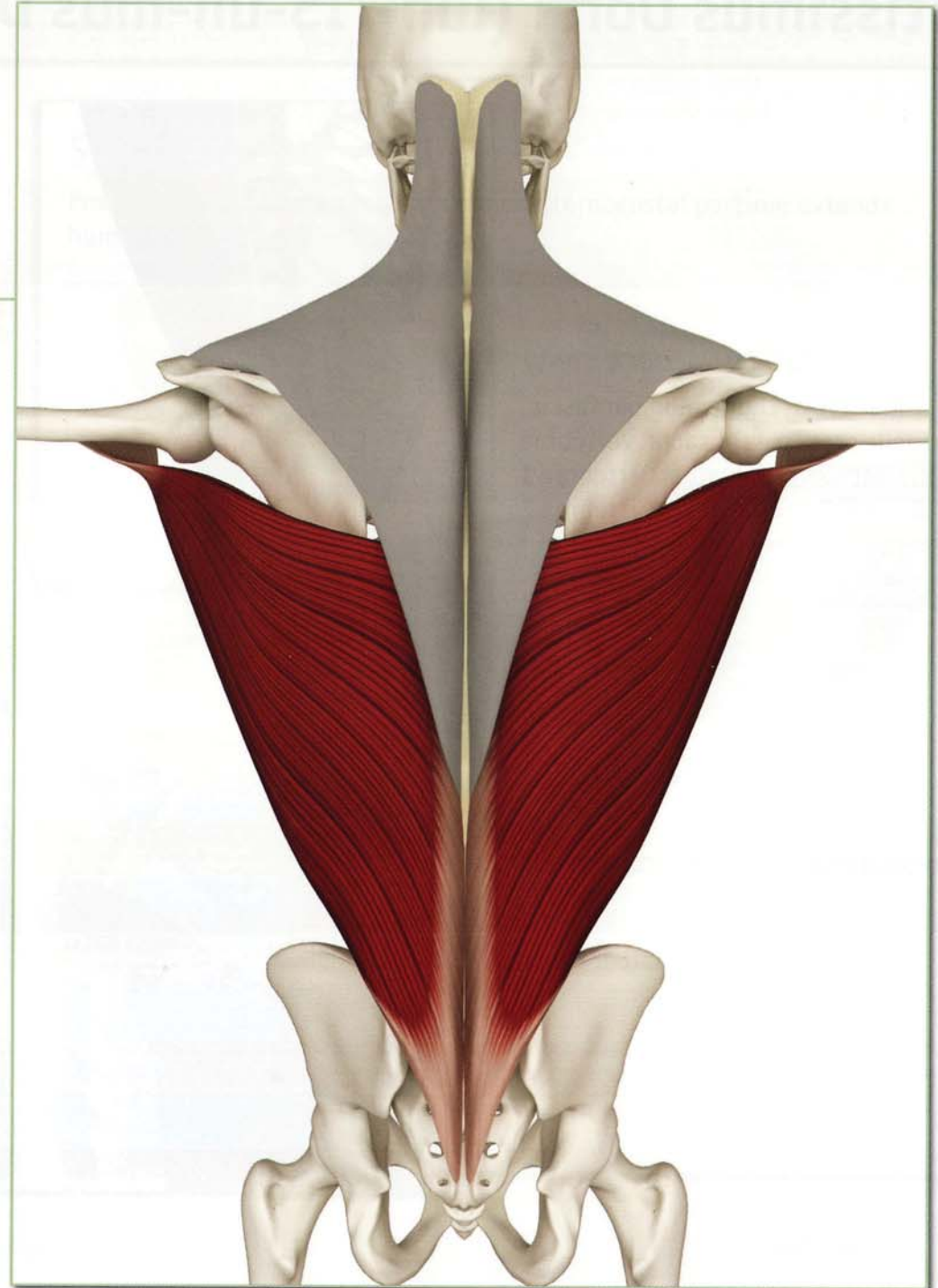
The erector spinae muscles are the prime movers in the back bend purvottanasana. Combine contracting the erector spinae with the synergists of this pose, including the quadriceps, gluteus maximus and triceps. This combination stretches the rectus femoris, iliopsoas, rectus abdominus, pectoralis major, triceps and anterior neck muscles.



Chapter 11

Latissimus Dorsi

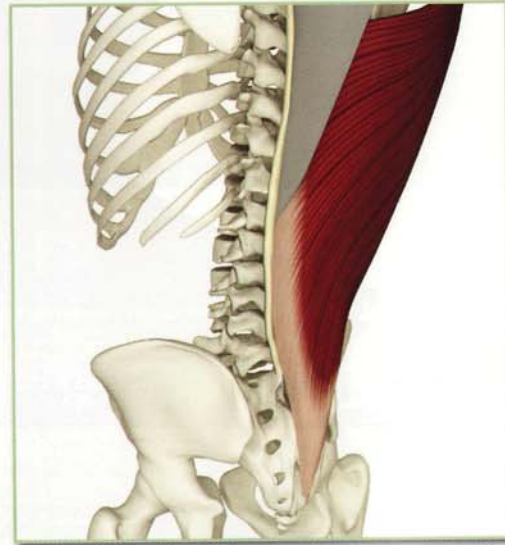
The latissimus dorsi forms two-thirds of the superficial back muscles, originating from the posterior iliac crest, sacrum and thoraco-lumbar fascia, rotating 180° before inserting on the inside of the proximal humerus. This “twist” increases the torque generated by contraction of the latissimus dorsi. This muscle draws the arm down and toward the body from the overhead position, internally rotating the humerus. When the humerus is fixed (as in certain twists or upward dog), contraction of the latissimus draws the chest forward and opens it. Tightness limits overhead postures such as virabhadrasana I, urdhvadhanurasana, and adhomukhasvanasana.



Latissimus Dorsi (luh-TIS-uh-mus DOR-si)

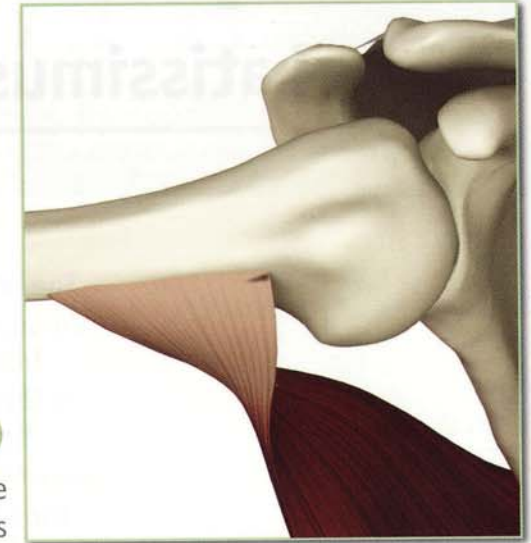
Origin (back view)

Iliac crest, thoracolumbar fascia, spinous processes of sacral vertebrae 1 through 5, lumbar vertebrae 1 through 5, and thoracic vertebrae 7 through 12, lower 3 ribs and inferior angle of scapula.



Insertion (front view)

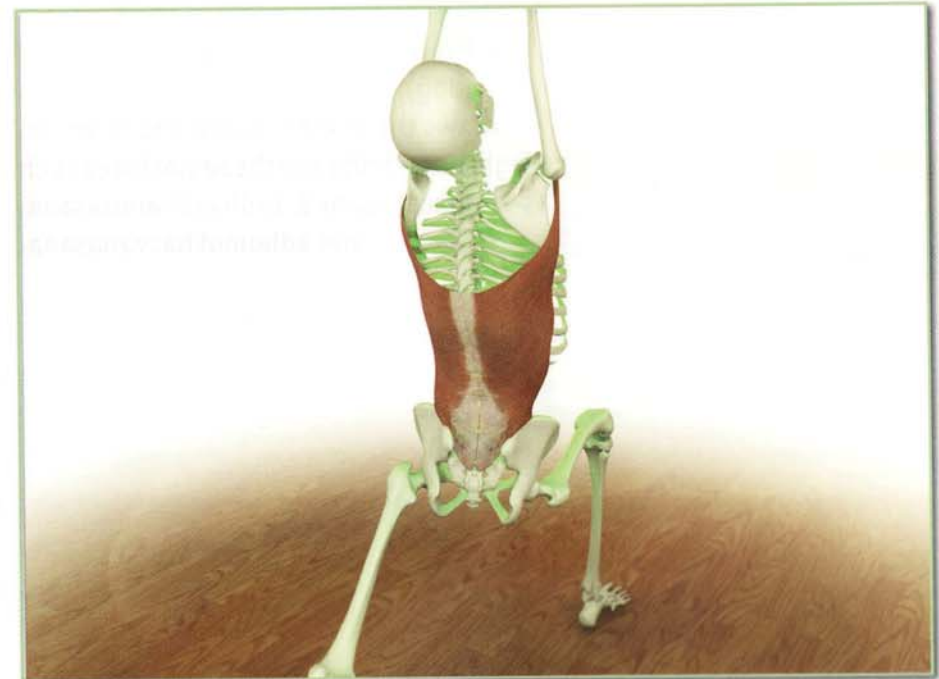
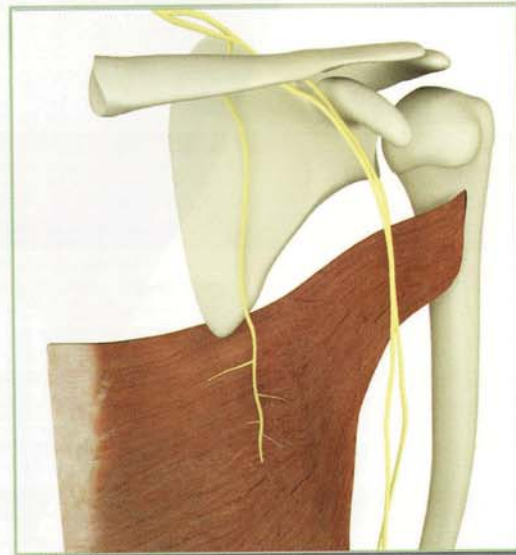
Floor of the bicipital groove of the humerus



Innervation & chakra illuminated

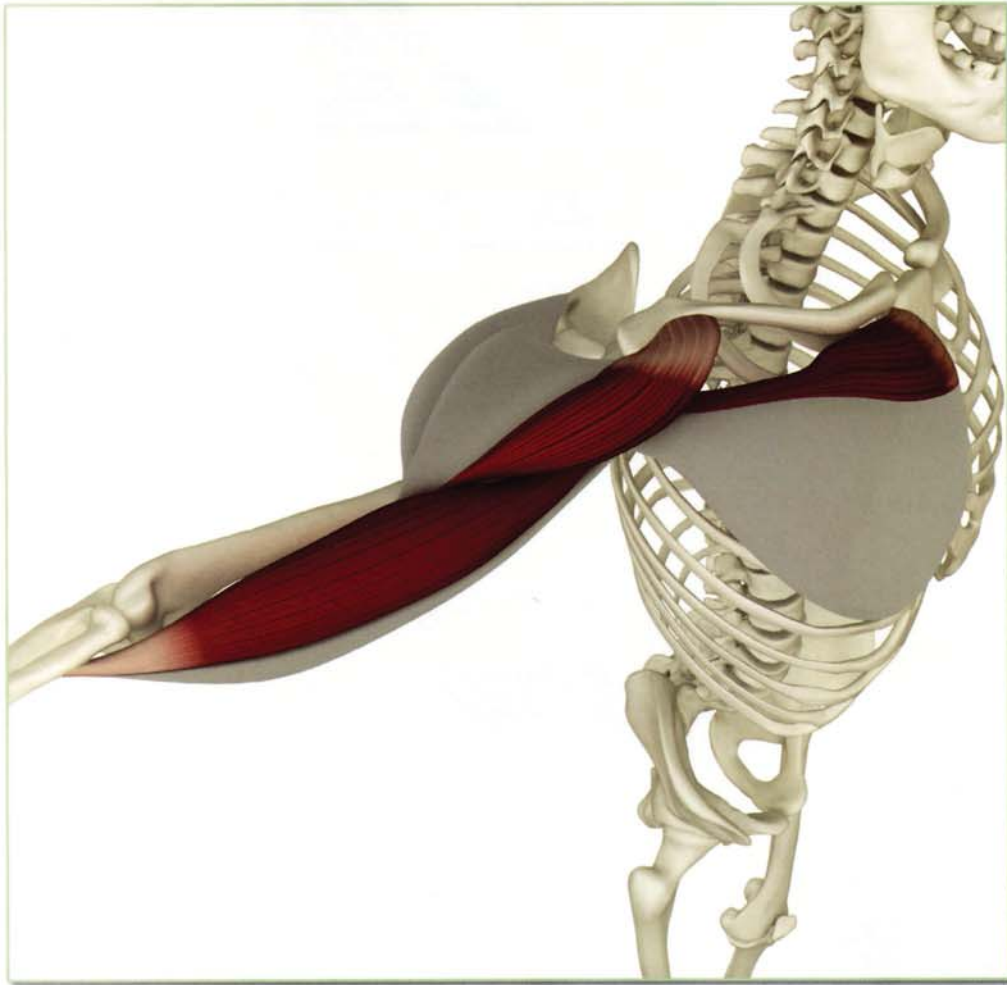
Thoracodorsal nerve (cervical nerves 6, 7 and 8).

Chakra illuminated: Fourth



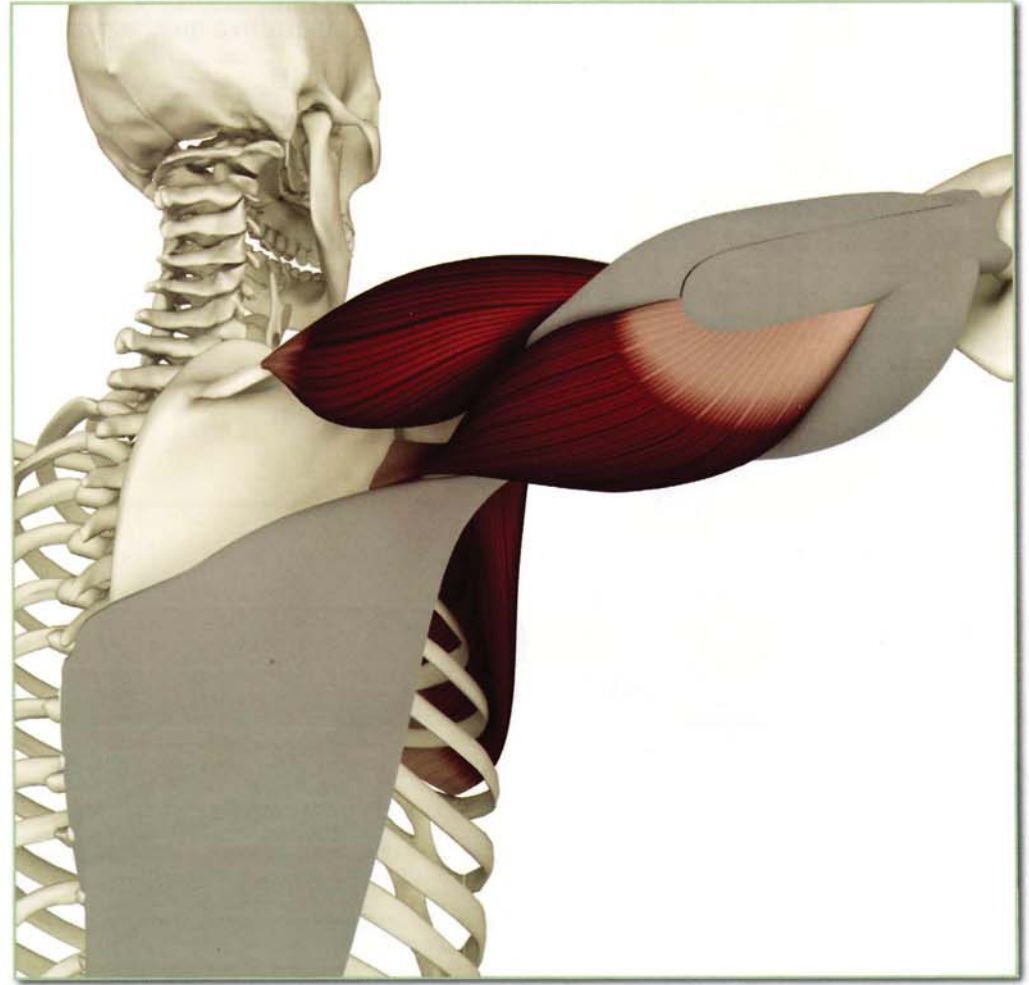
Antagonists

Anterior deltoids, pectoralis major (clavicular portion) and long head of biceps.



Synergists

Posterior deltoids and pectoralis major (sternocostal portion; extends humerus). Long head of triceps.



Latissimus Dorsi (luh-TIS-uh-mus DOR-si)

Action

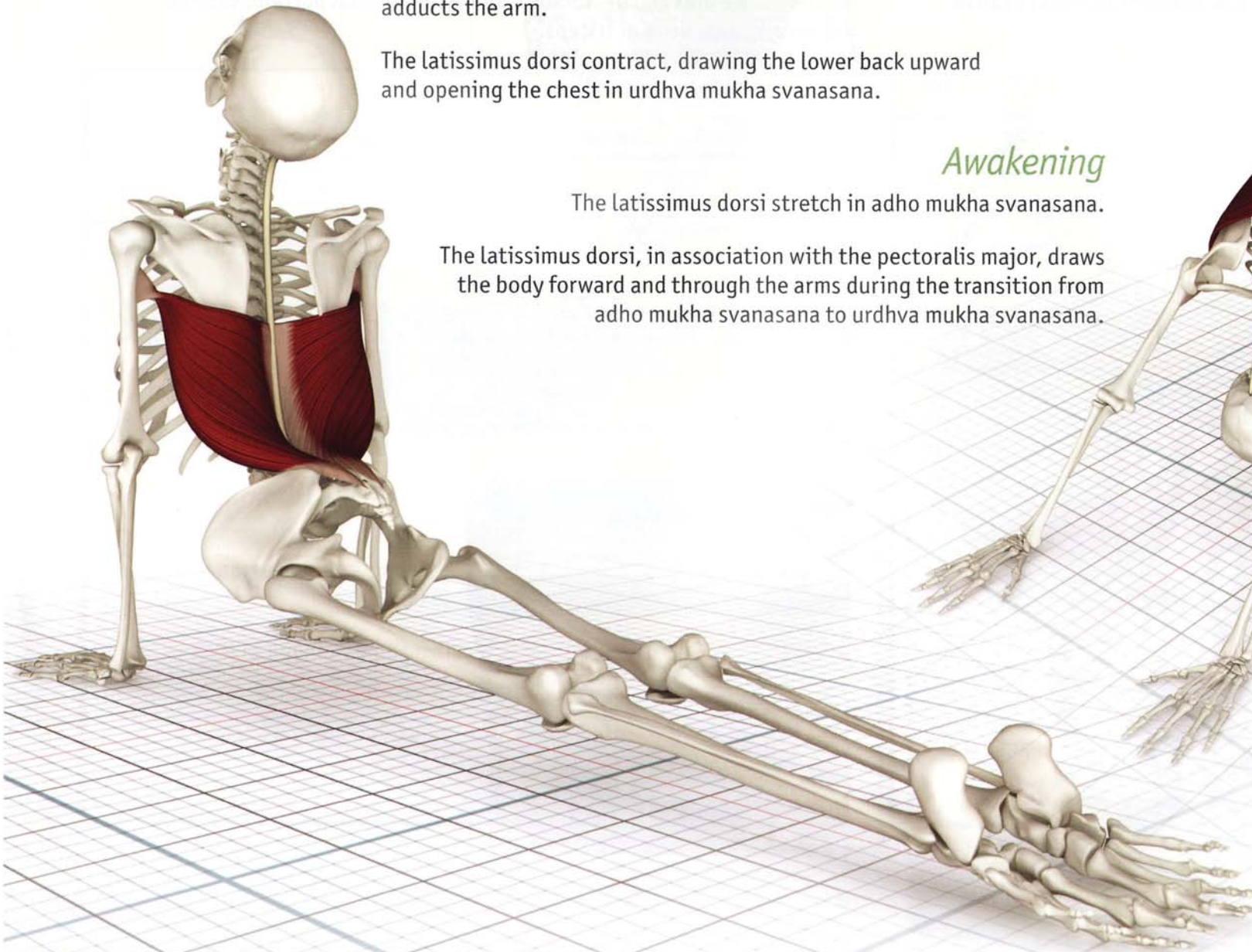
Extends the arm (from a flexed position). Internally rotates and adducts the arm.

The latissimus dorsi contract, drawing the lower back upward and opening the chest in urdhva mukha svanasana.

Awakening

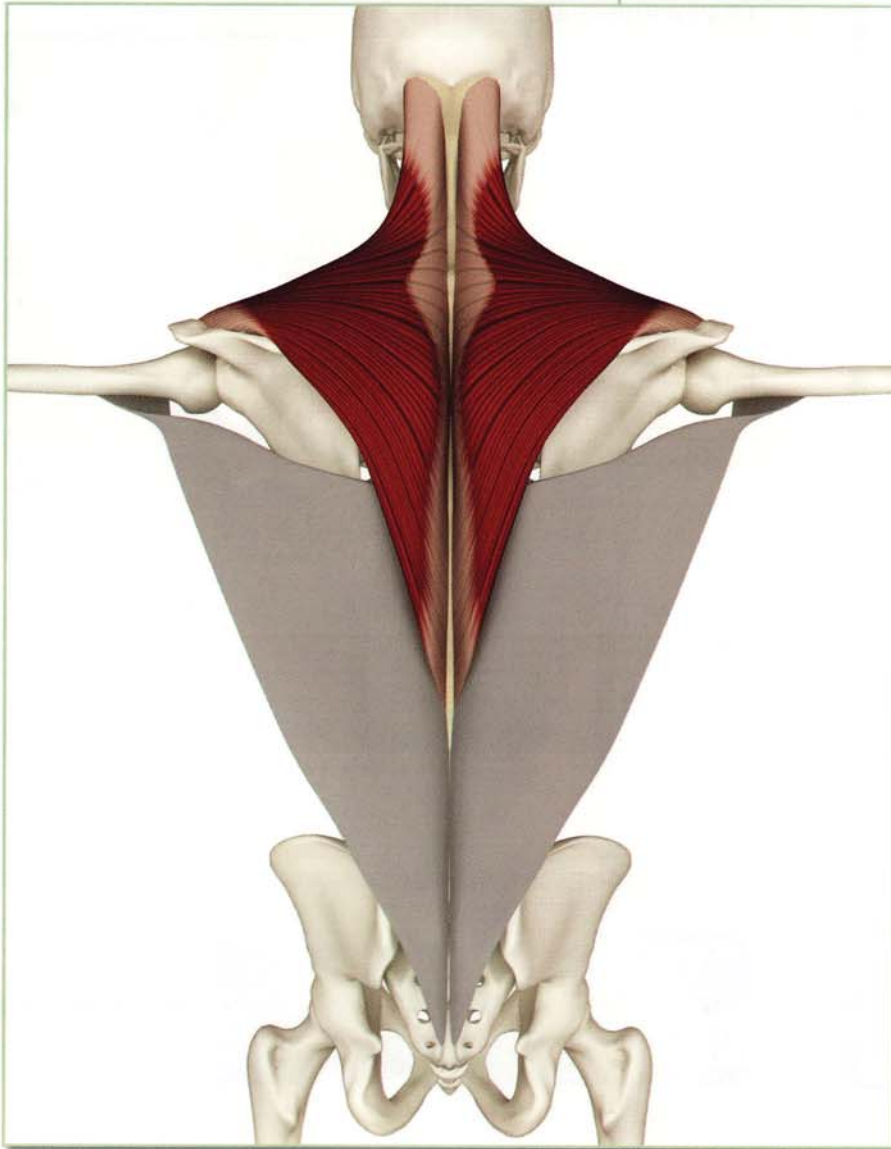
The latissimus dorsi stretch in adho mukha svanasana.

The latissimus dorsi, in association with the pectoralis major, draws the body forward and through the arms during the transition from adho mukha svanasana to urdhva mukha svanasana.



Chapter 12

Trapezius



This is a broad triangular-shaped muscle originating from the center of the back, extending from the lower thoracic spine to the base of the skull, inserting on the scapula and clavicle. Contraction of the lower fibers draws the scapula downward. Contraction of the upper fibers elevates and rotates the scapula upward. This action increases contact of the humeral head with the glenoid in overhead movements (such as full arm balance). Contraction of the middle fibers adducts the scapula, assisting the rhomboids to open the chest.

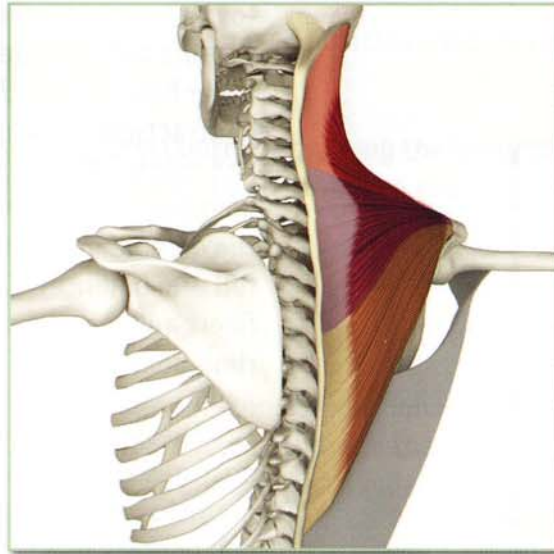
Tightness in the middle fibers limits postures such as gomukhasana B. Weakness in the lower and upper fibers limits arm balances such as tolasana and vrksasana respectively.

Trapezius (tra-PE-ze-us)

Origin

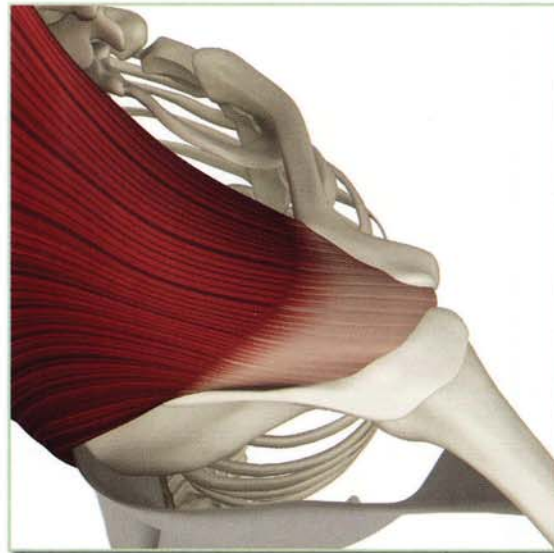
Base of skull, posterior ligaments of neck and spinous processes of cervical vertebra 2 through thoracic vertebra 12.

(illustration shows upper, middle and lower fibers of the trapezius)



Insertion (top view)

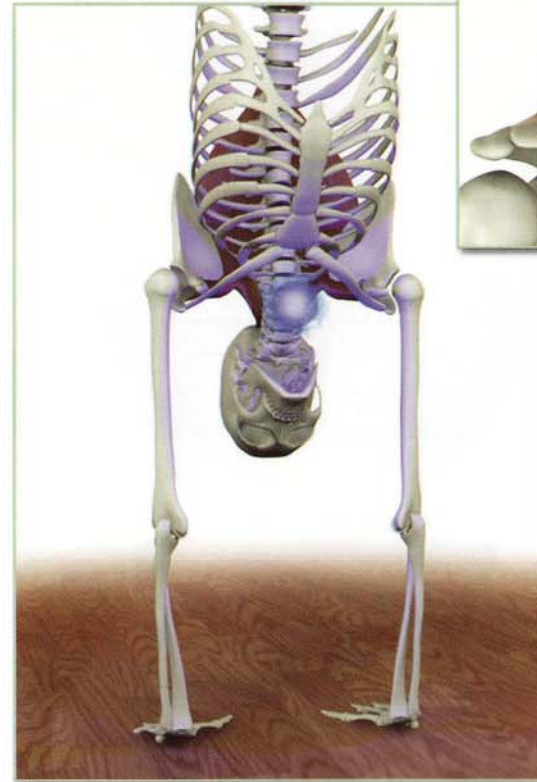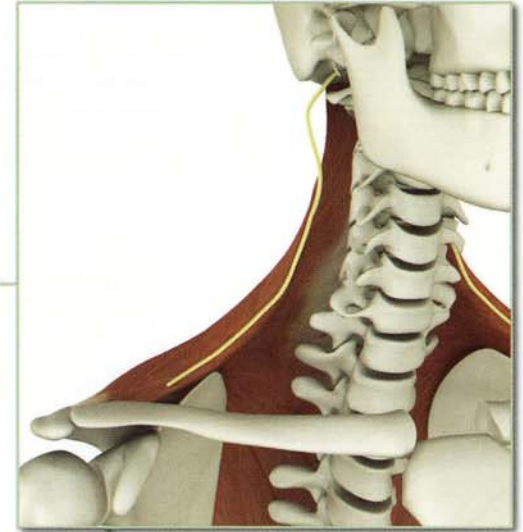
Posterior aspect of lateral third of the clavicle, medial margin of acromion and superior spine of the scapula.



Innervation & chakra illuminated

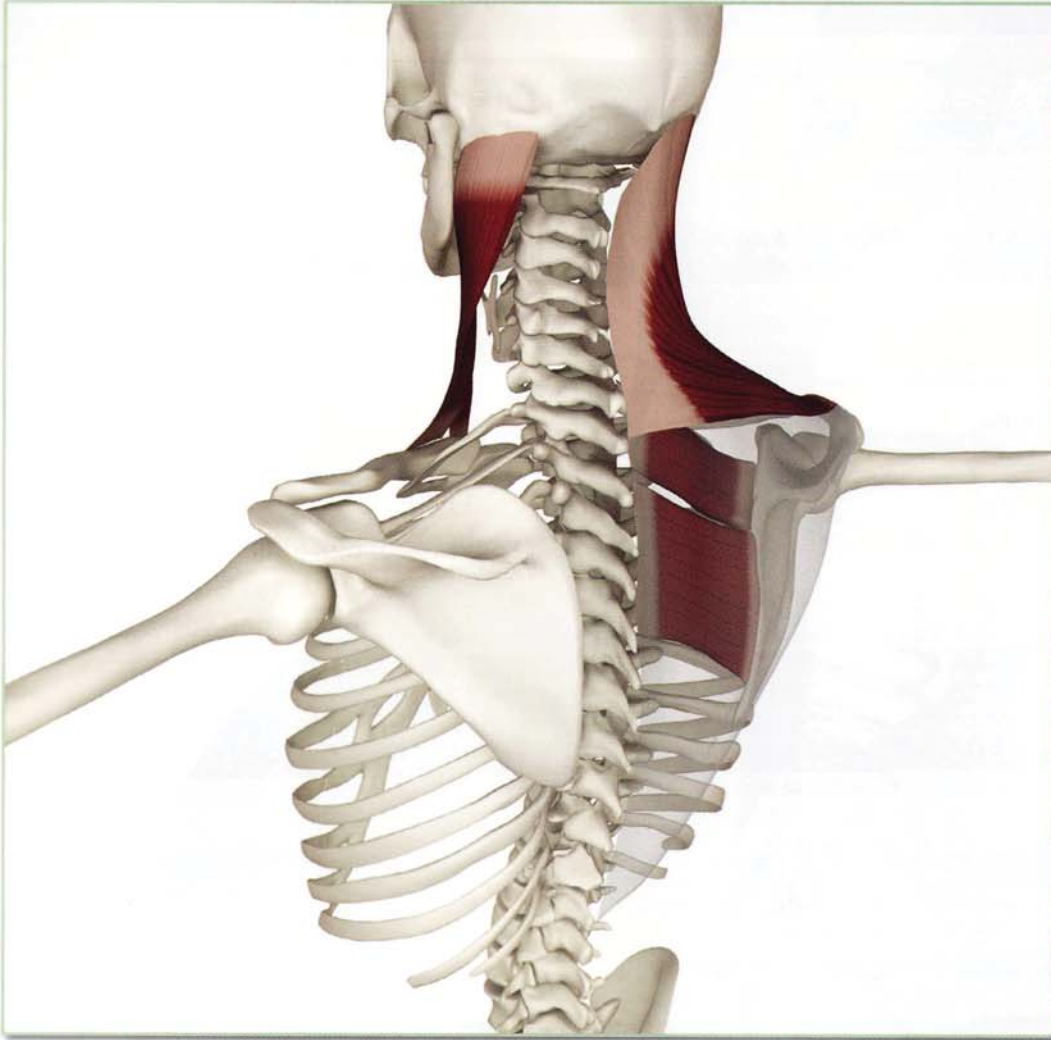
Accessory nerve (cranial nerve 11, and cervical nerves 3 and 4).

Chakra illuminated: Fifth



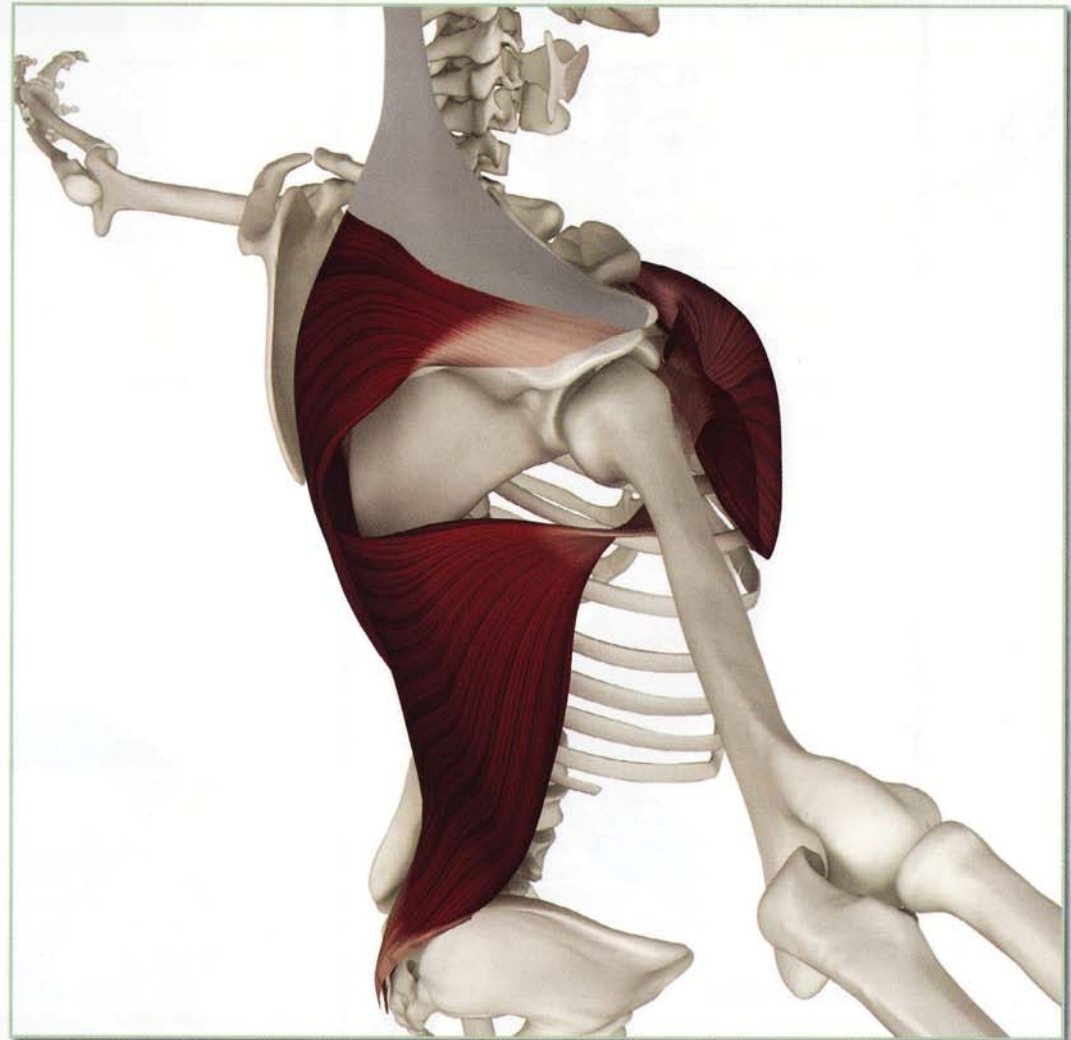
Antagonists Lower Fibers

Upper fibers of trapezius, rhomboid major, minor and sternocleidomastoid.



Antagonists Upper Fibers

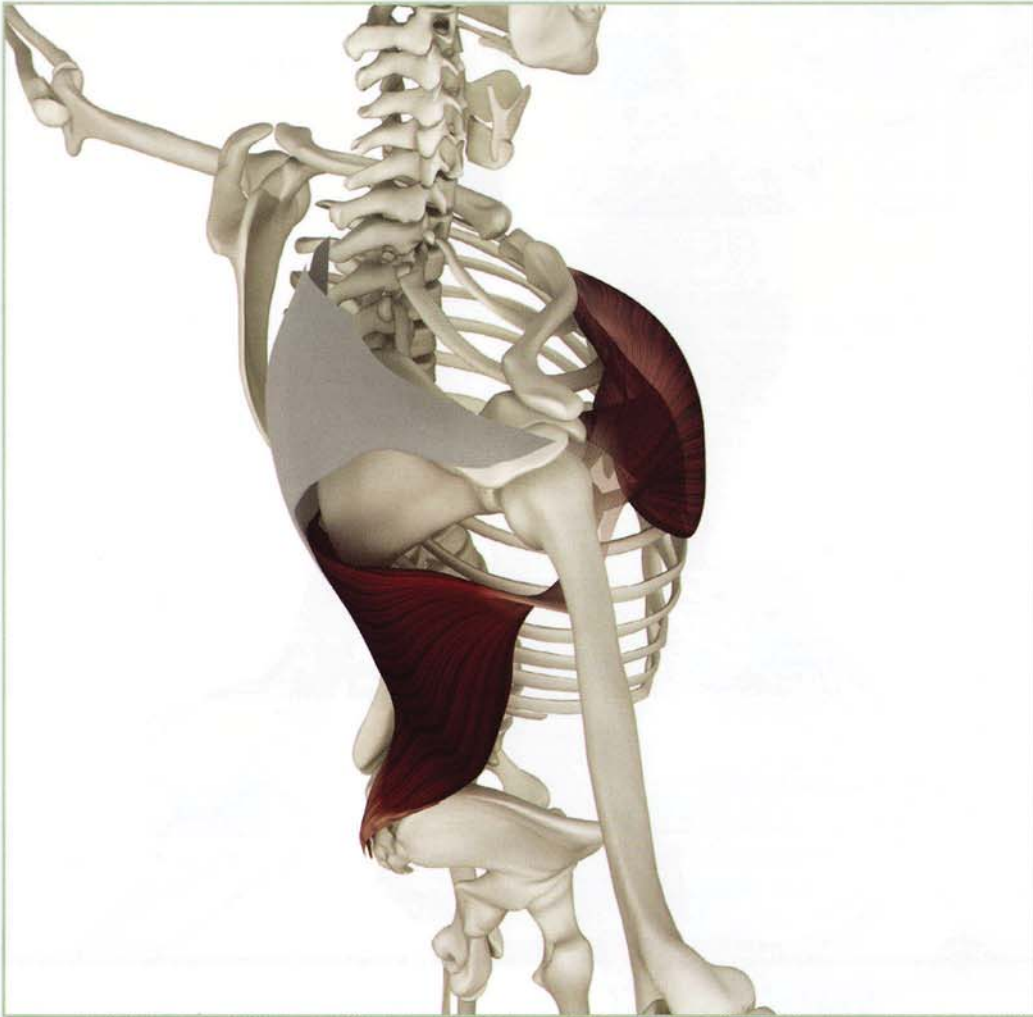
Lower fibers of trapezius, pectoralis minor, major and latissimus dorsi.



Trapezius (tra-PE-ze-us)

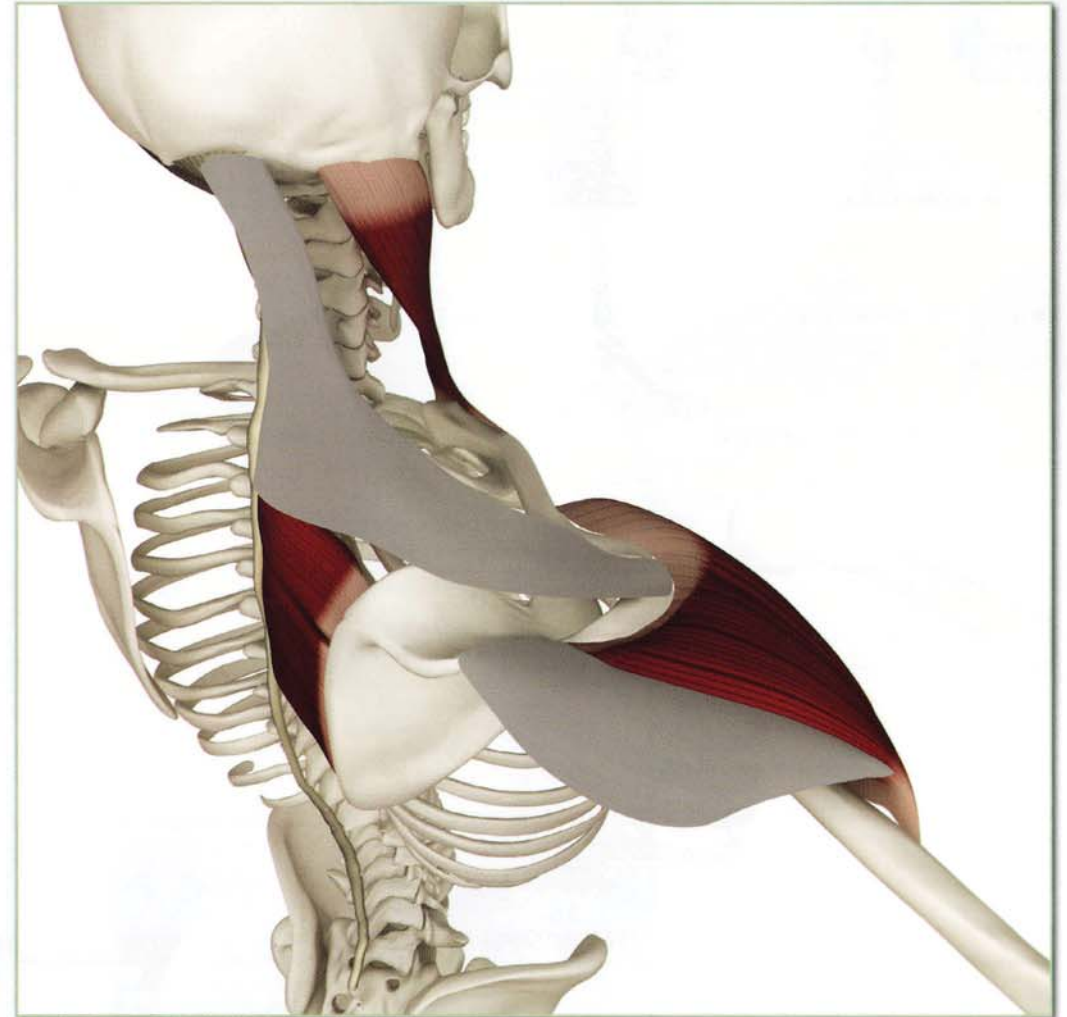
Synergists Lower Fibers

Pectoralis minor, major and latissimus dorsi.



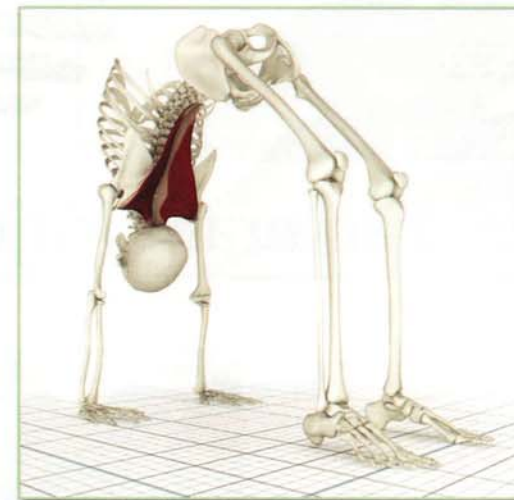
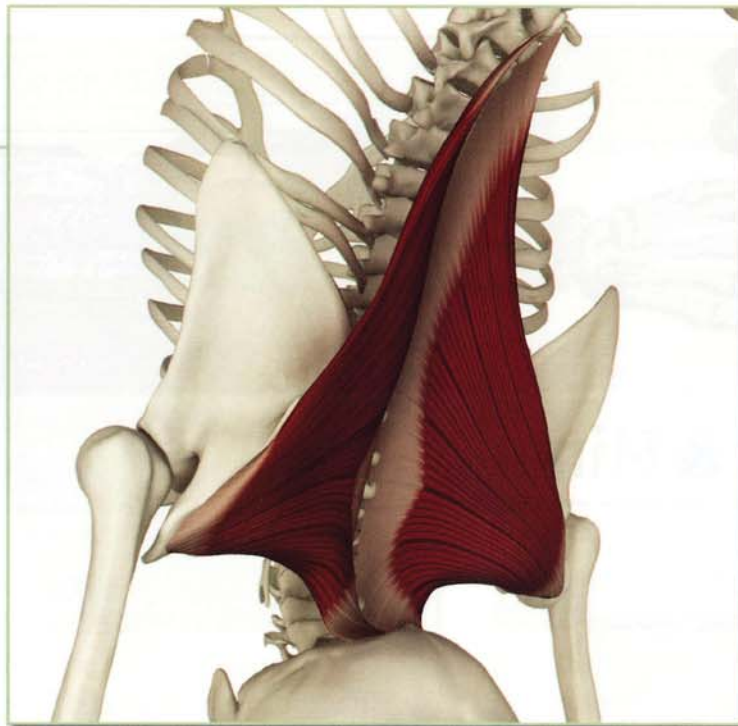
Synergists Upper Fibers

Anterior and lateral deltoids, rhomboid major, minor and sternocleidomastoid.



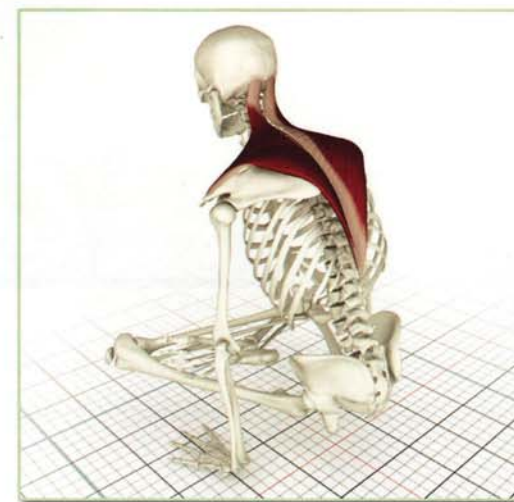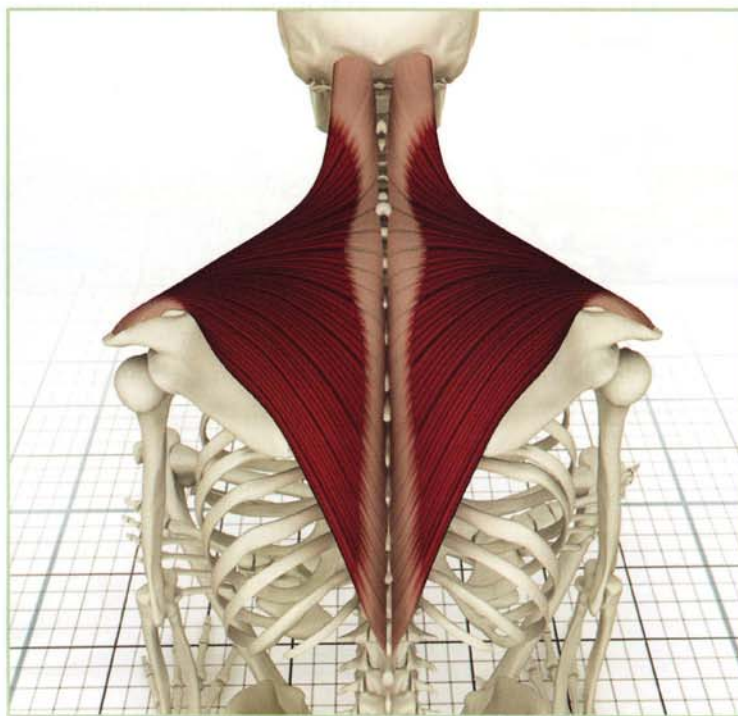
Action

The upper fibers of the trapezius contract in urdhvadhanurasana assisting the lift of the upper body, outwardly rotating the scapula and drawing the glenoid into greater contact with the humeral head.



Awakening

The middle and lower fibers of the trapezius contract in tolasana, lifting the body, retracting the scapular inward and downward. Weakness in this muscle limits the ability to perform this pose.



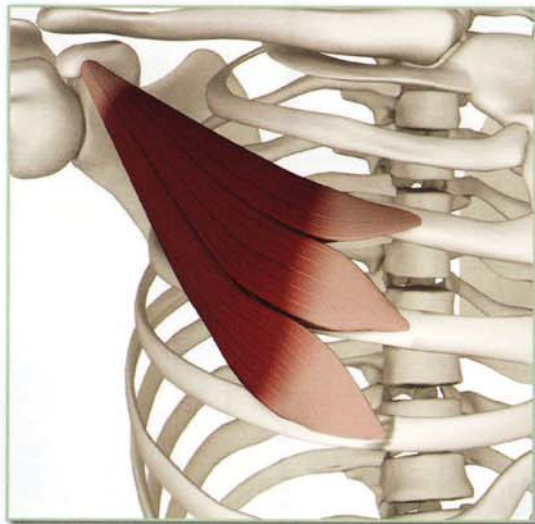
Chapter 13

Pectoralis Major & Minor

Pectoralis Minor (pek-to-RA-lis):

This is a small three-headed muscle lying deep to the pectoralis major, originating from the third, fourth and fifth ribs and inserting on the coracoid process of the scapula. The pectoralis minor draws the scapula downward and forward in open chain movements.

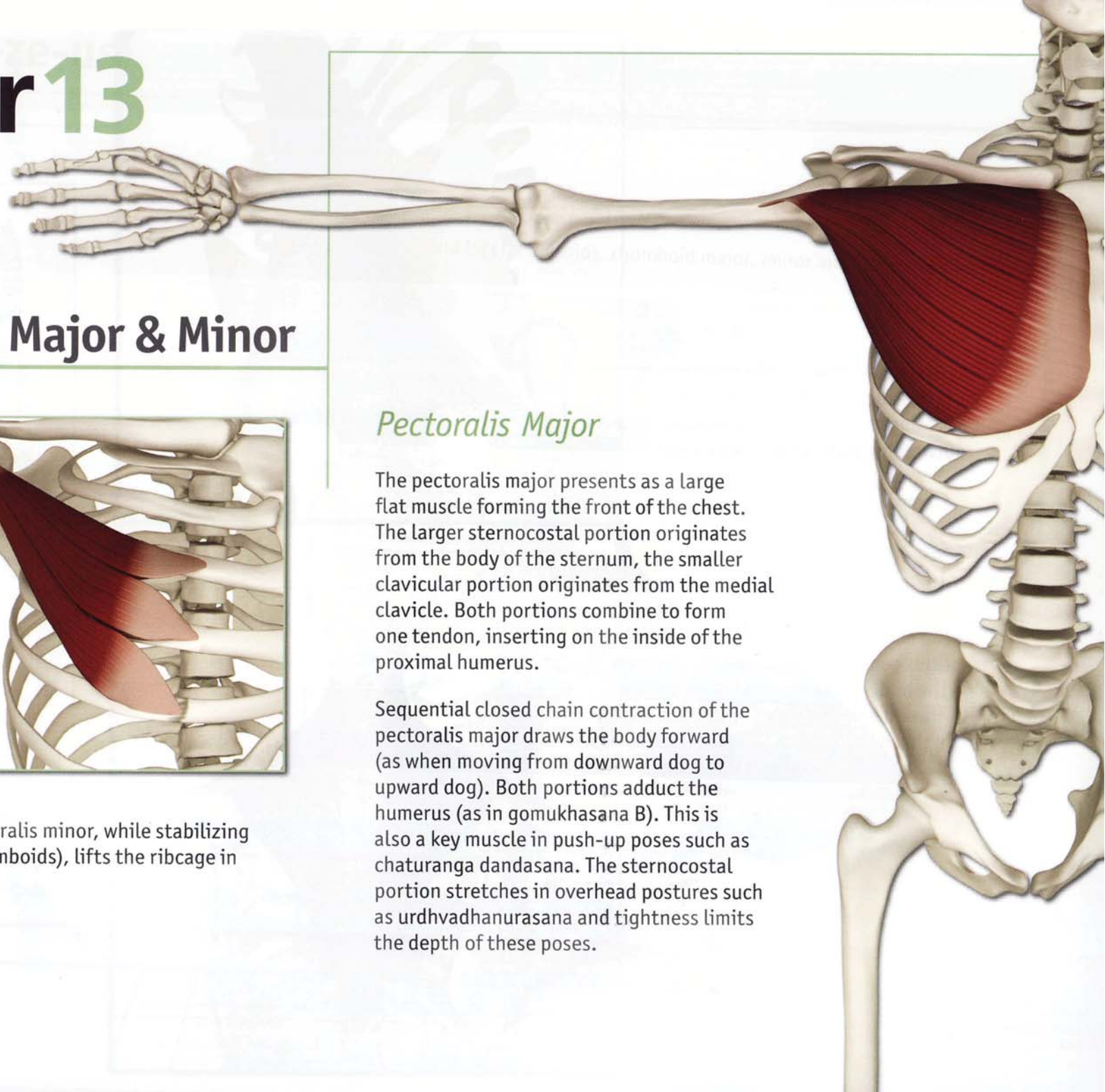
Closed chain contraction of the pectoralis minor, while stabilizing the scapula posteriorly (with the rhomboids), lifts the ribcage in respiration.



Pectoralis Major

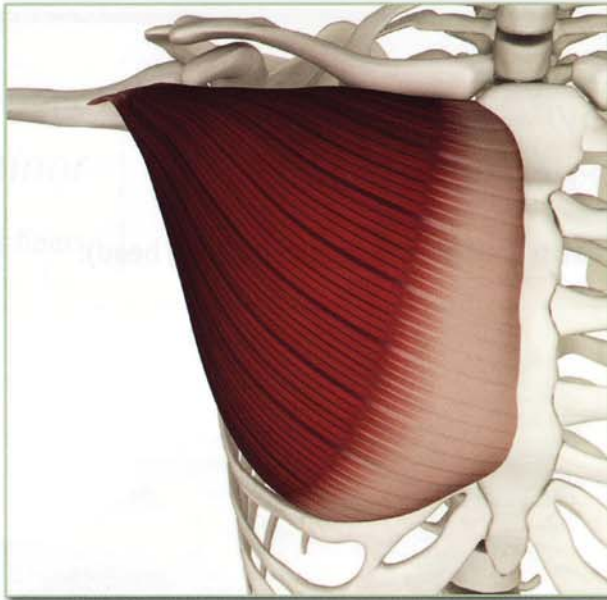
The pectoralis major presents as a large flat muscle forming the front of the chest. The larger sternocostal portion originates from the body of the sternum, the smaller clavicular portion originates from the medial clavicle. Both portions combine to form one tendon, inserting on the inside of the proximal humerus.

Sequential closed chain contraction of the pectoralis major draws the body forward (as when moving from downward dog to upward dog). Both portions adduct the humerus (as in gomukhasana B). This is also a key muscle in push-up poses such as chaturanga dandasana. The sternocostal portion stretches in overhead postures such as urdhvadhanurasana and tightness limits the depth of these poses.



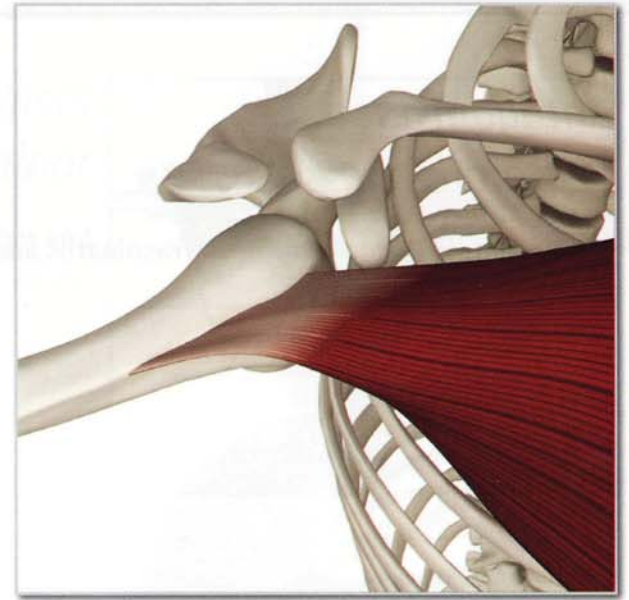
Origin
Pectoralis major

Medial 1/3 of clavicle,
anterior aspect of sternum,
upper six costal cartilages and
aponeurosis of the external
oblique.



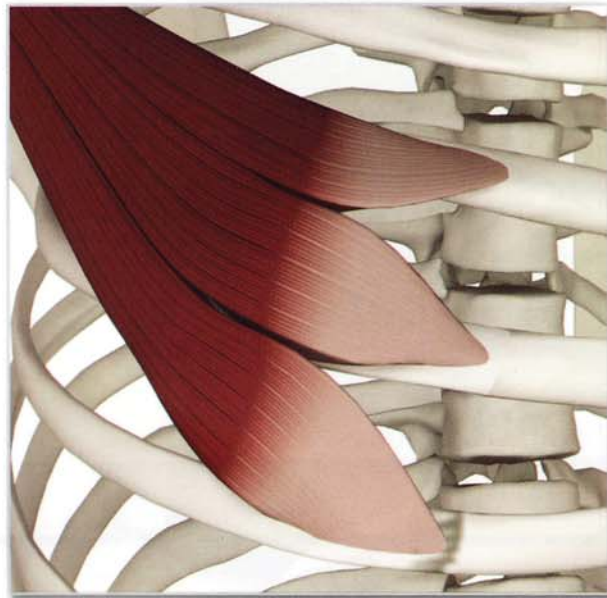
Insertion
Pectoralis major

Lateral lip of bicipital
groove (sternal fibers more
proximally, clavicular fibers
insert more distally).



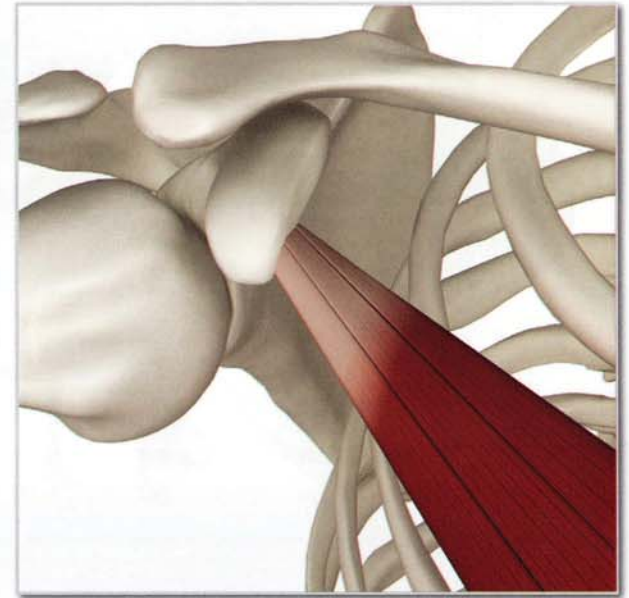
Origin
Pectoralis minor

Outer surface of ribs 2 through 5.



Insertion
Pectoralis minor

Coracoid process of the
scapula.

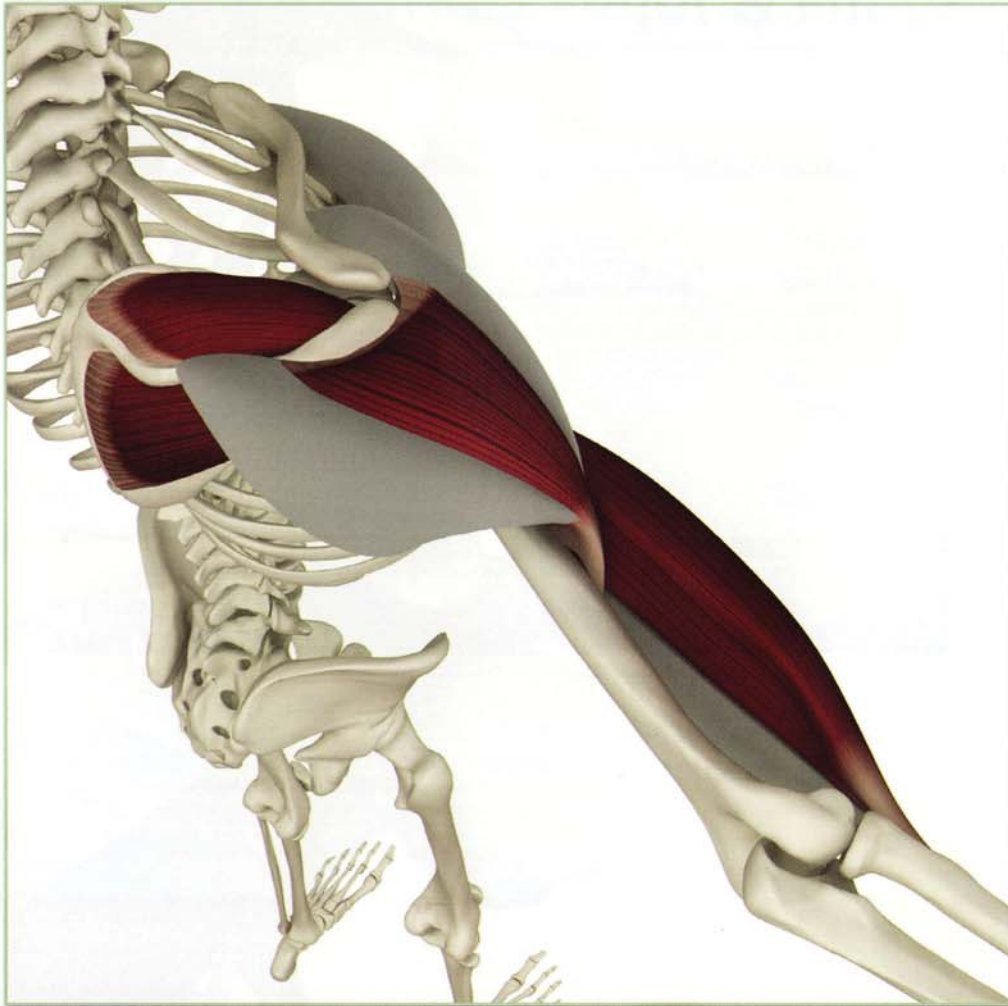


Pectoralis Major & Minor

Antagonists

Pectoralis major

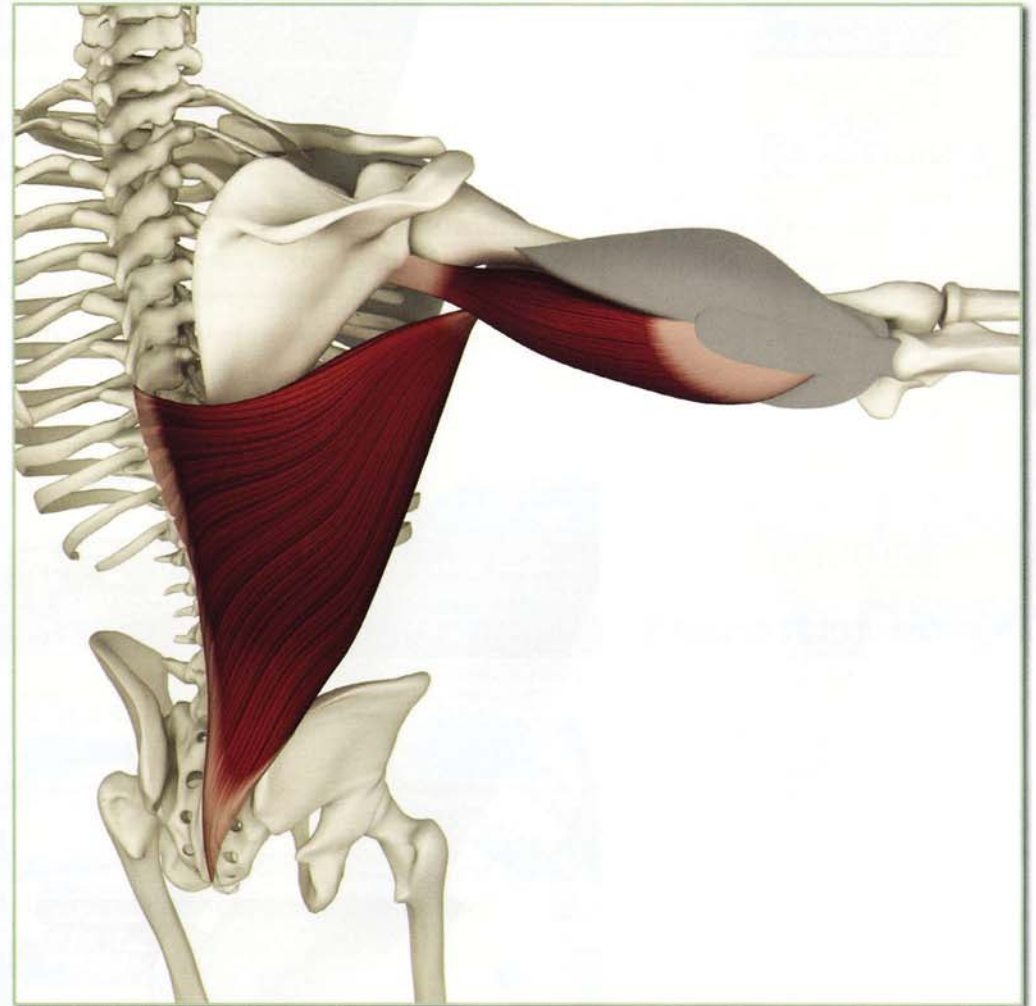
Middle deltoid, supraspinatus, infraspinatus and biceps (long head).



Synergists

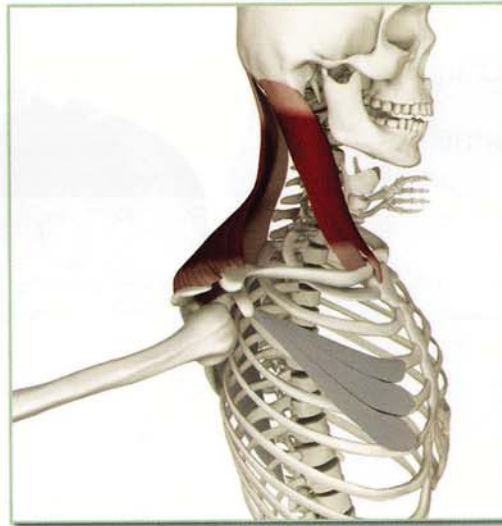
Pectoralis major

Latissimus dorsi and triceps (long head).



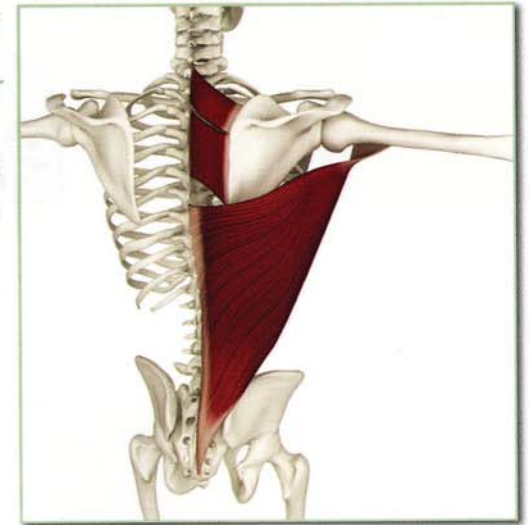Antagonists Pectoralis minor

Sternocleidomastoid and upper fibers of the trapezius.



Synergists Pectoralis minor

Rhomboid major, minor and latissimus dorsi.



Innervation & chakra illuminated

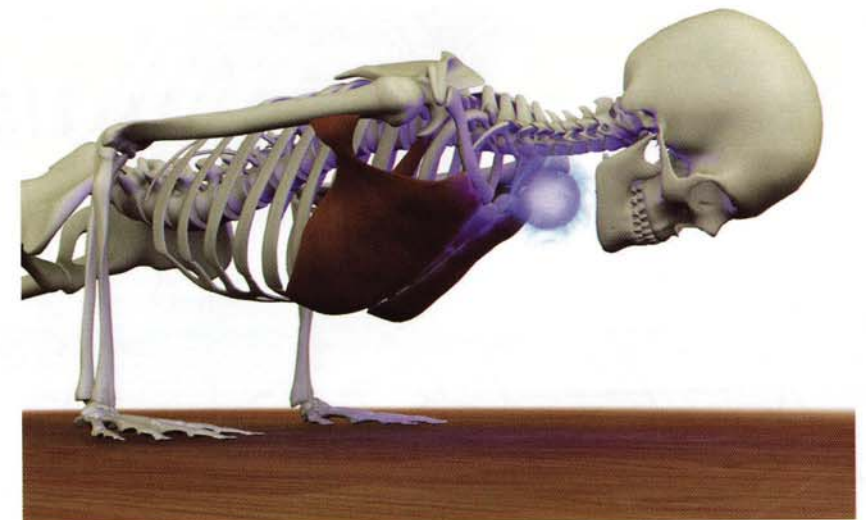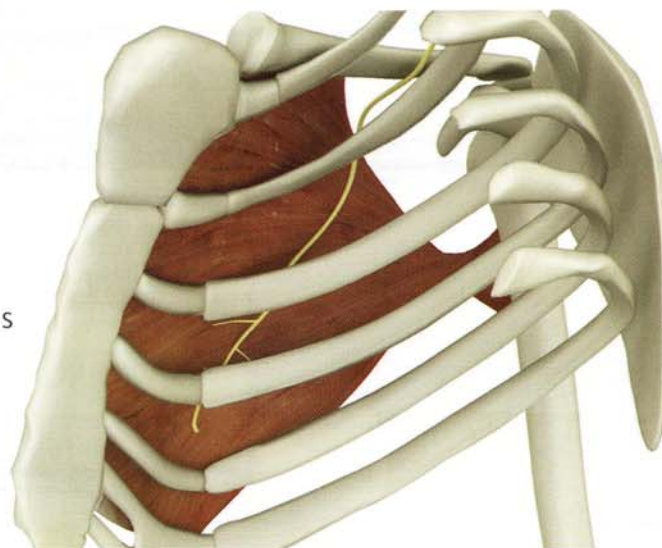
Pectoralis major:

Clavicular portion: Lateral pectoral nerve (cervical nerves 5 through 7)
Sternal portion: Medial pectoral nerve (cervical nerves 8 through thoracic nerve 1).

Pectoralis minor:

Medial pectoral nerve (cervical nerves 8 through thoracic nerve 1).

Chakra illuminated: Fifth



Pectoralis Major & Minor

Action

Adducts and internally rotates arm.

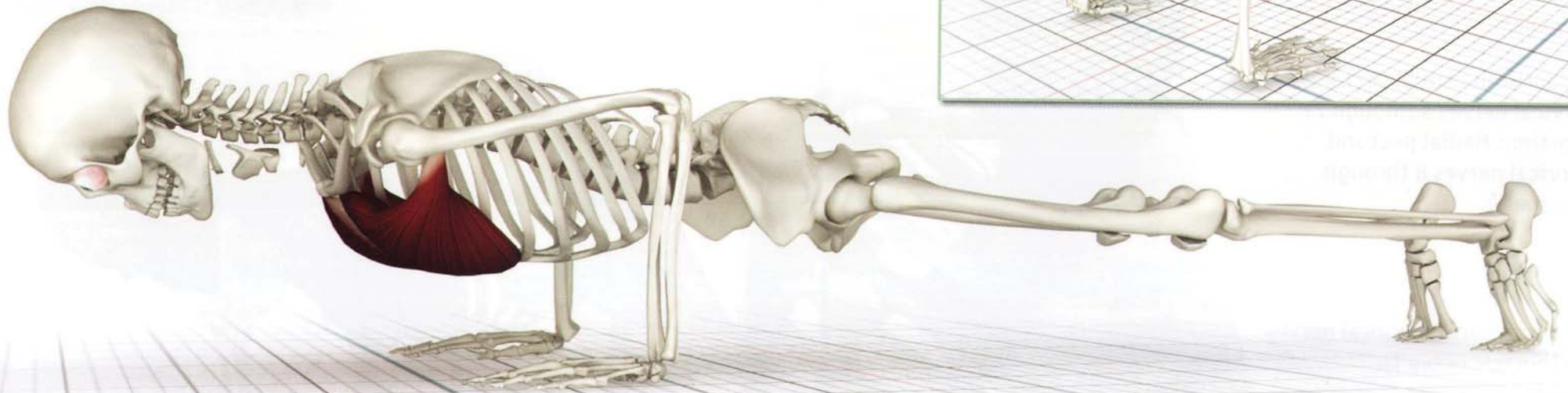
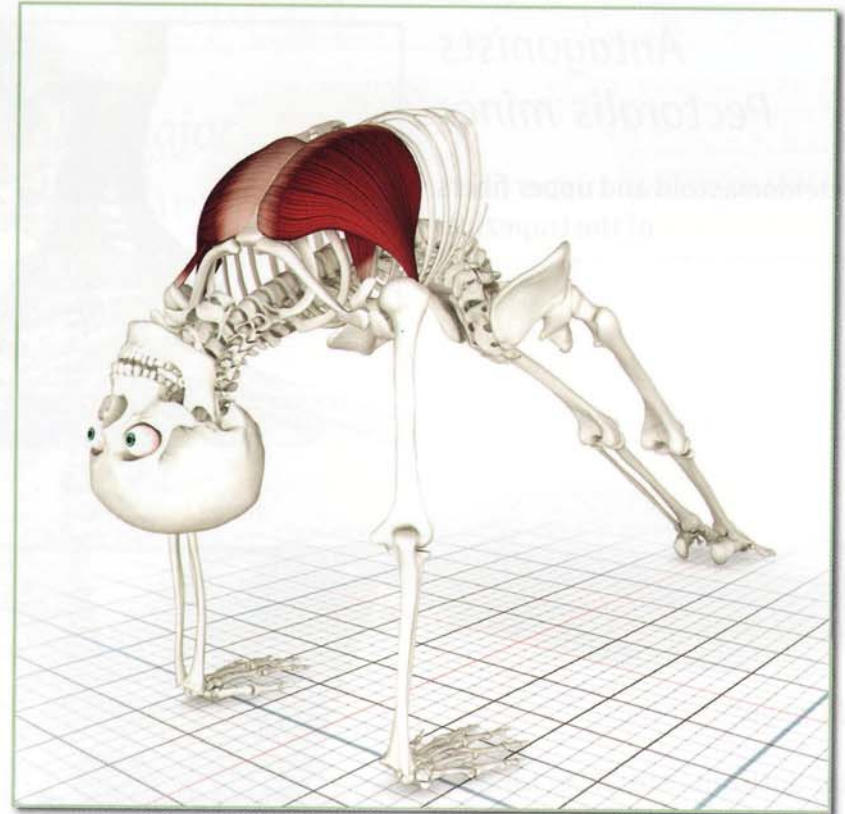
Flexes arm from an extended position.

Depresses arm and shoulder.

The pectoralis major and minor are stretched and awakened in purvottonasana.

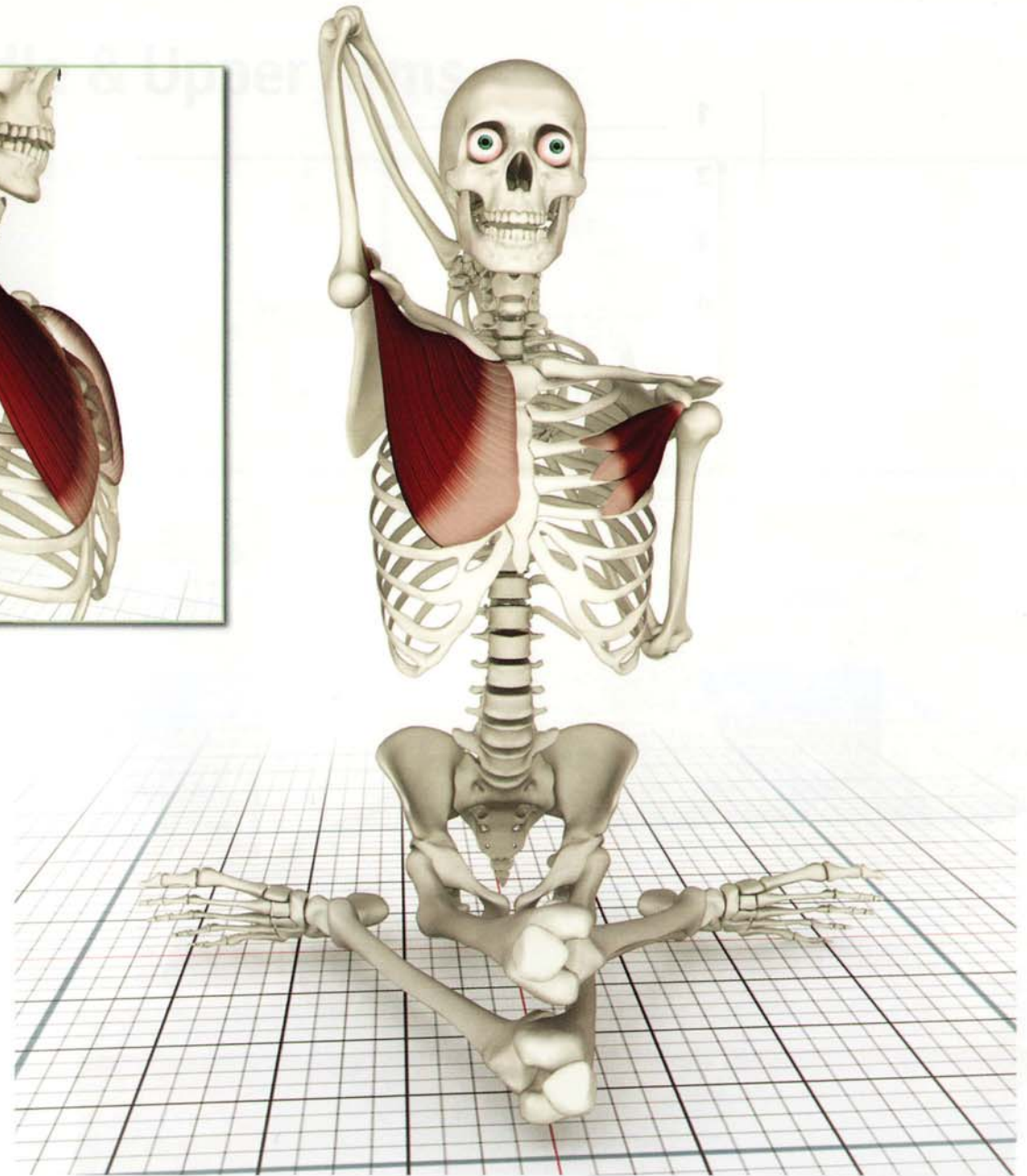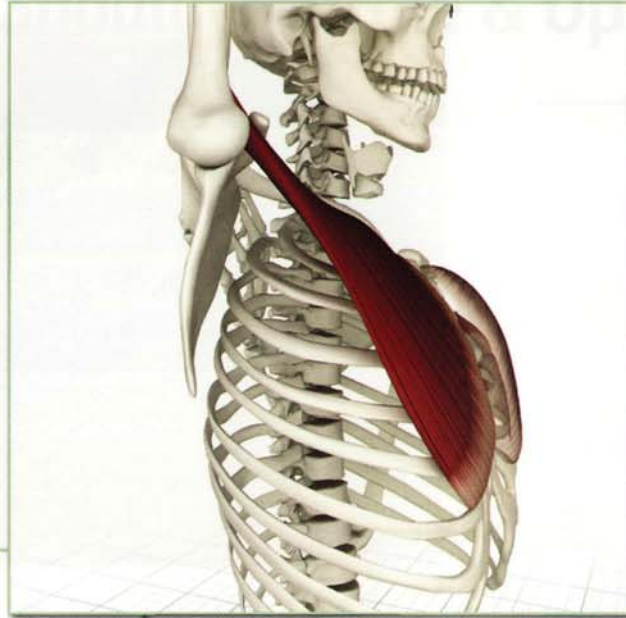
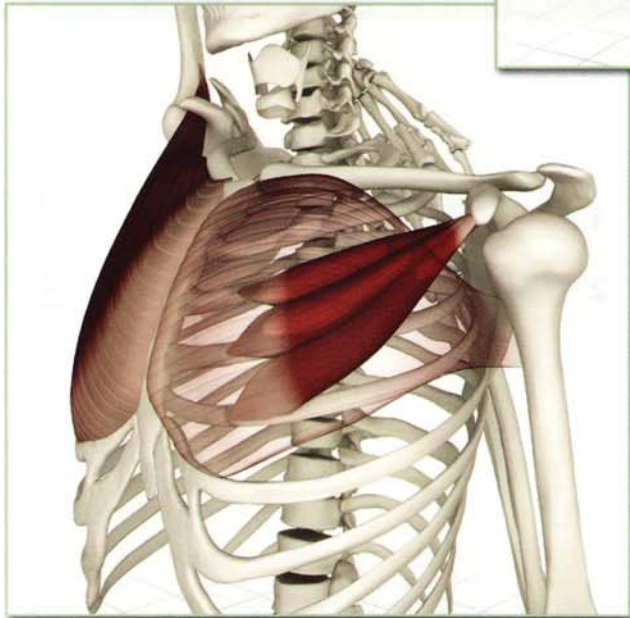
Awakening

Chaturanga Dandasana: The pectoralis major and minor (in association with the serratus anterior) stabilize the upper body in this pose.



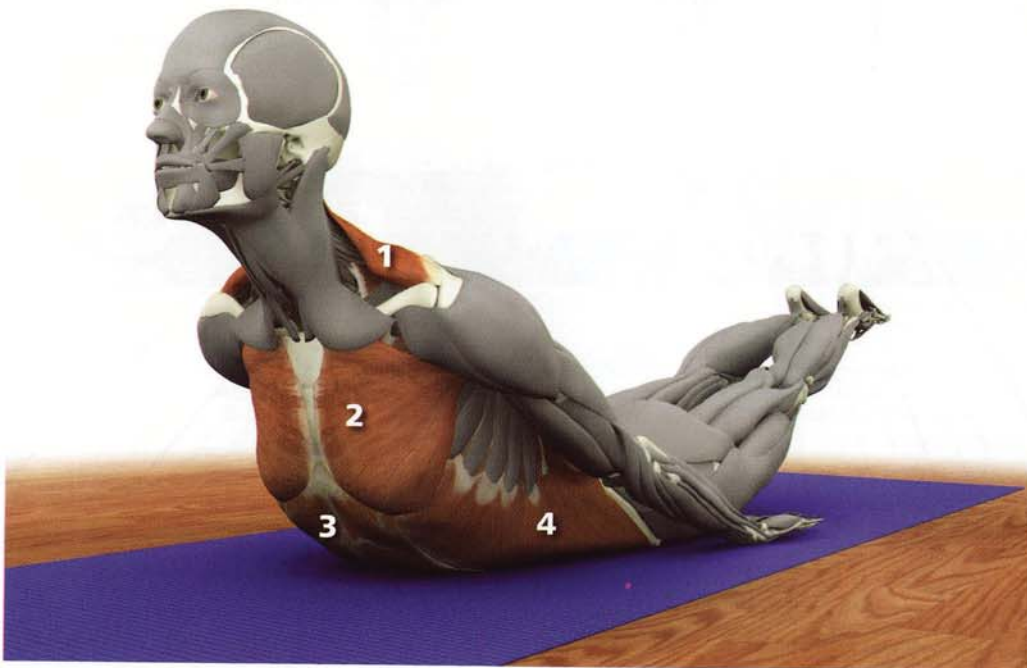

Stretched and Contracted

The upper arm stretches the lower fibers of the pectoralis major. The pectoralis minor contracts drawing the scapula of the lower arm forward. The rhomboids of the lower arm contract to stabilize the scapula, lifting the ribcage. Eccentrically contracting the upper arm pectoralis major facilitates this stretch (seen here in gomukhasana B).



Test your anatomy*

- 1 _____
- 2 _____
- 3 _____
- 4 _____



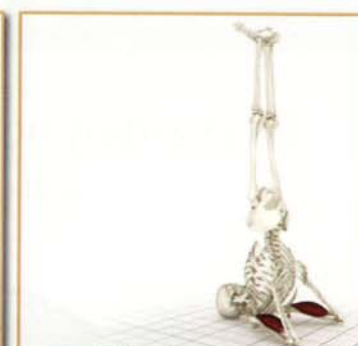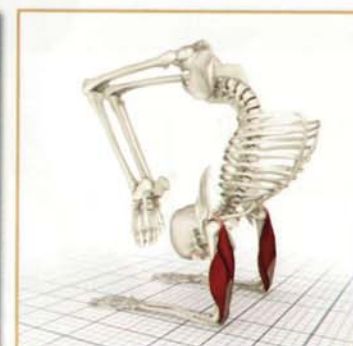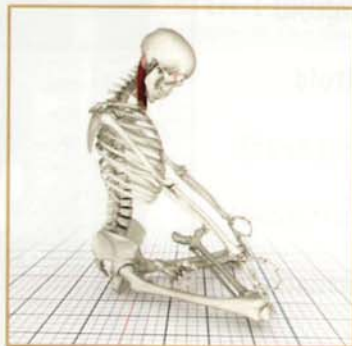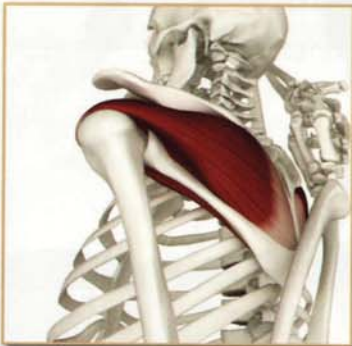
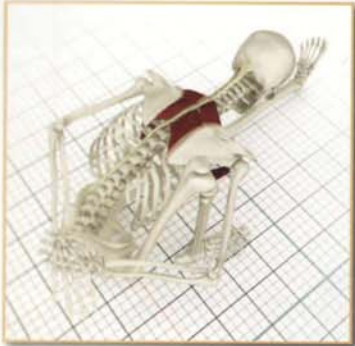- 1 _____
- 2 _____

**Please see www.bandhayoga.com for answers...*

Part Three

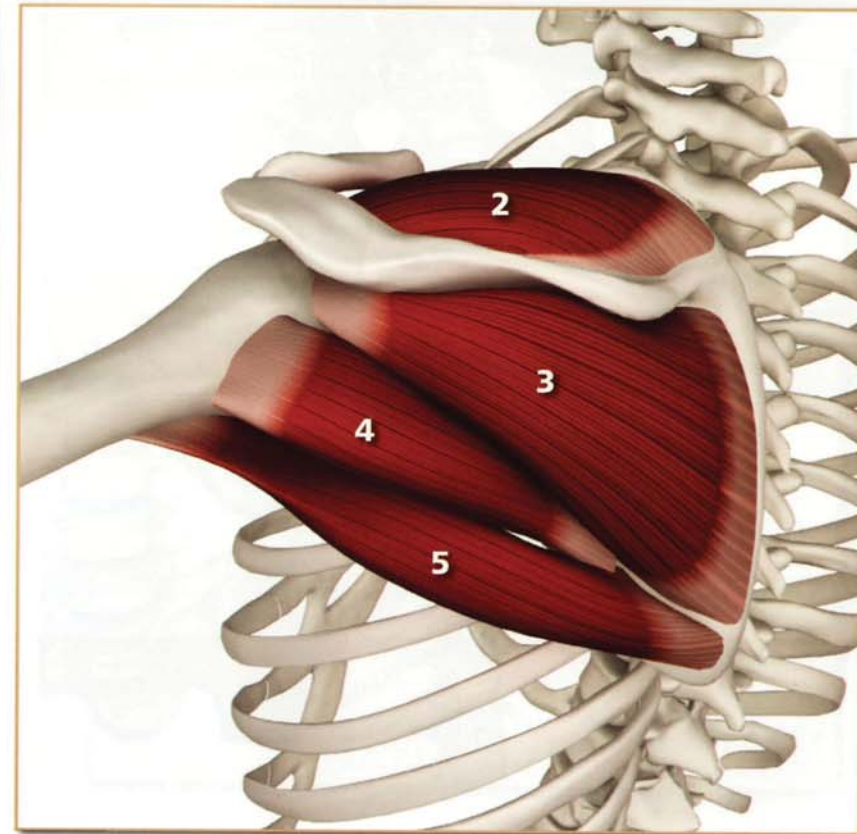
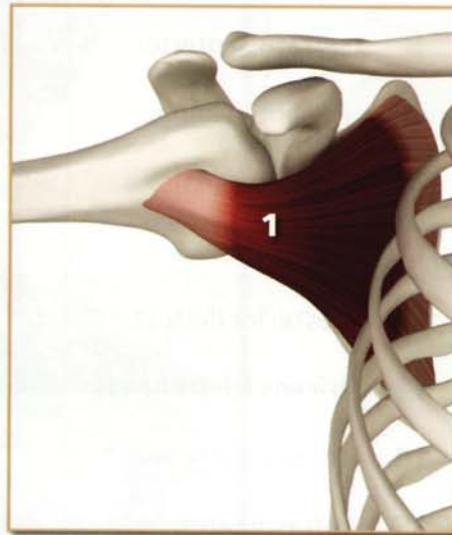
Shoulder Girdle & Upper Arms

Shoulder Girdle & Upper Arms

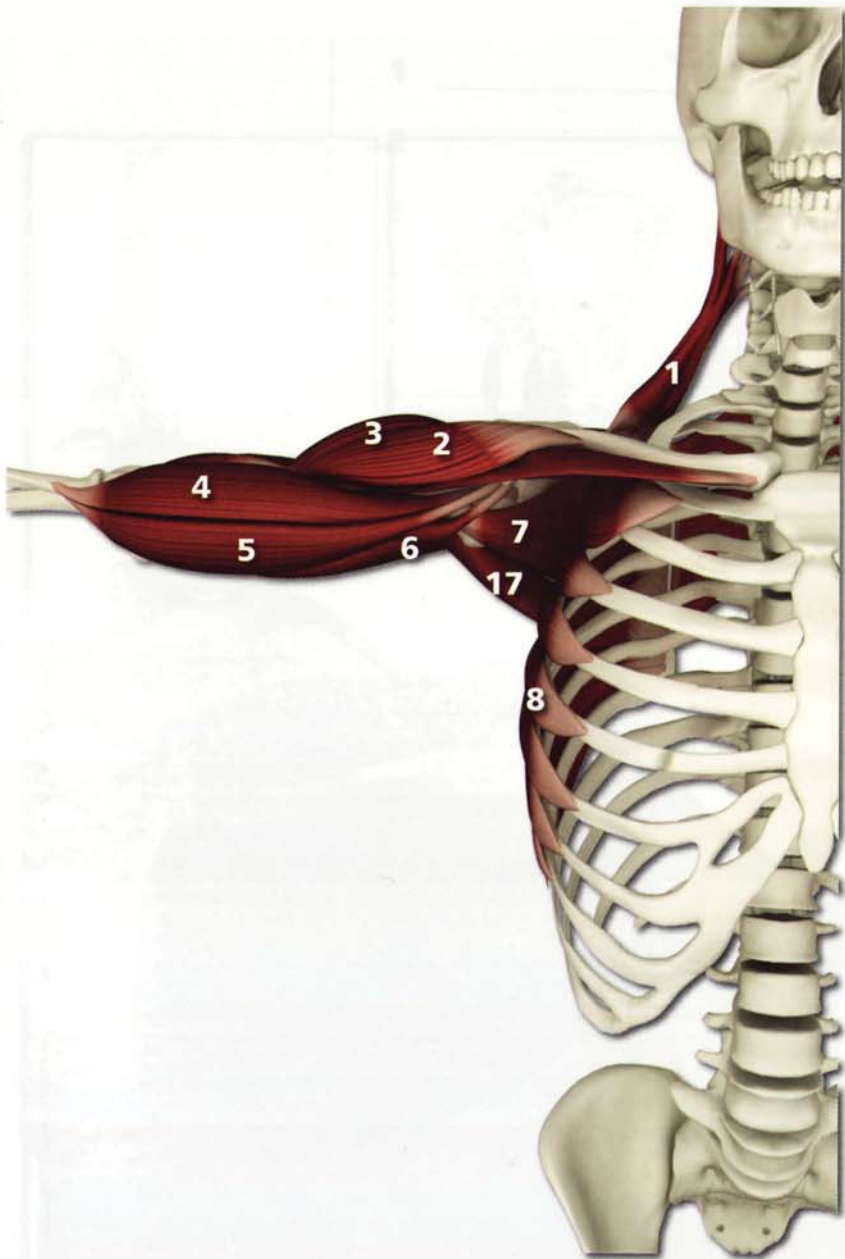


Rotator cuff

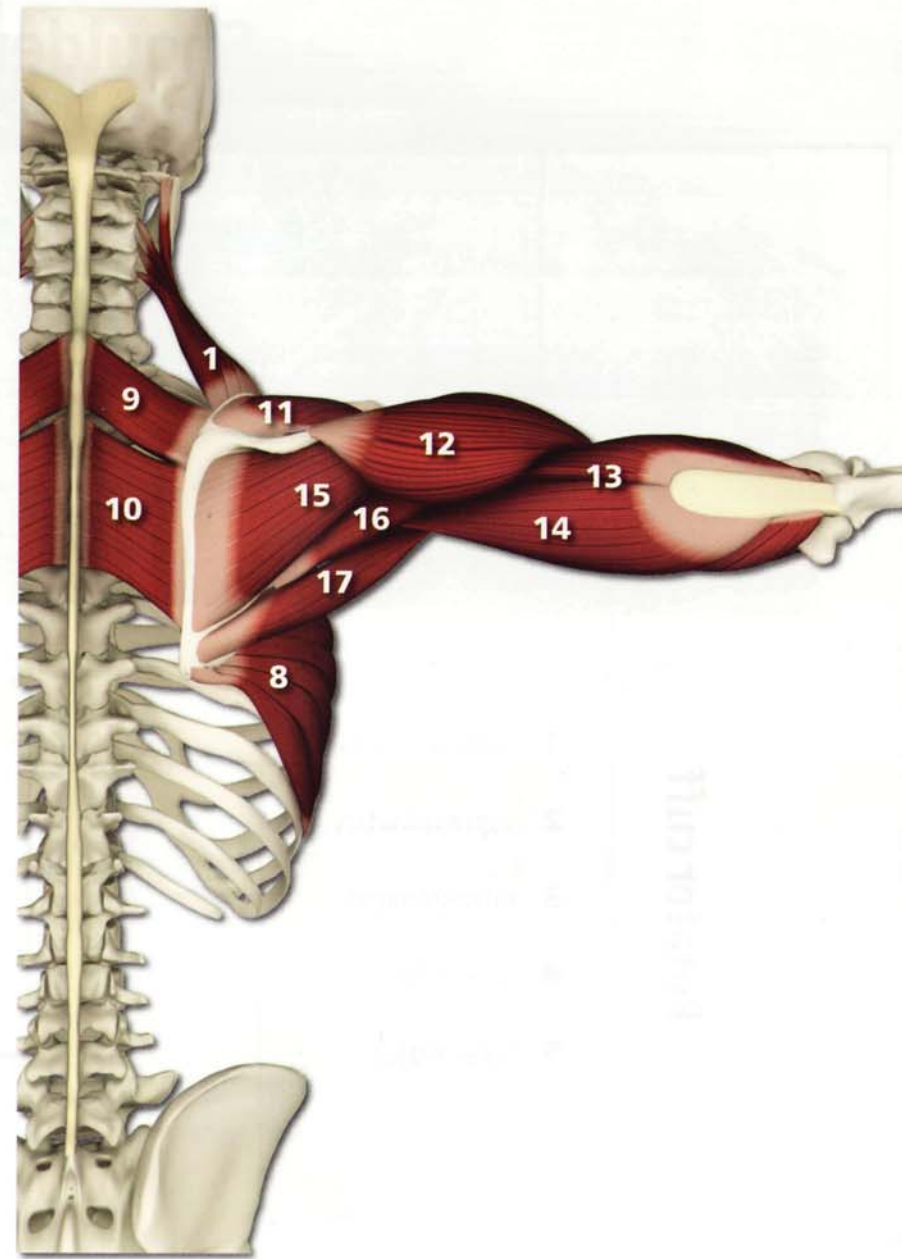
- 1 subscapularis
- 2 supraspinatus
- 3 infraspinatus
- 4 teres minor
- 5 teres major




Shoulder Girdle & Upper Arms



- 1** levator scapulae
- 2** anterior deltoid
- 3** lateral deltoid
- 4** biceps (long head)
- 5** biceps (short head)
- 6** coracobrachialis
- 7** subscapularis
- 8** serratus anterior
- 9** rhomboid minor
- 10** rhomboid major
- 11** supraspinatus
- 12** posterior deltoid
- 13** triceps (short head)
- 14** triceps (long head)
- 15** infraspinatus
- 16** teres minor
- 17** teres major

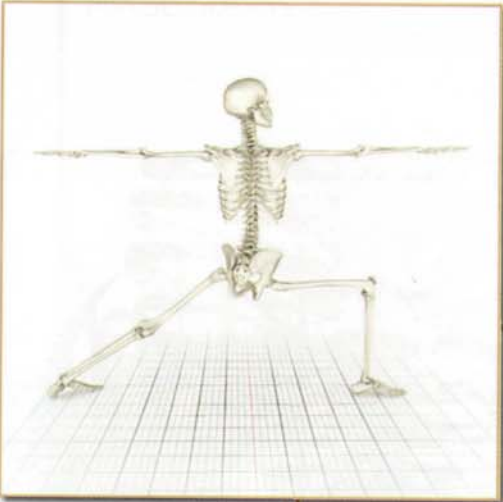


Movement: Scapula



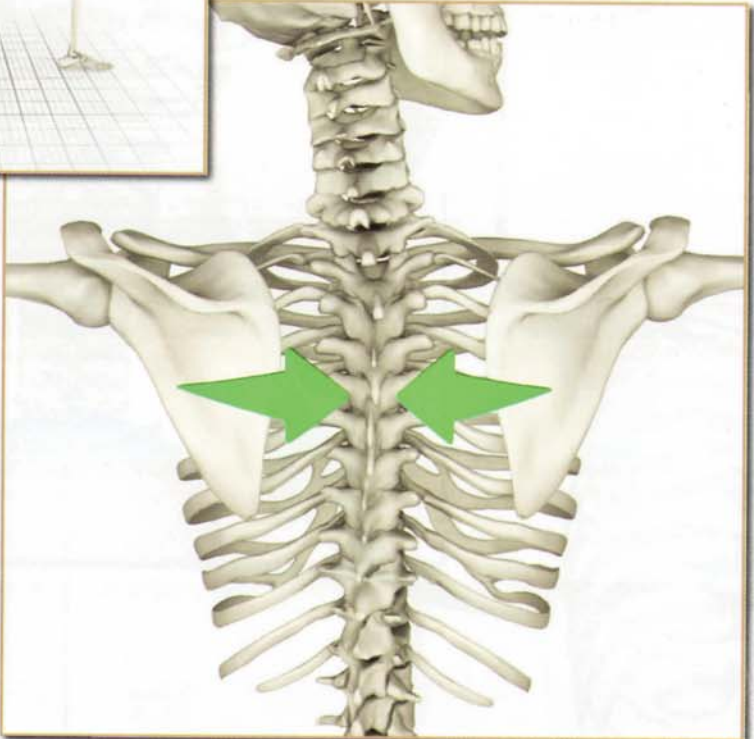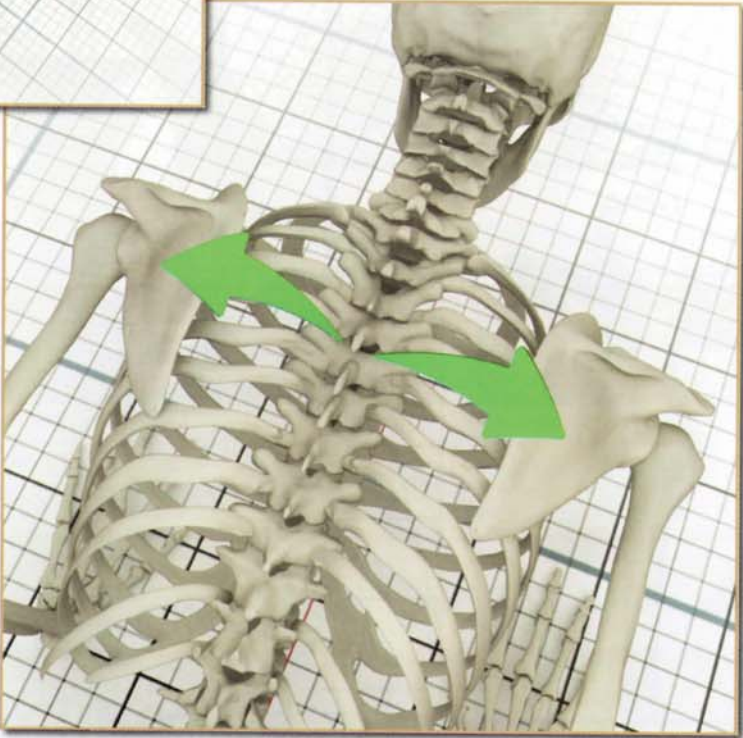Abduction (protraction)

Chataranga Dandasana



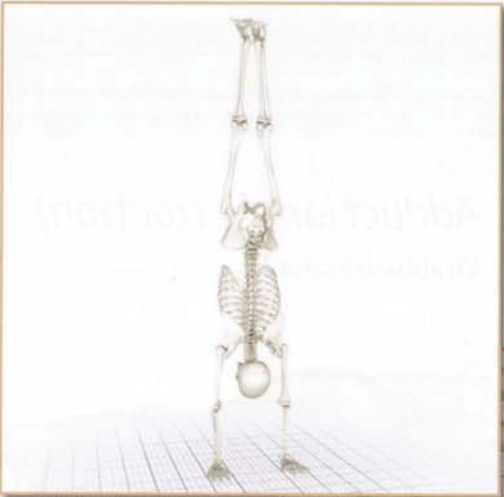Adduction (retraction)

Virabhadrasana II

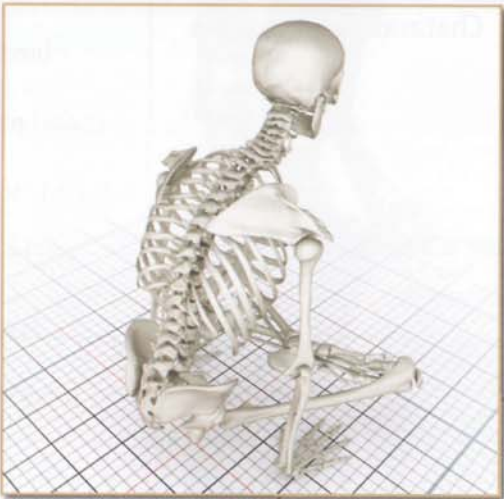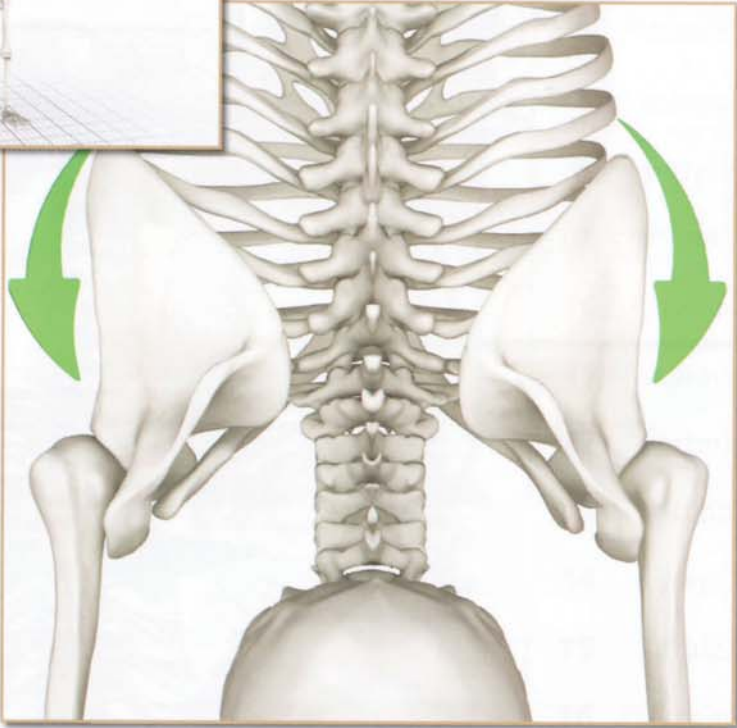


Shoulder Girdle & Upper Arms

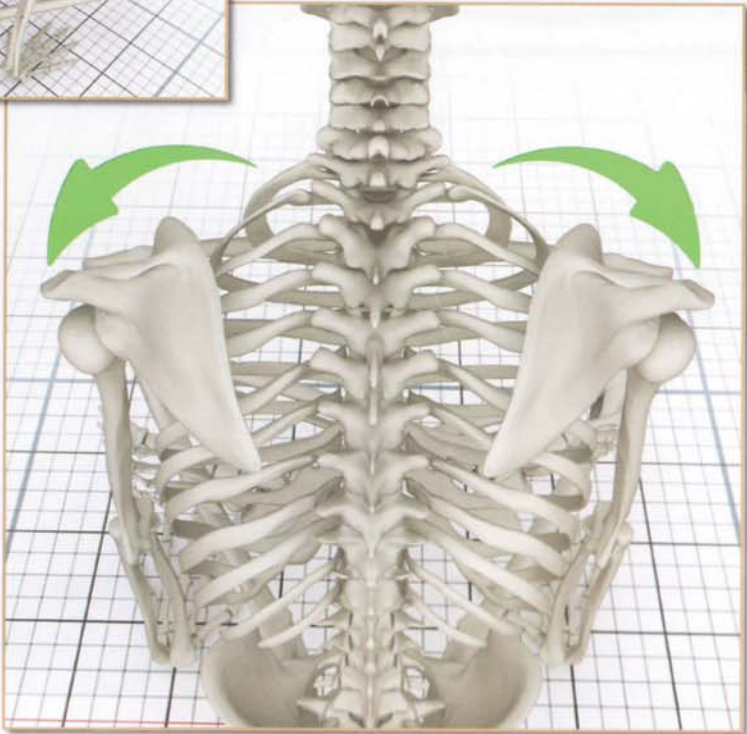
Movement: Scapula



*Upward
Rotation*
Adho Mukha Vrksasana

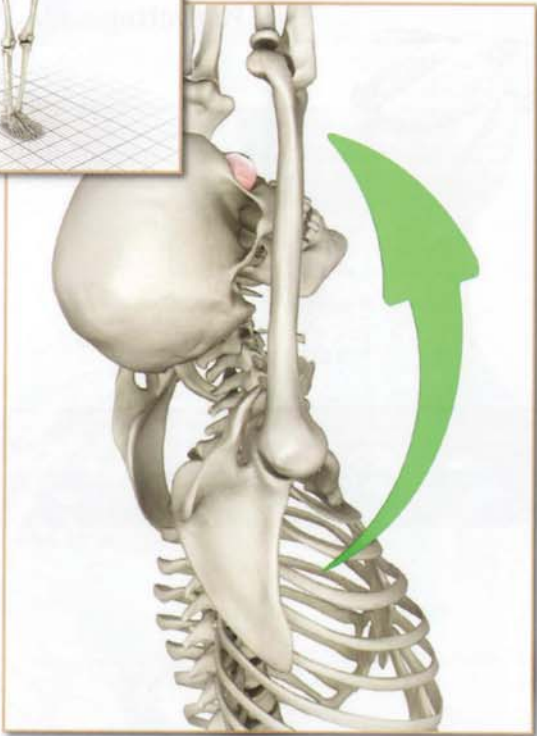
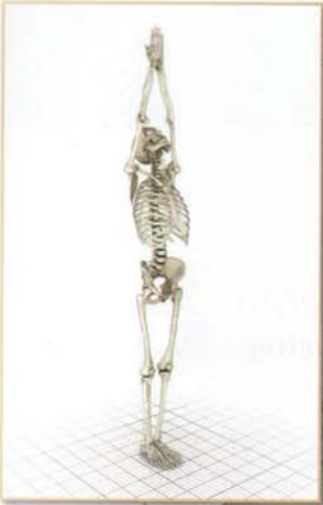
*Downward
Rotation*
Tolasana

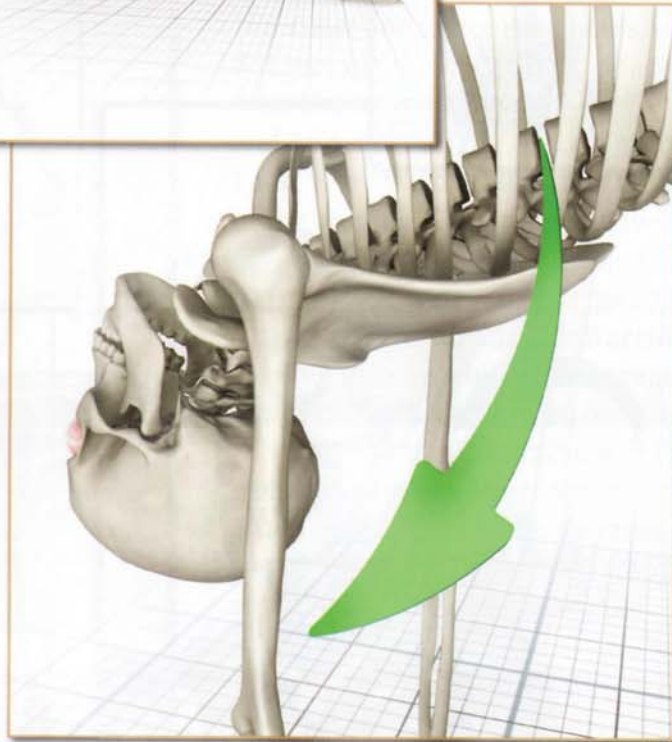


Movement: Upper Arm

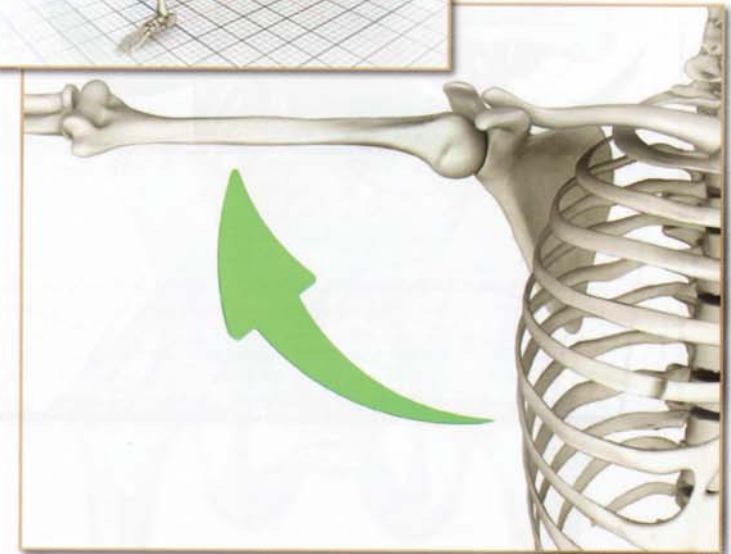
Flexion
Tadasana



Extension
Purvotttonasana

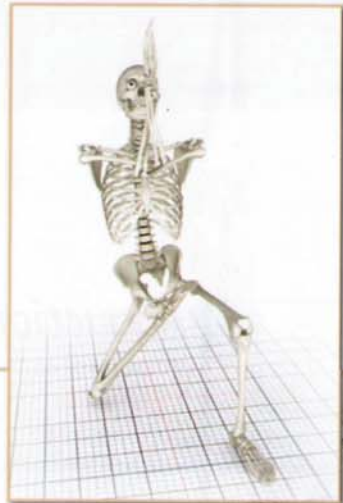

Abduction
Virabhadrasana II

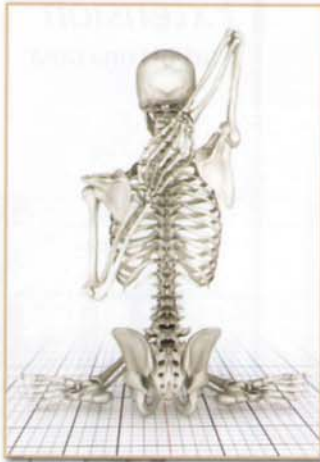

Shoulder Girdle & Upper Arms

Movement: Upper Arm



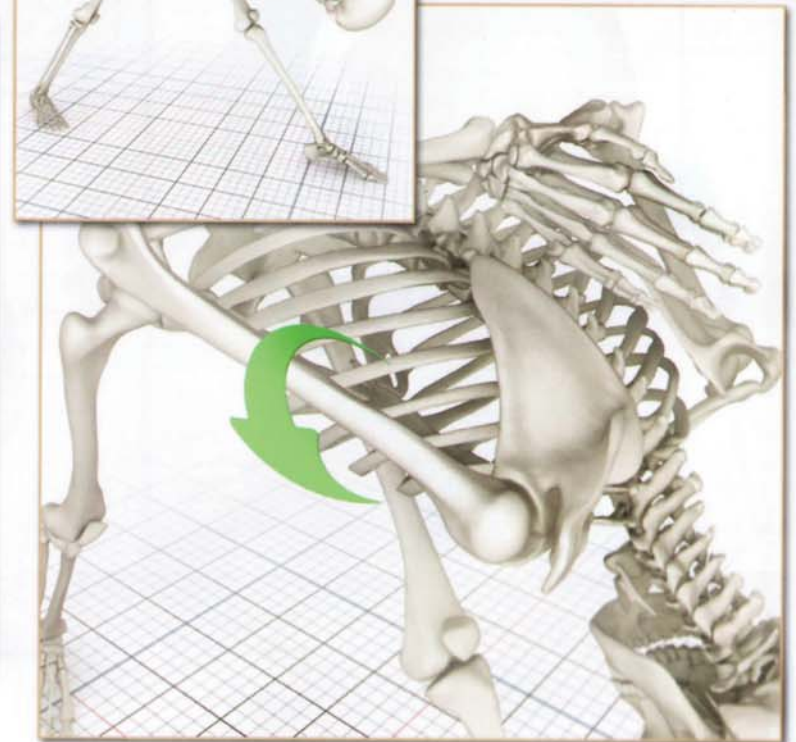
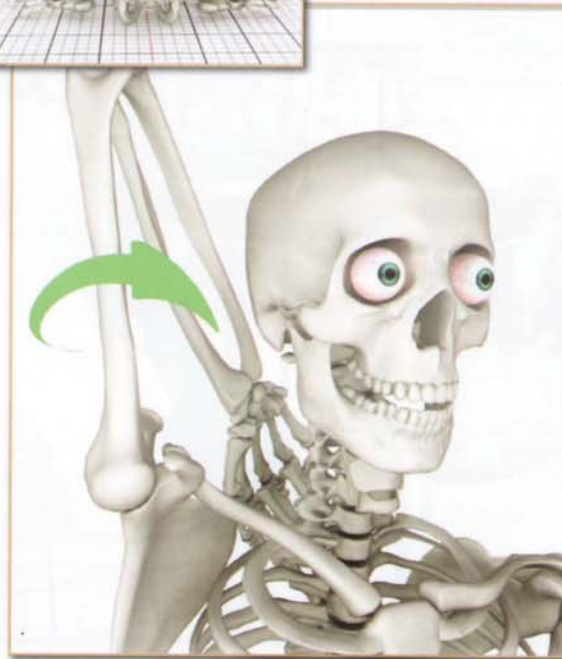
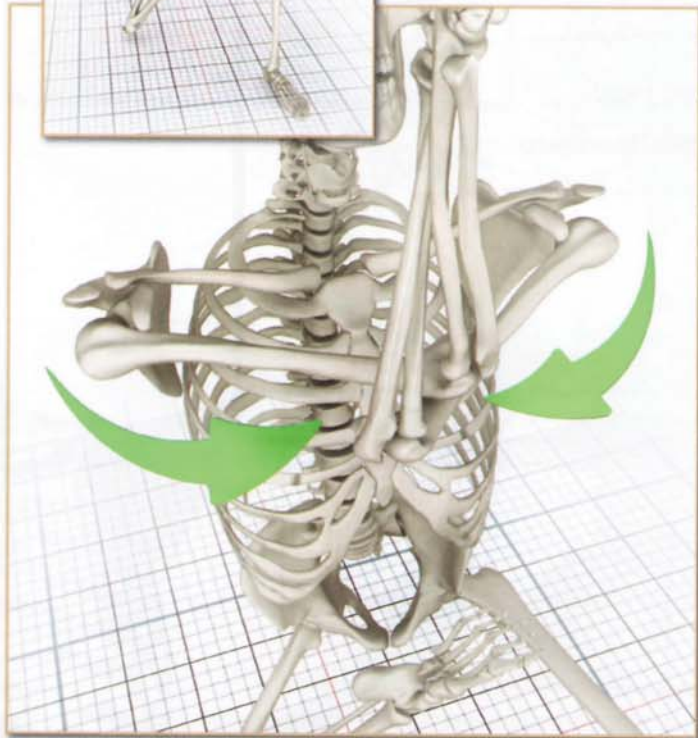
Adduction
Vatayanasana



External Rotation
Gomukhasana B

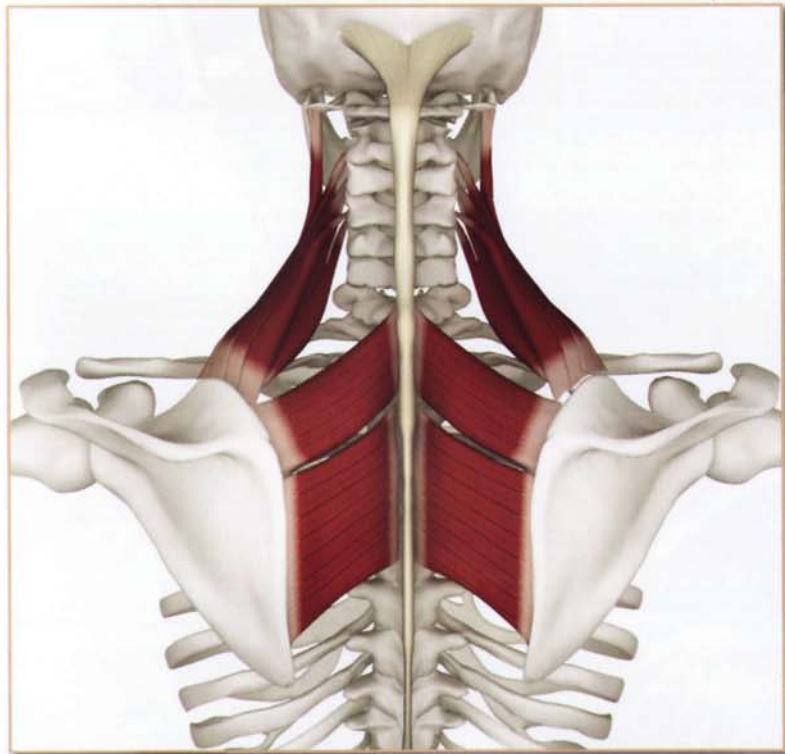


Internal Rotation
Parsvotthanasana



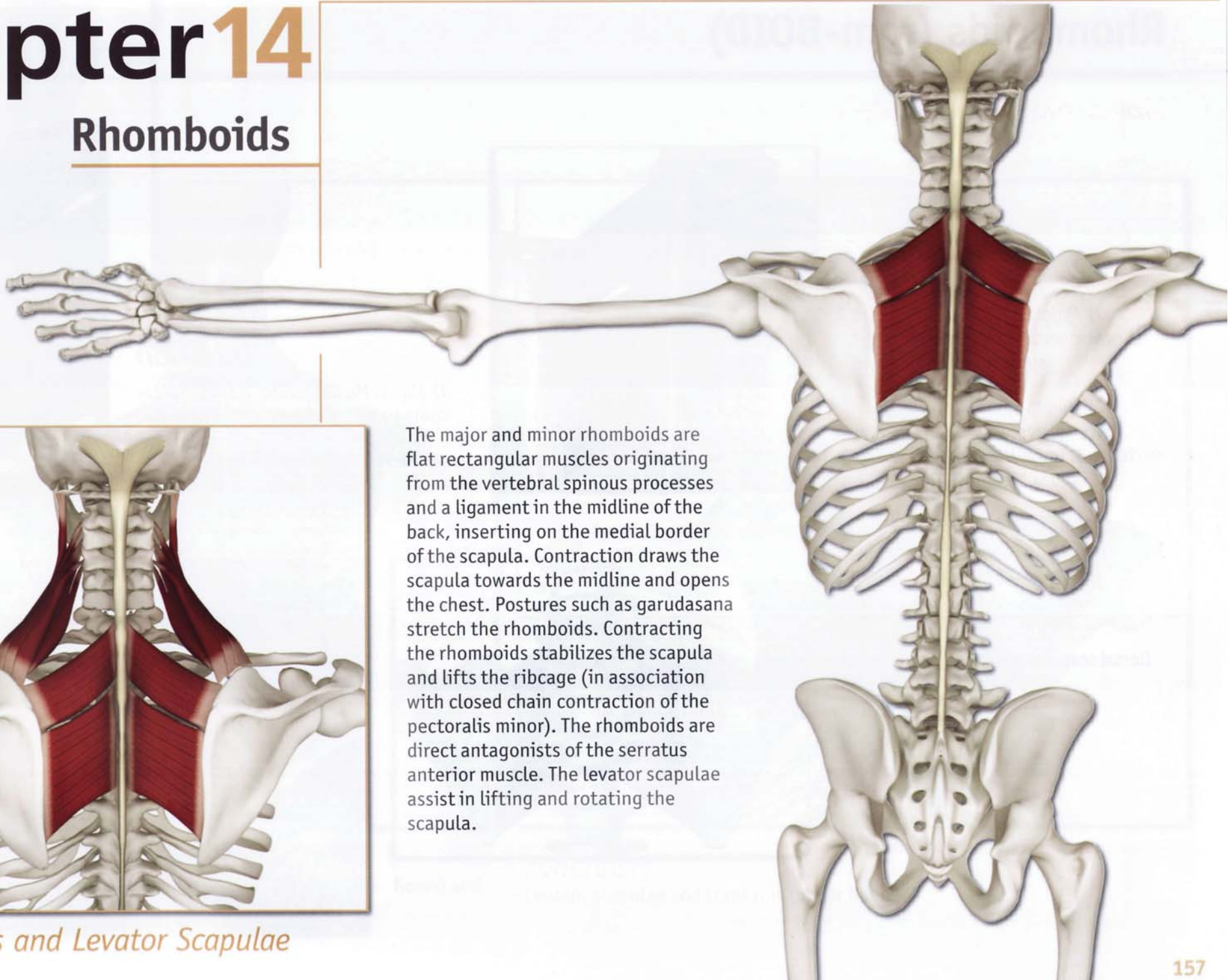
Chapter 14

Rhomboids



Rhomboids and Levator Scapulae

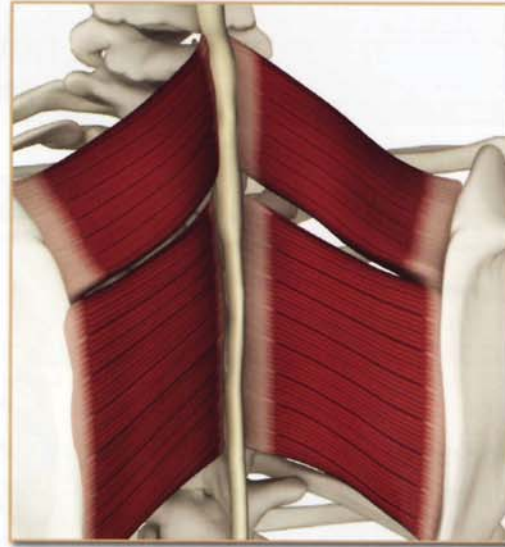
The major and minor rhomboids are flat rectangular muscles originating from the vertebral spinous processes and a ligament in the midline of the back, inserting on the medial border of the scapula. Contraction draws the scapula towards the midline and opens the chest. Postures such as garudasana stretch the rhomboids. Contracting the rhomboids stabilizes the scapula and lifts the ribcage (in association with closed chain contraction of the pectoralis minor). The rhomboids are direct antagonists of the serratus anterior muscle. The levator scapulae assist in lifting and rotating the scapula.



Rhomboids (rom-BOID)

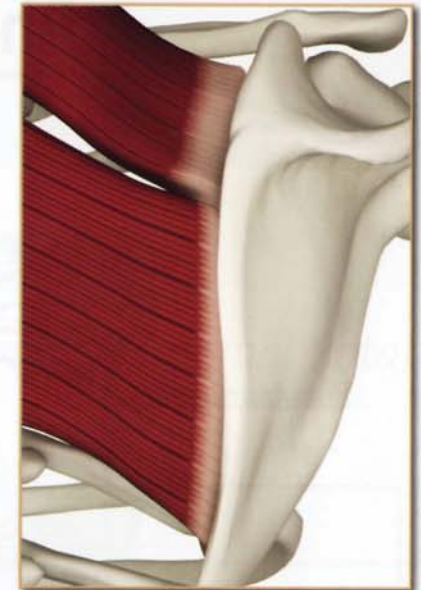
Origin

- 1) *Major*: Spinous processes of thoracic vertebrae 2 through 5 and supraspinous ligament.
- 2) *Minor*: Spinous processes of cervical vertebra 7 and thoracic vertebra 1, lower ligamentum nuchae and supraspinous ligament.



Insertion

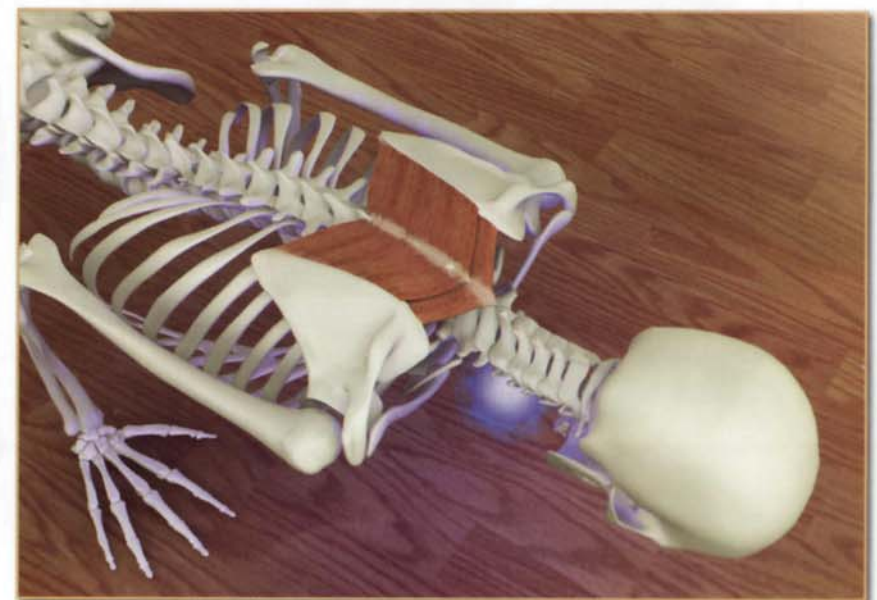
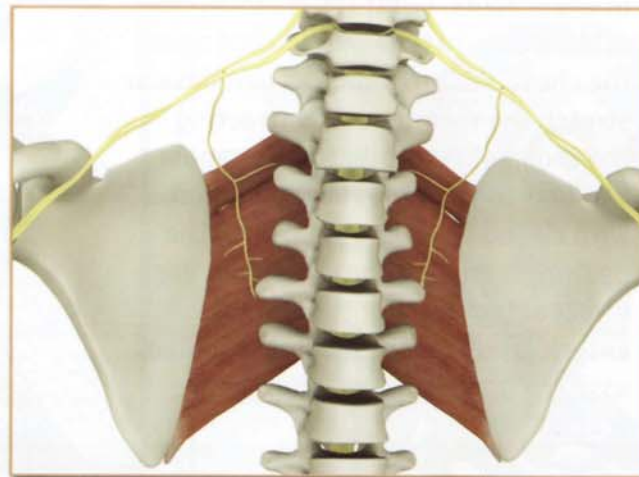
- 1) *Major*: Medial border from scapular spine to inferior angle of the scapula.
- 2) *Minor*: Upper medial border of the scapula.

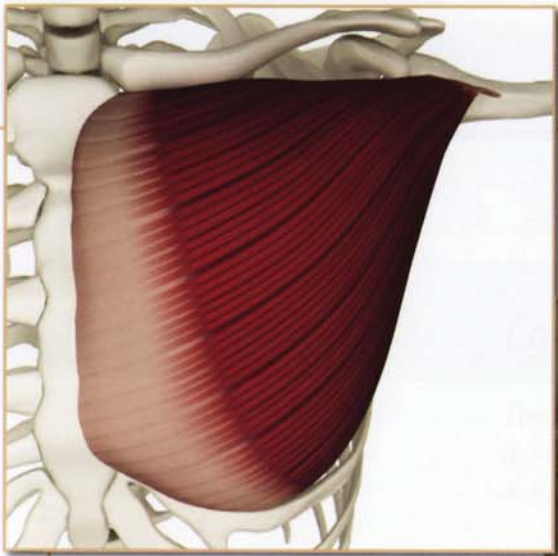


Innervation & chakra illuminated

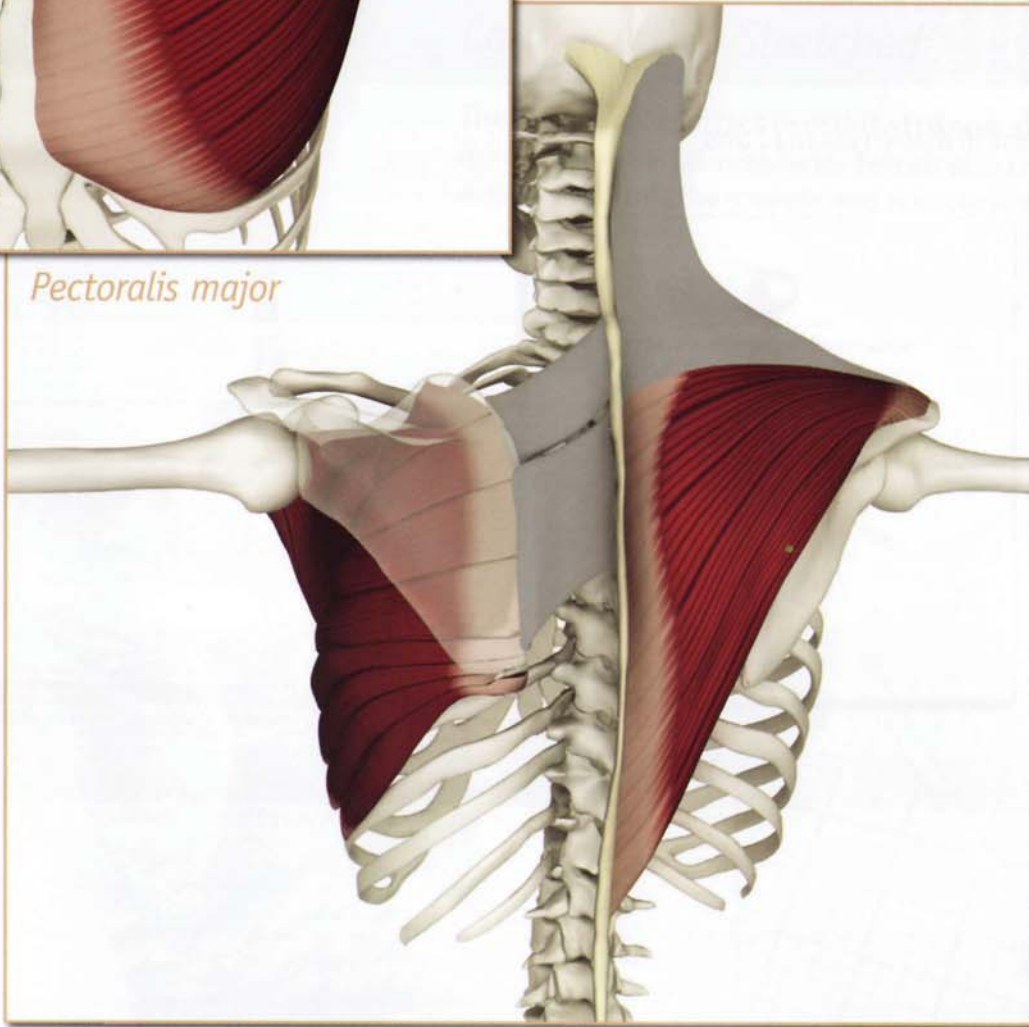
Dorsal scapular nerve (cervical nerve 5).

Chakra illuminated: Fifth



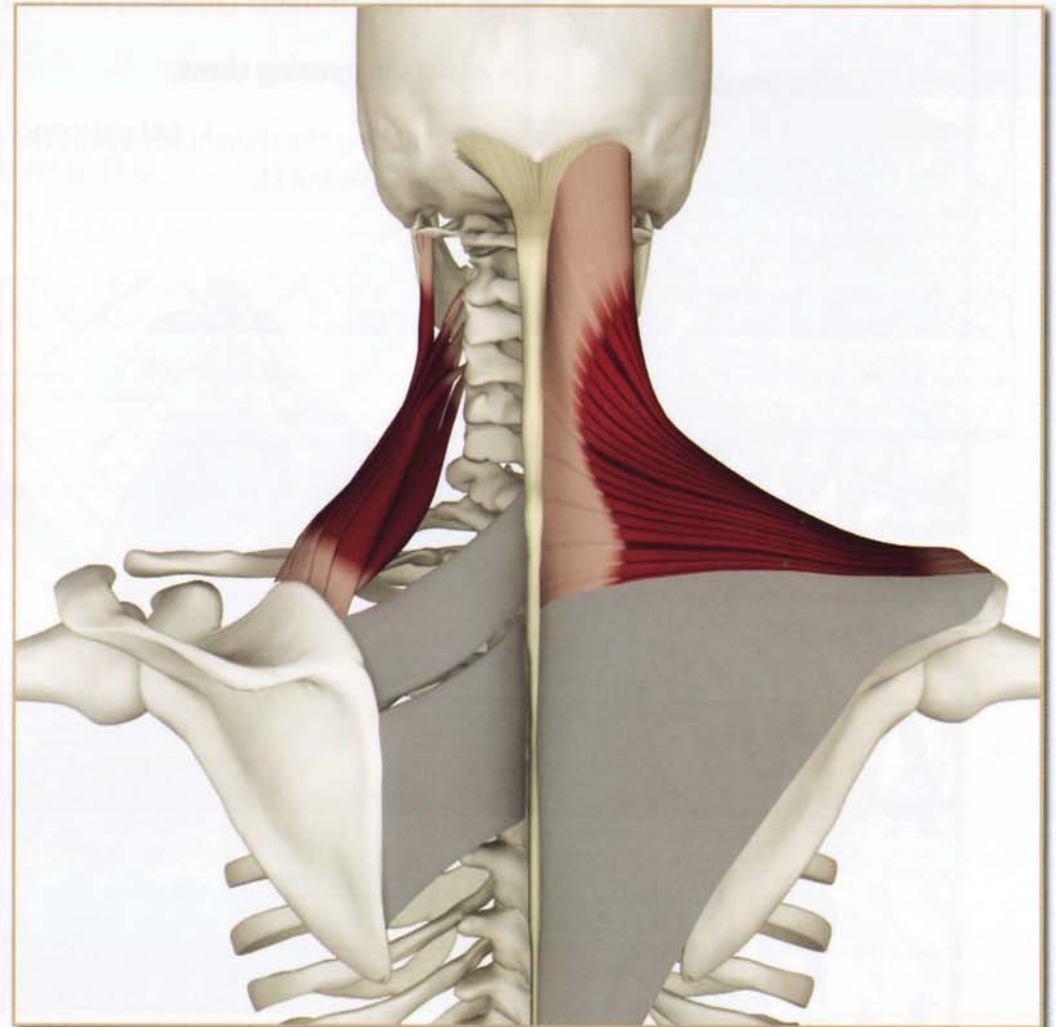


Pectoralis major



Antagonists

Serratus anterior (seen here through the scapula), trapezius (lower fibers) and pectoralis major (sternocostal portion - see inset above).



Synergists

Levator scapulae and trapezius (upper fibers).

Rhomboids (rom-BOID)

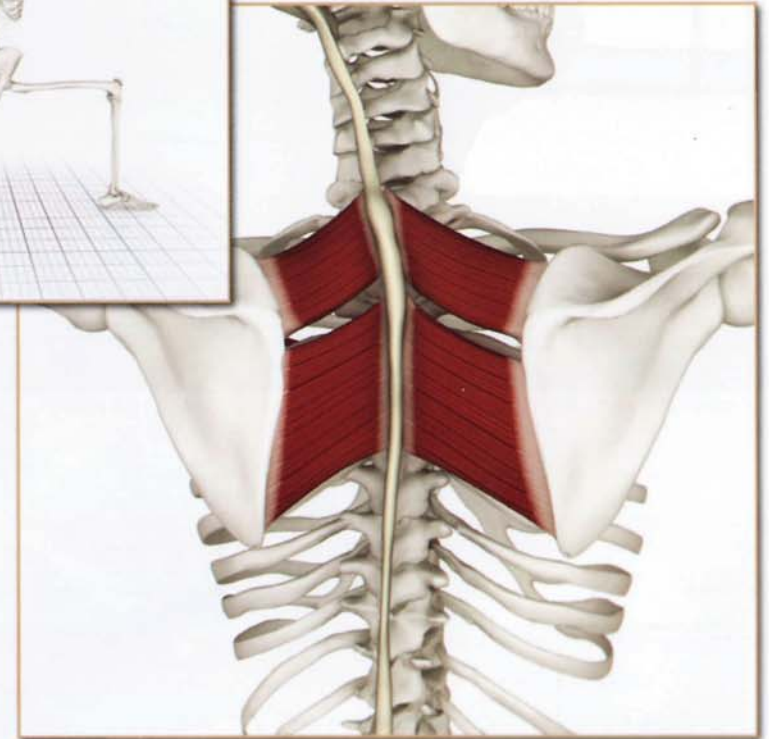

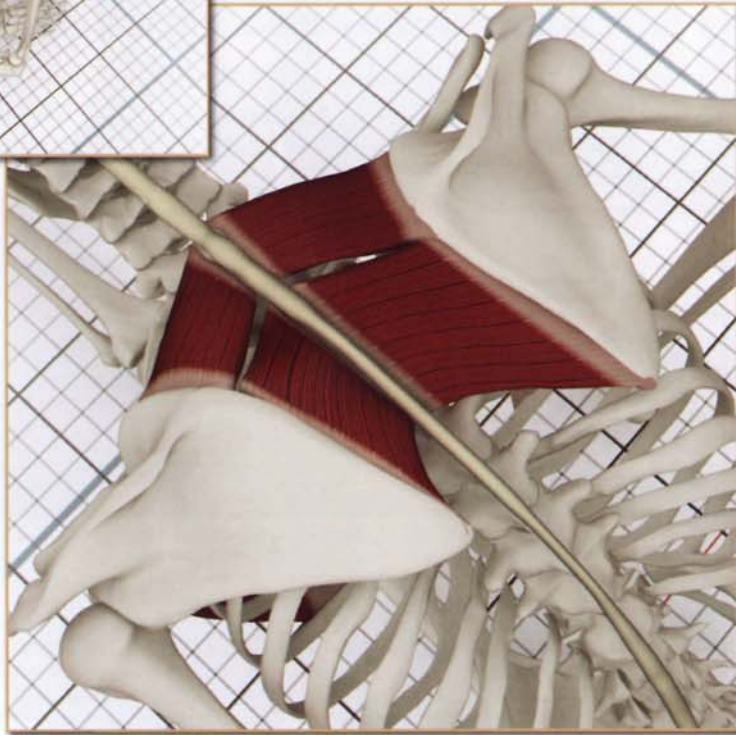


Action

Stabilizes, retracts (adducts) and rotates scapula downward.

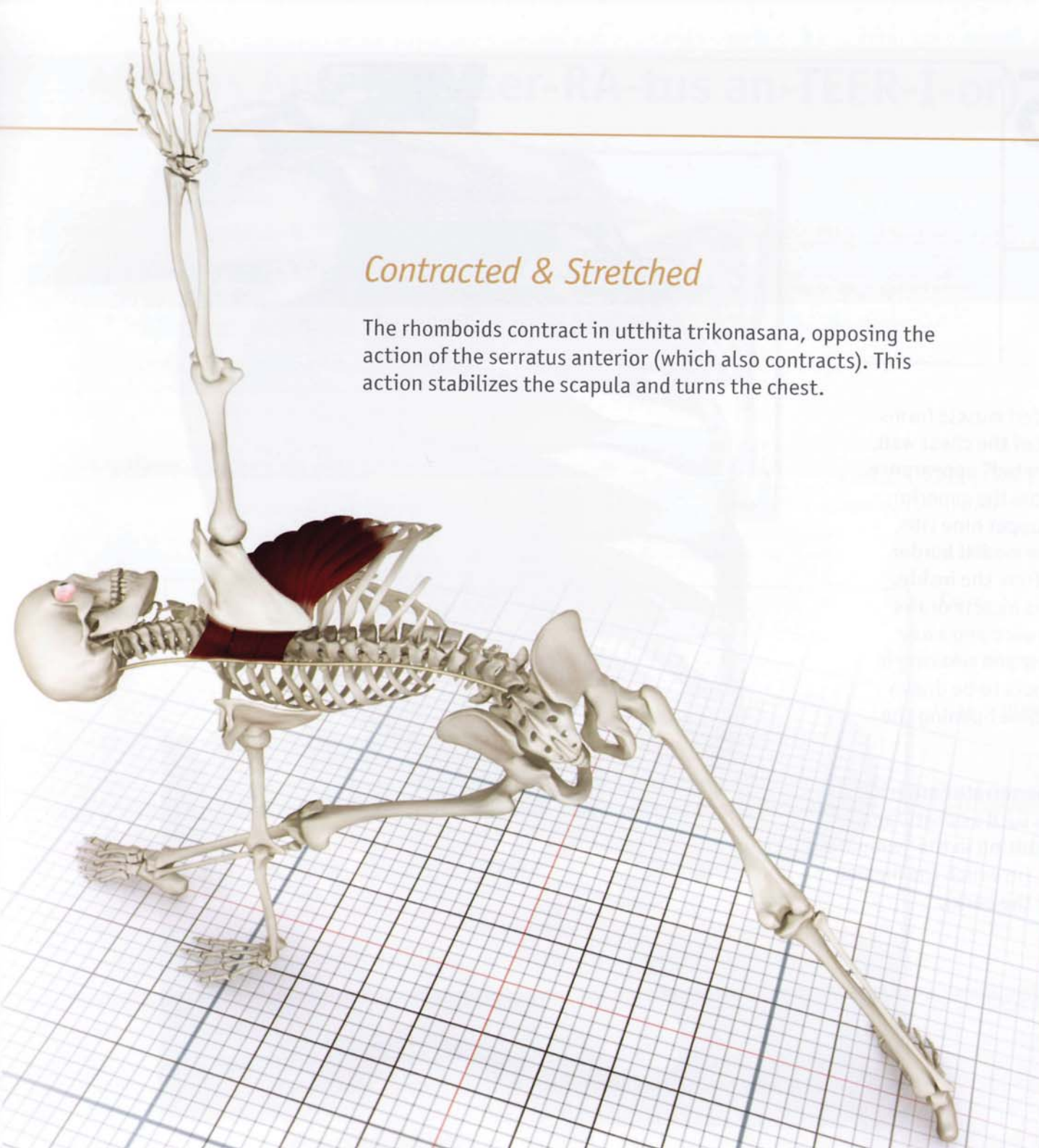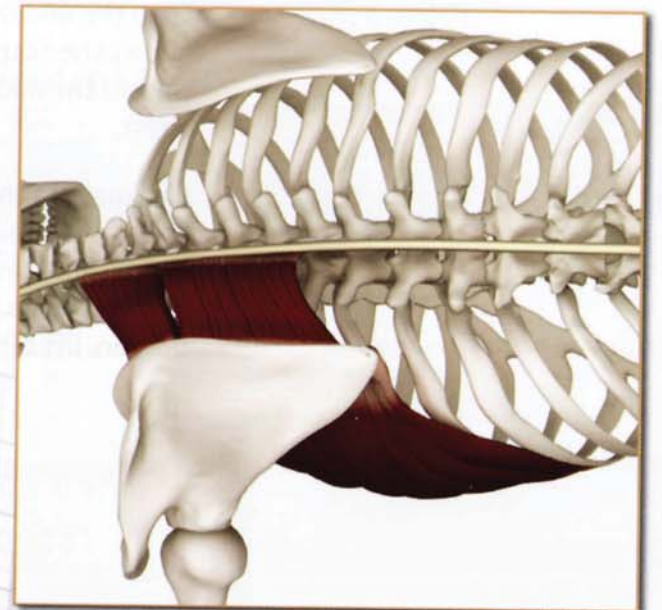
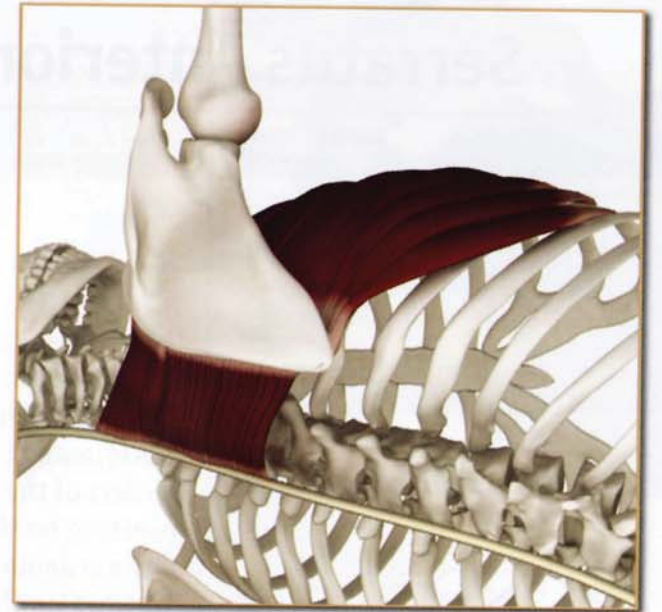
Assists in opening chest.

Contracting the rhomboids opens the chest in marichyasana I and virabhadrasana II.



Contracted & Stretched

The rhomboids contract in utthita trikonasana, opposing the action of the serratus anterior (which also contracts). This action stabilizes the scapula and turns the chest.

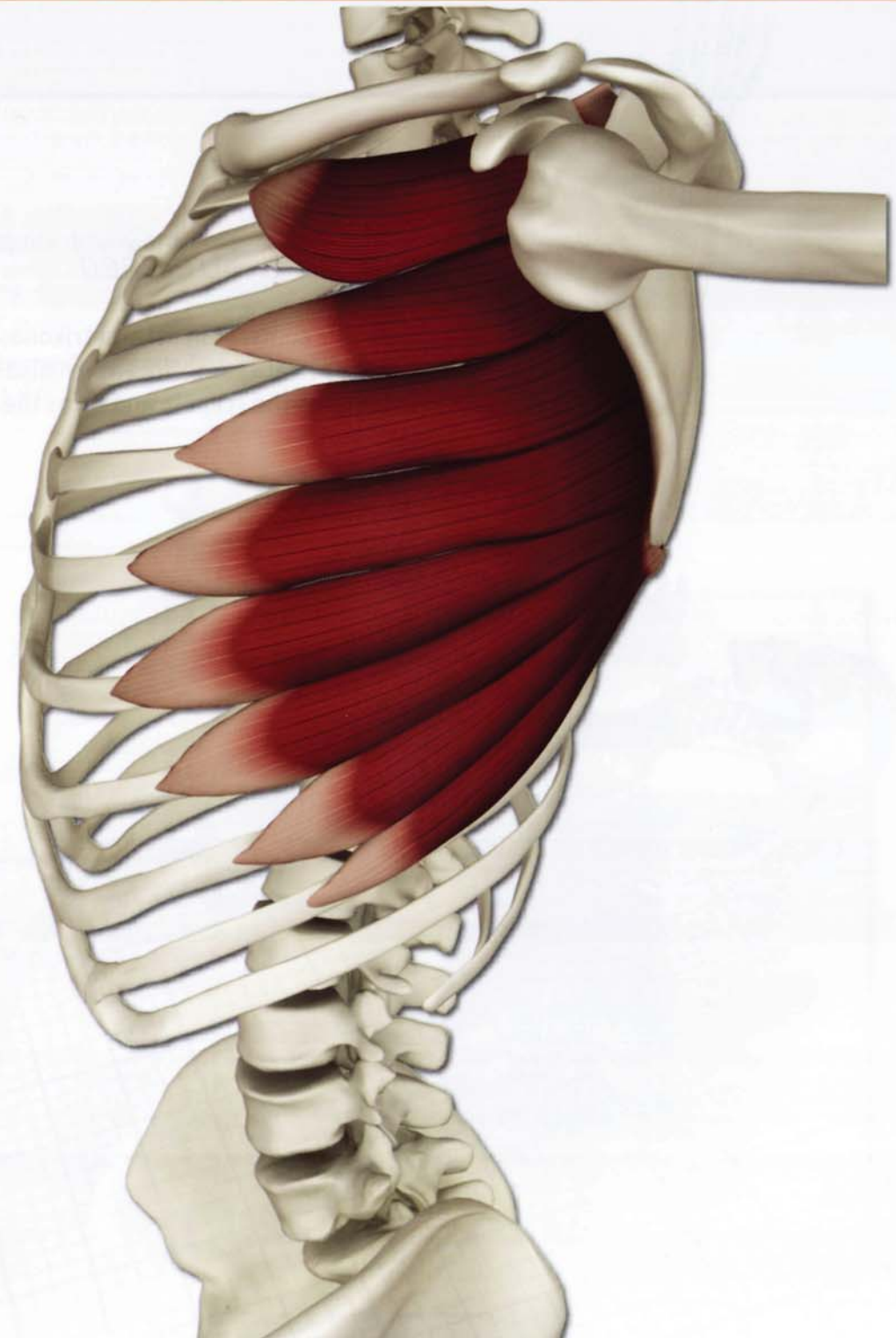


Chapter 15

Serratus Anterior

This multi-headed muscle forms the lateral part of the chest wall, giving it a “serrated” appearance. It originates from the superior borders of the upper nine ribs, inserting on the medial border of the scapula from the inside. Contracting this muscle draws the scapula forward and away from the midline and relaxing it allows the scapula to be drawn toward the midline opening the chest.

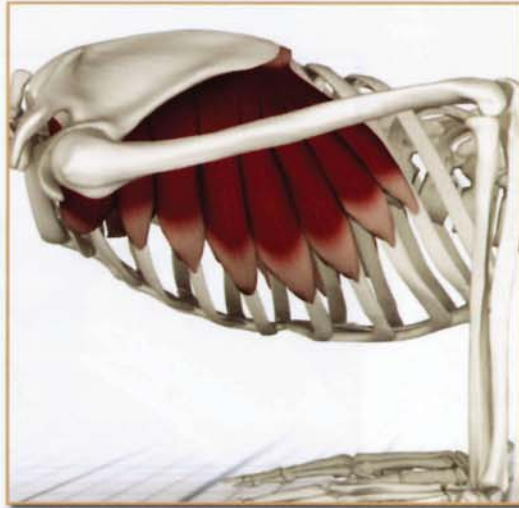Weakness in the serratus anterior limits postures such as chaturanga dandasana, resulting in the “winging” of the scapula, (in which the medial borders lift off the back).



Serratus Anterior (ser-RA-tus an-TEER-I-or)

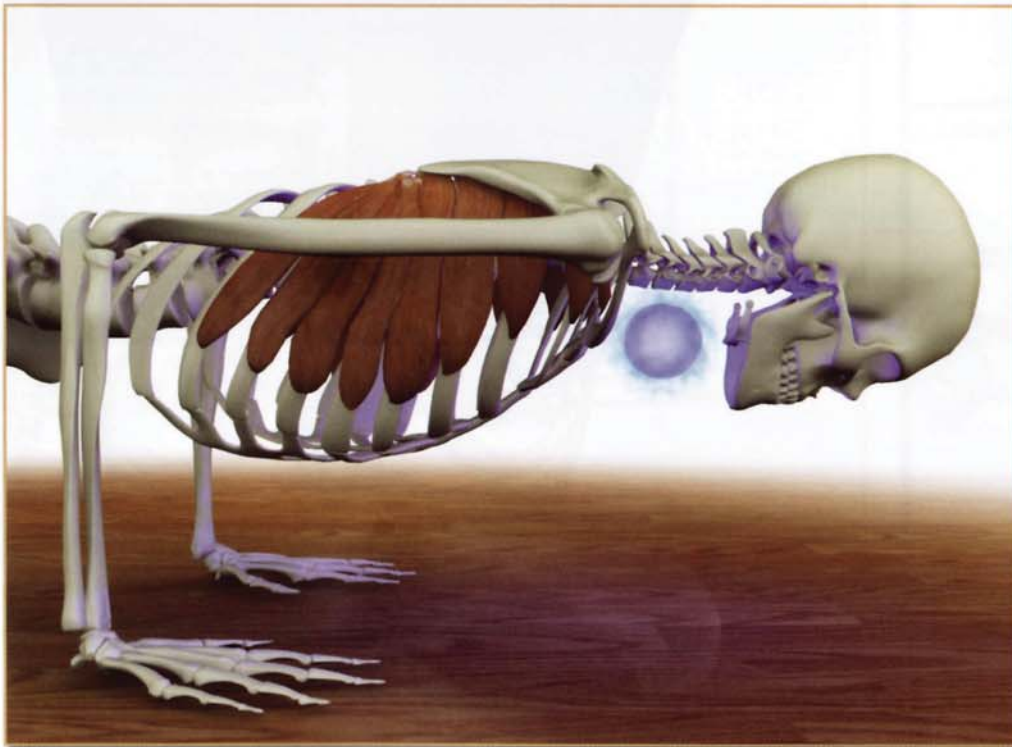
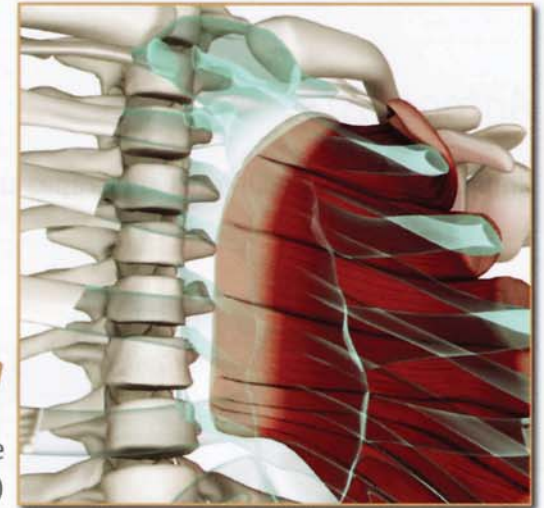
Origin

Outer surfaces and superior borders of ribs 1 through 9.



Insertion

Costal aspect of medial border of the scapula. (seen here through the chest)



Innervation & chakra illuminated

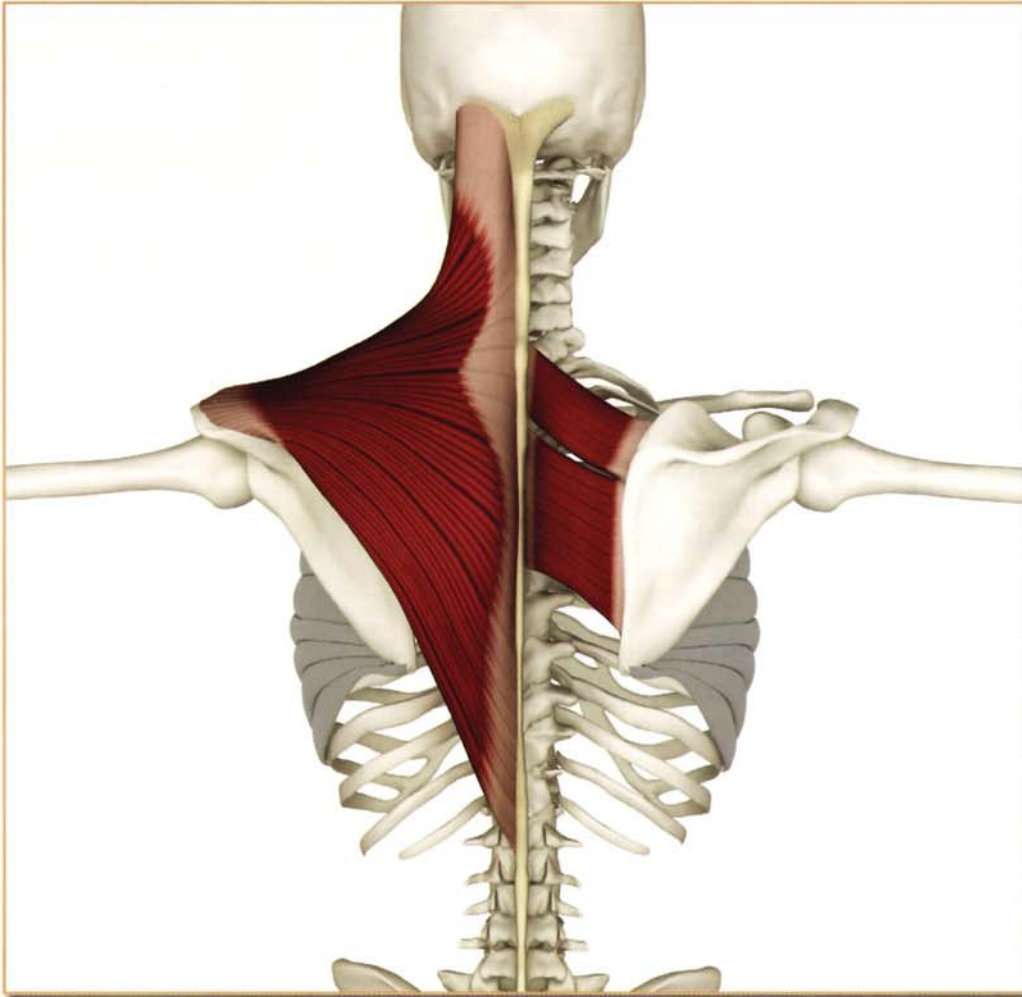
Long thoracic nerve (cervical nerves 5, 6 and 7).

Chakra illuminated: Fifth

Serratus Anterior (ser-RA-tus an-TEER-I-or)

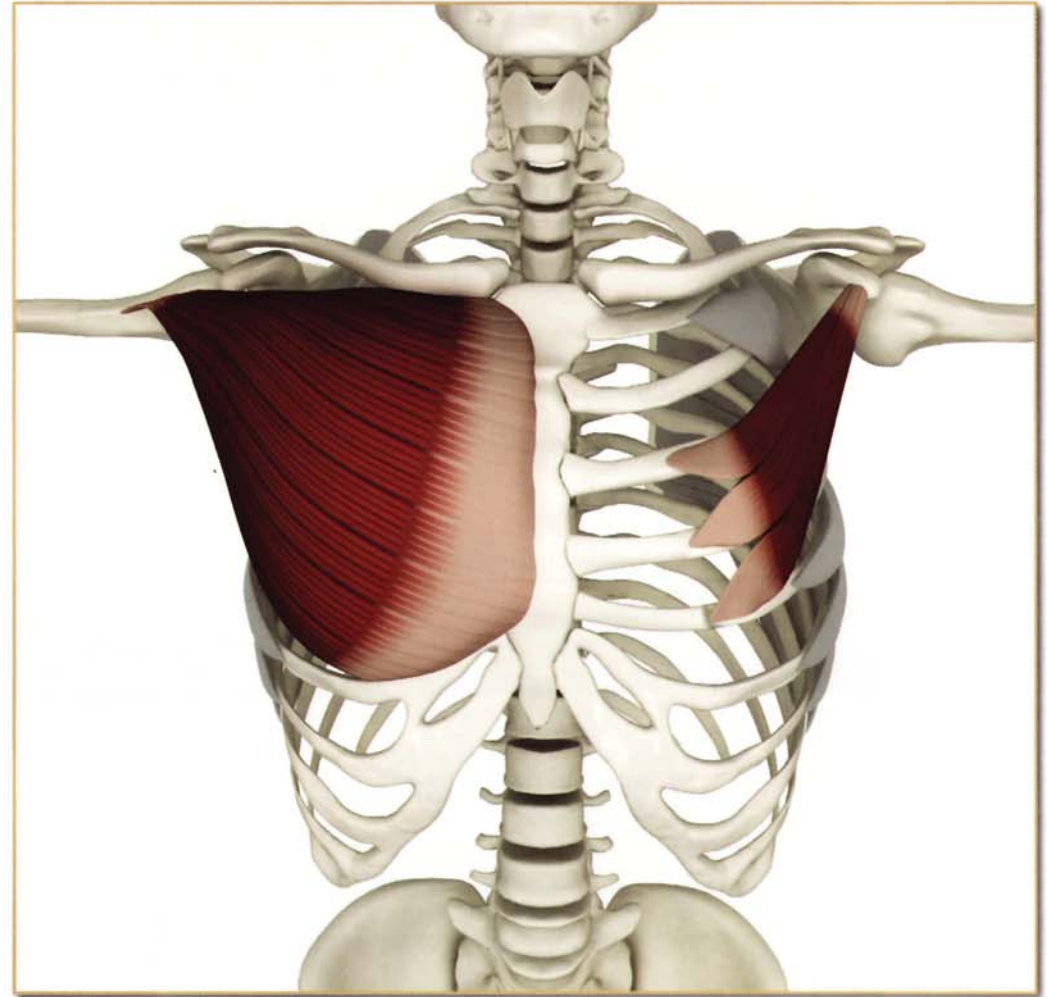
Antagonists

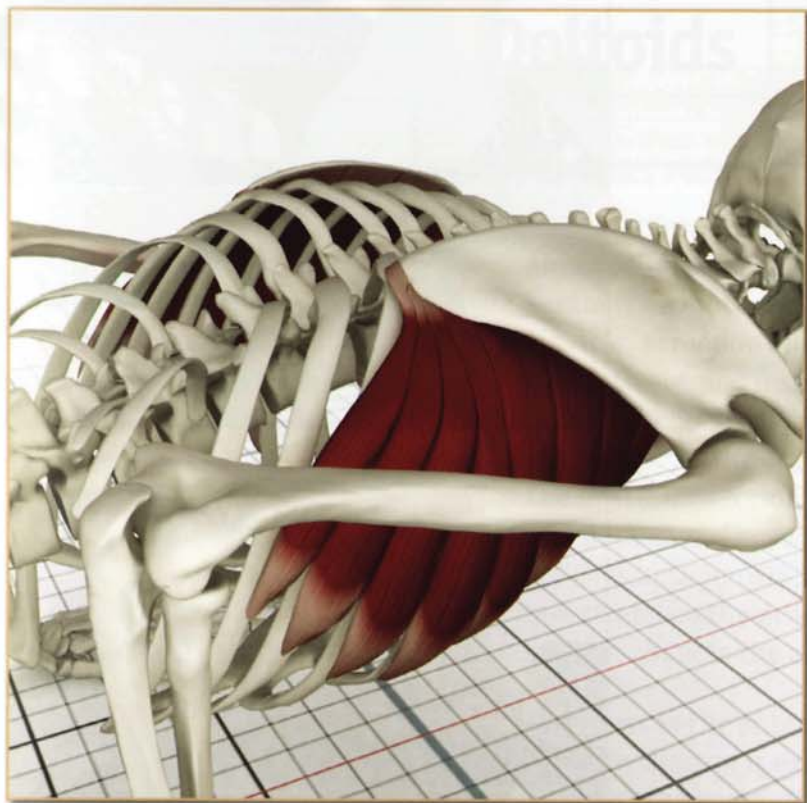
Rhomboid (major and minor) and trapezius (middle fibers).



Synergists

Pectoralis (major and minor).



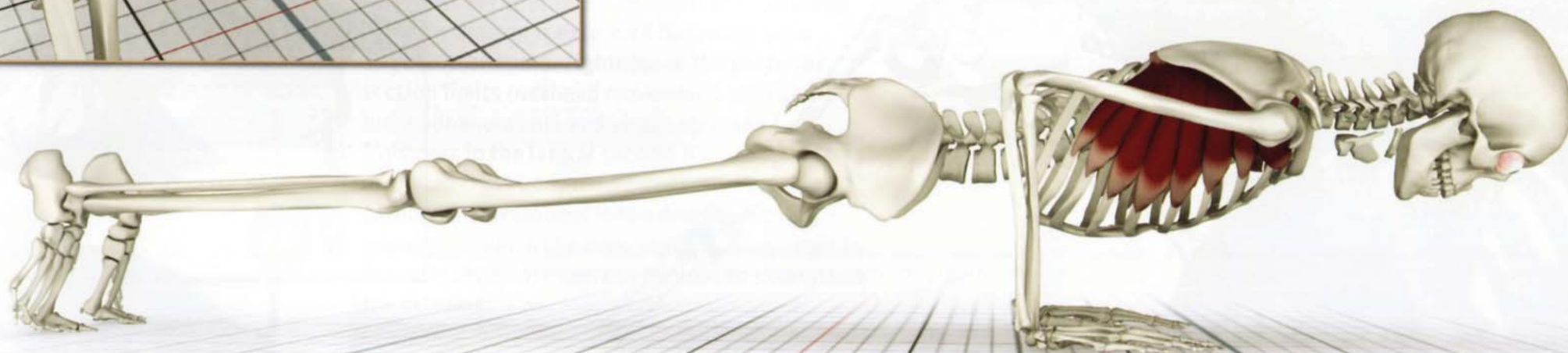


Action

Stabilizes and protracts (abducts) scapula, preventing the medial border from lifting or “winging” during pushing movements.

Assists scapular rotation.

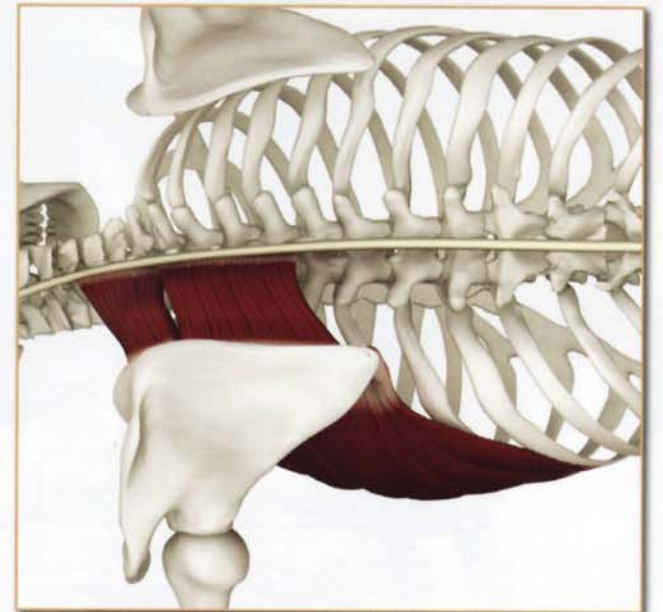
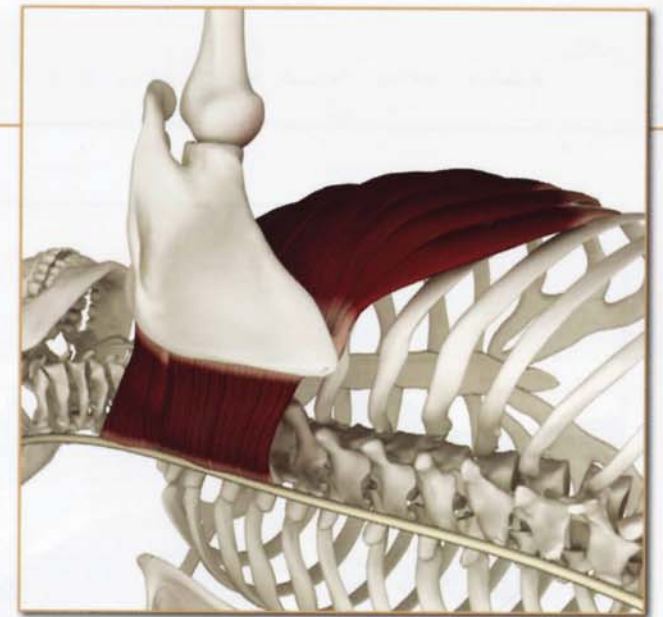
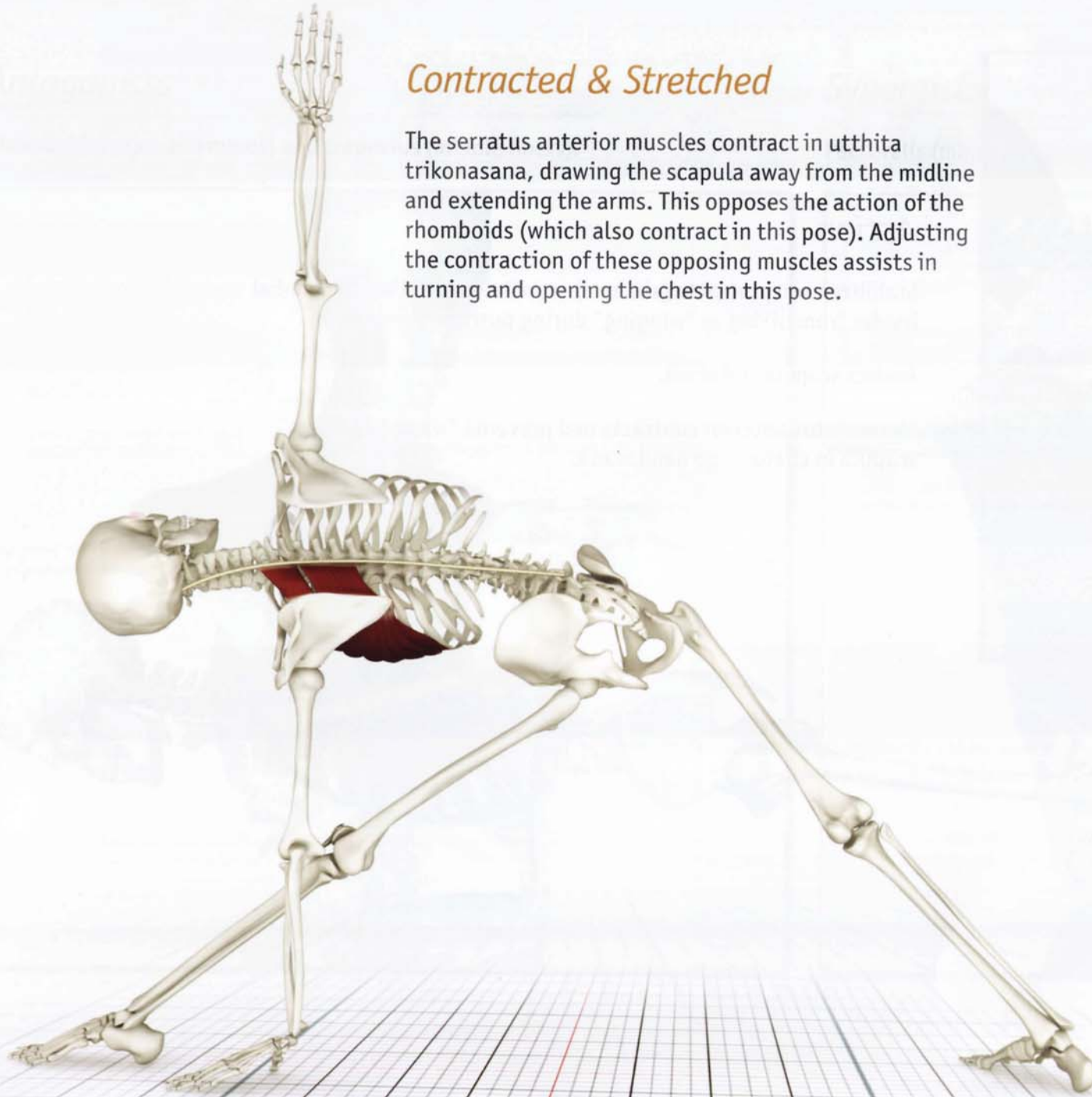The serratus anterior contracts and prevents “winging” of the scapula in chaturanga dandasana.



Serratus Anterior (ser-RA-tus an-TEER-I-or)

Contracted & Stretched

The serratus anterior muscles contract in utthita trikonasana, drawing the scapula away from the midline and extending the arms. This opposes the action of the rhomboids (which also contract in this pose). Adjusting the contraction of these opposing muscles assists in turning and opening the chest in this pose.



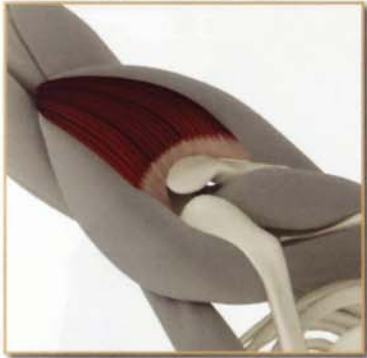Chapter 16

Deltoids

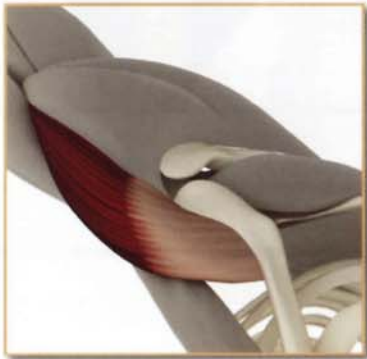posterior deltoid



lateral deltoid

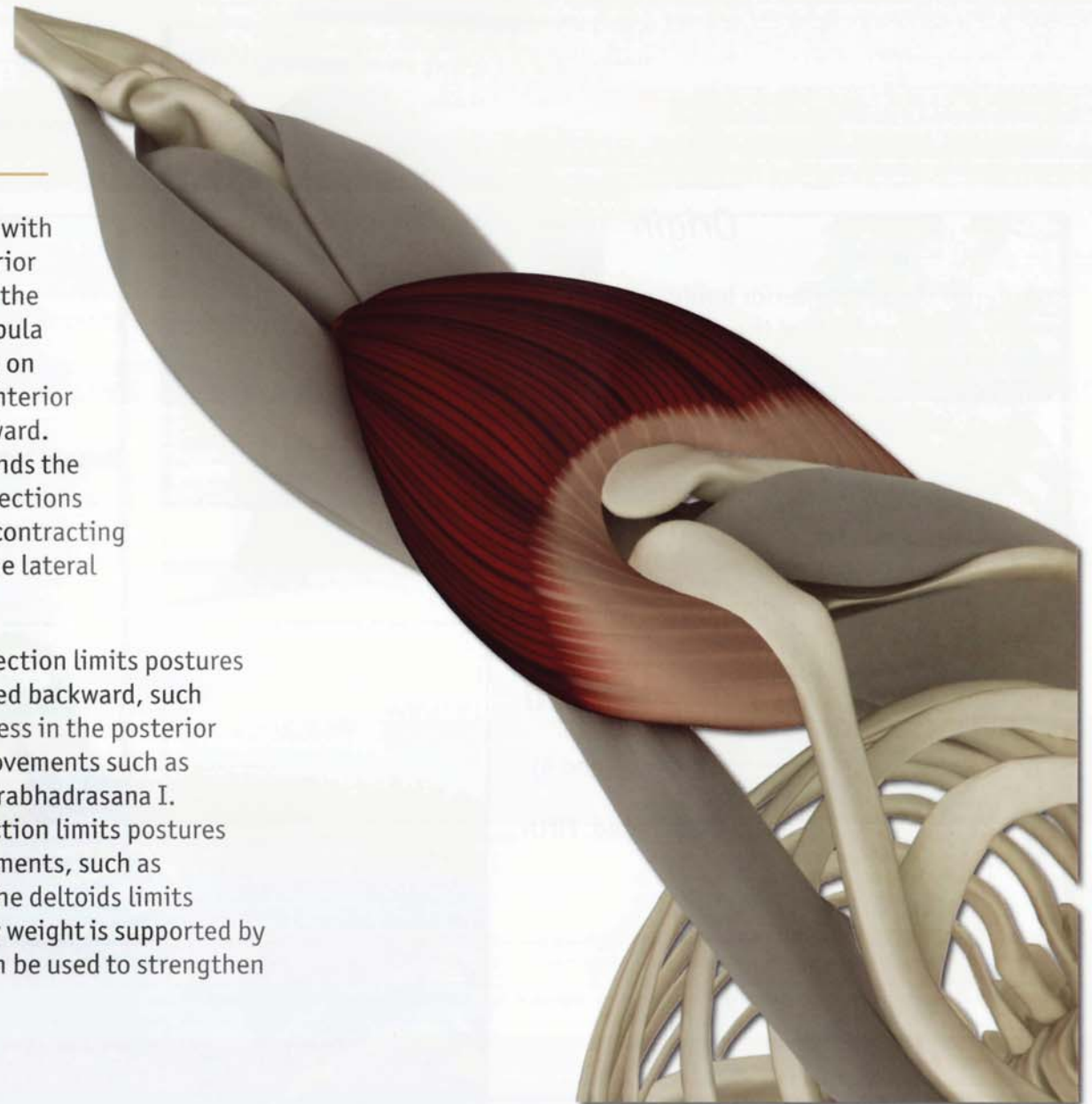


anterior deltoid



This is a three-part muscle with anterior, lateral and posterior sections, originating from the clavicle, acromion and scapula respectively, and inserting on the lateral humerus. The anterior section raises the arm forward. The posterior section extends the arm backward. These two sections are thus antagonists, and contracting one stretches the other. The lateral section abducts the arm.

Tightness in the anterior section limits postures in which the arm is extended backward, such as purvottonasana. Tightness in the posterior section limits overhead movements such as urdhvadhanurasana and virabhadrasana I. Tightness in the lateral section limits postures involving cross body movements, such as garudasana. Weakness in the deltoids limits postures in which the body weight is supported by the arms. Arm balances can be used to strengthen the deltoids.



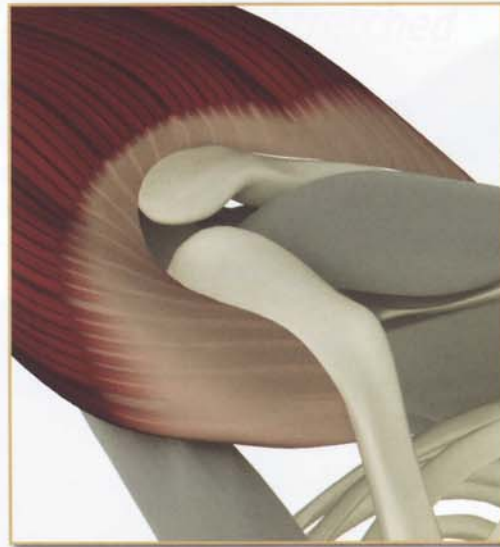
Deltoids

Origin

Anterior section: Anterior border of the lateral 1/3 of the clavicle.

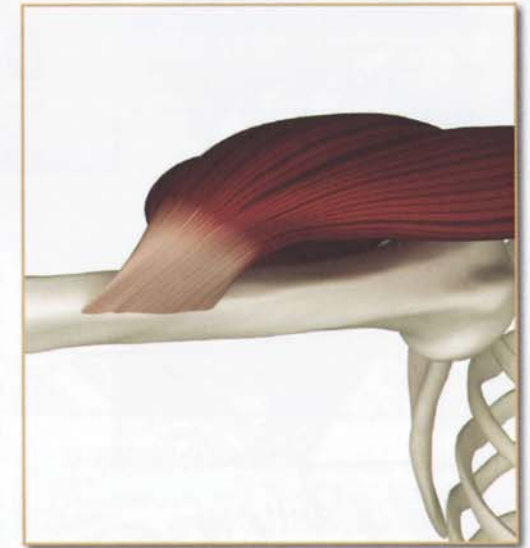
Lateral section: Lateral border of the acromion process of the scapula.

Posterior section: Scapular spine.



Insertion

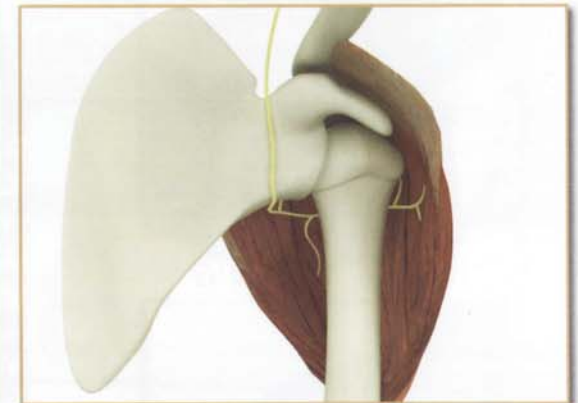
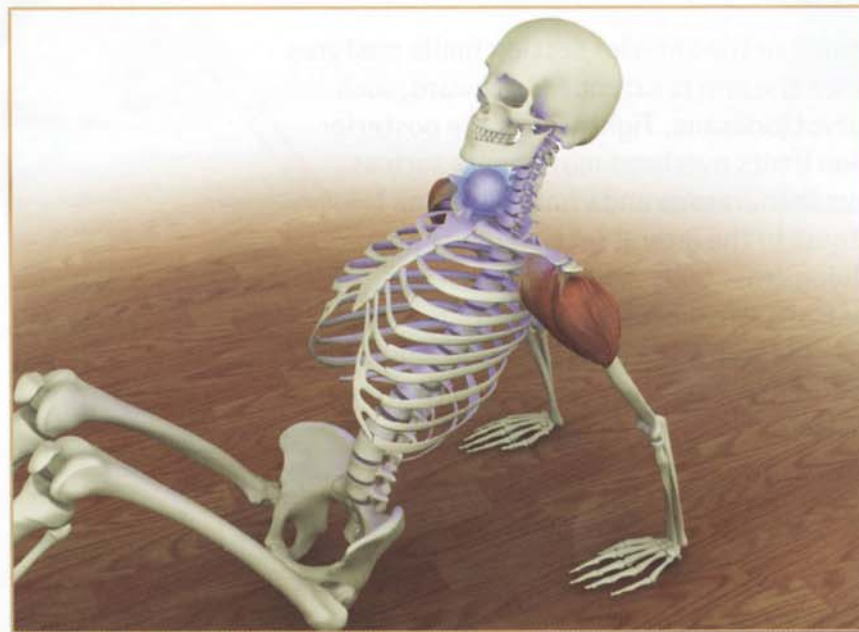
Deltoid tuberosity on lateral surface of the humeral shaft.



Innervation & chakra illuminated

Axillary nerve (cervical nerves 5 and 6).

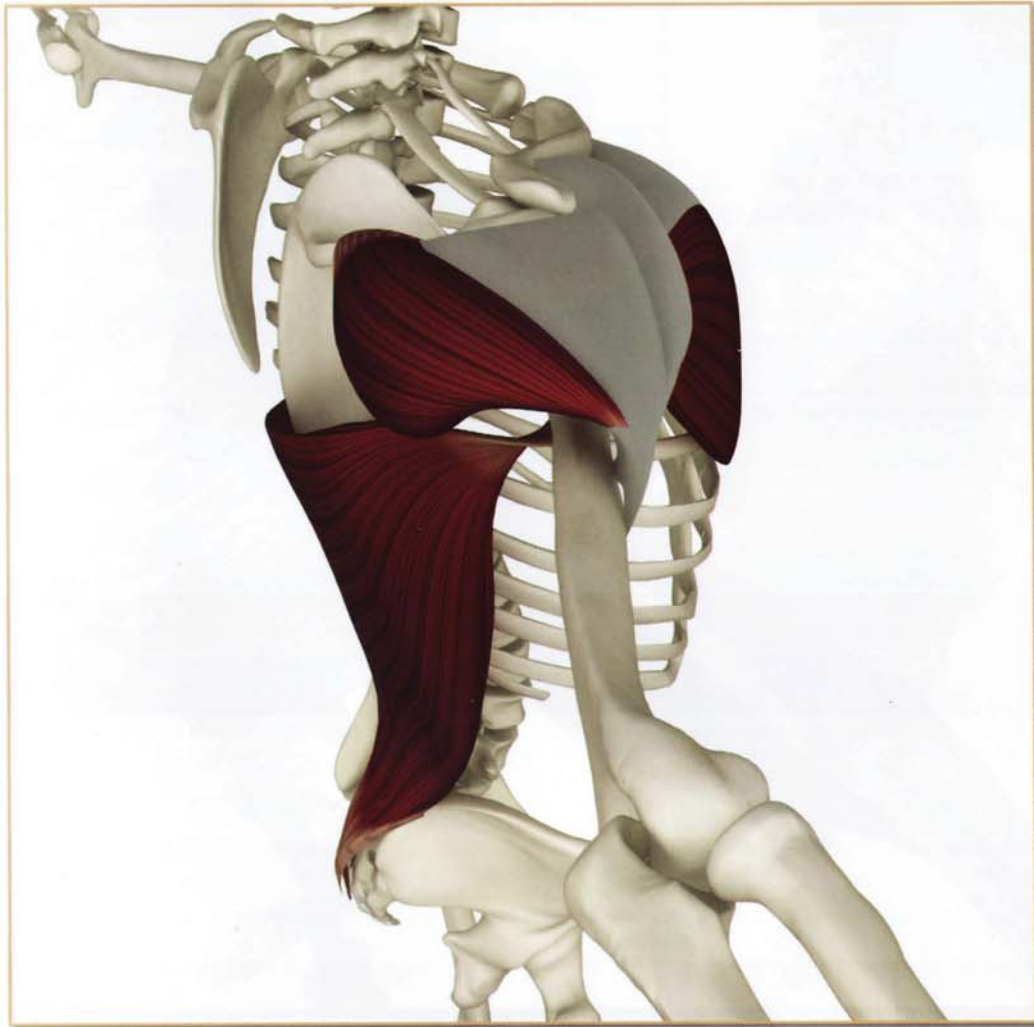
Chakra illuminated: Fifth



Deltoids Anterior Section

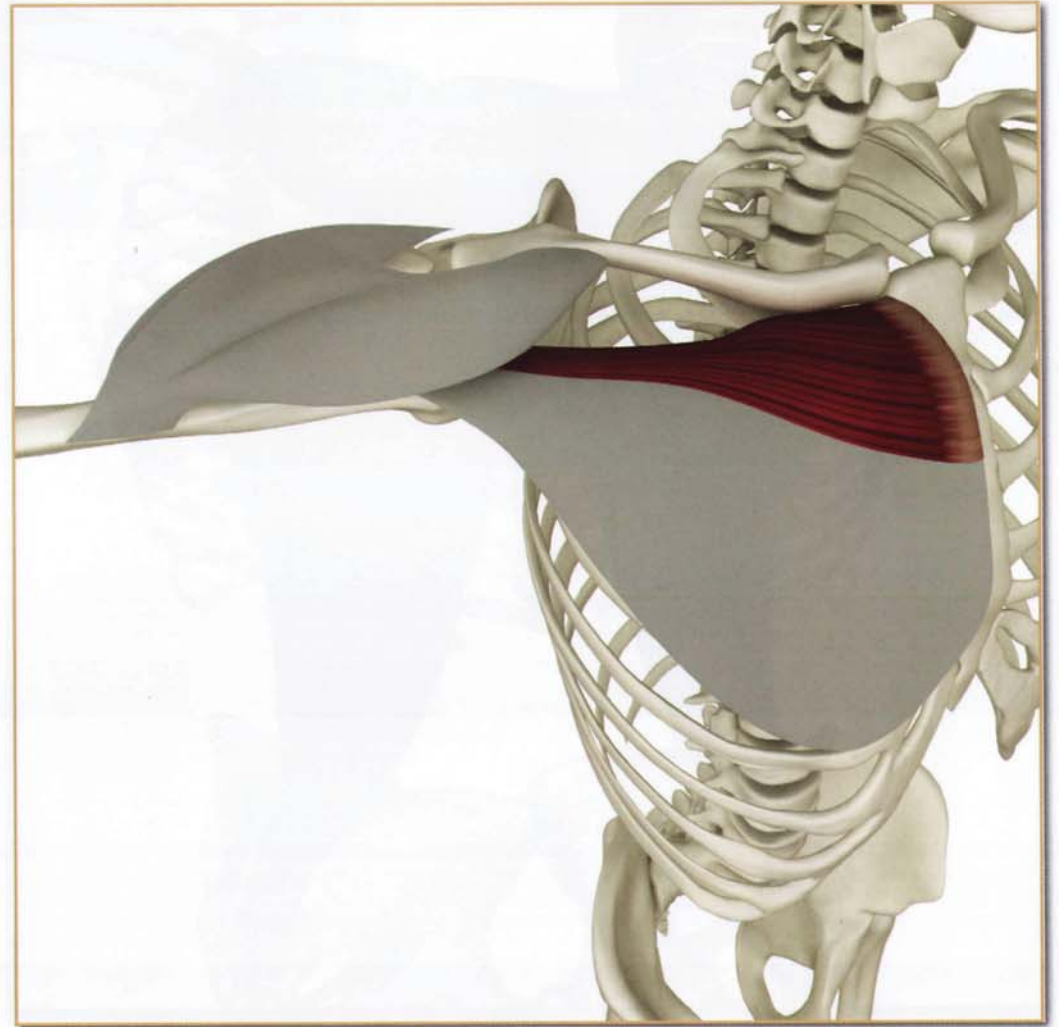
Antagonists

Deltoids (posterior section), latissimus dorsi and pectoralis major (sternocostal portion).



Synergists

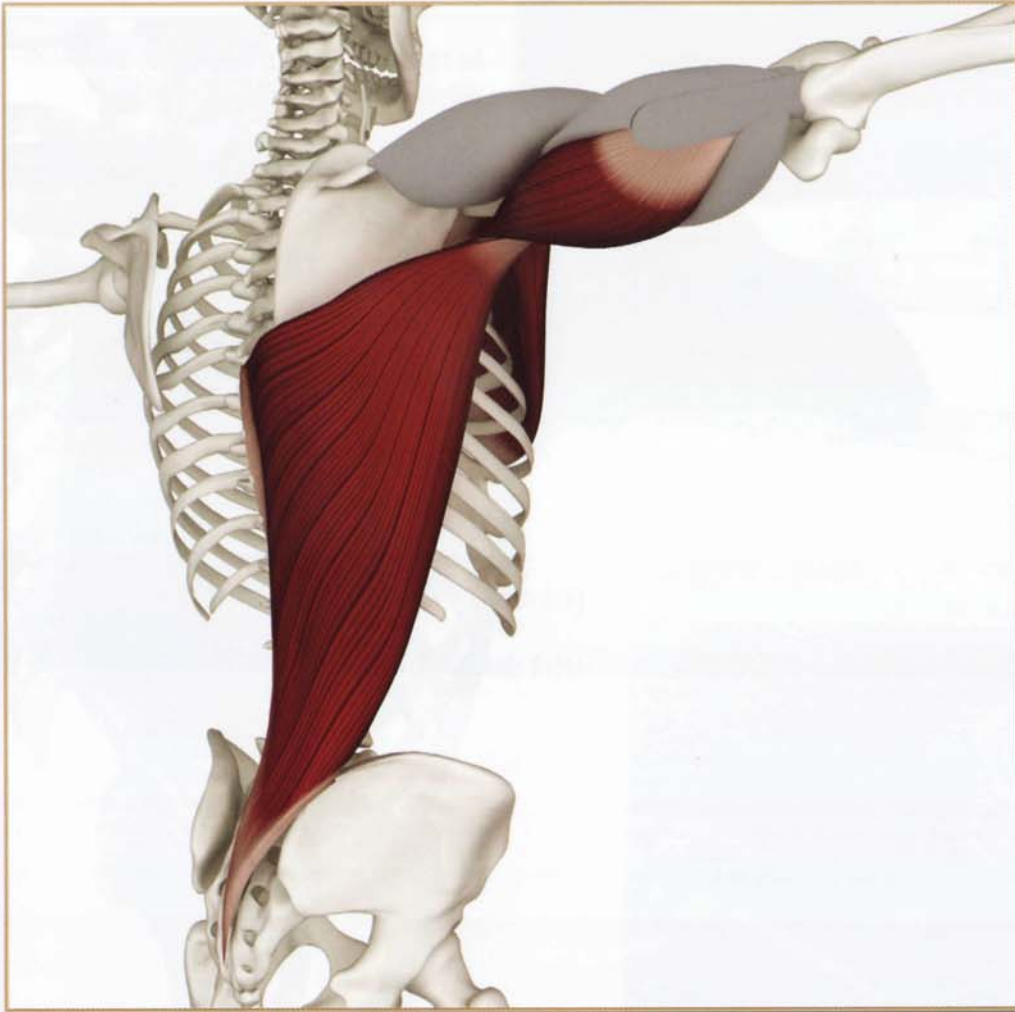Pectoralis major (clavicular portion).



Deltoids Lateral Section

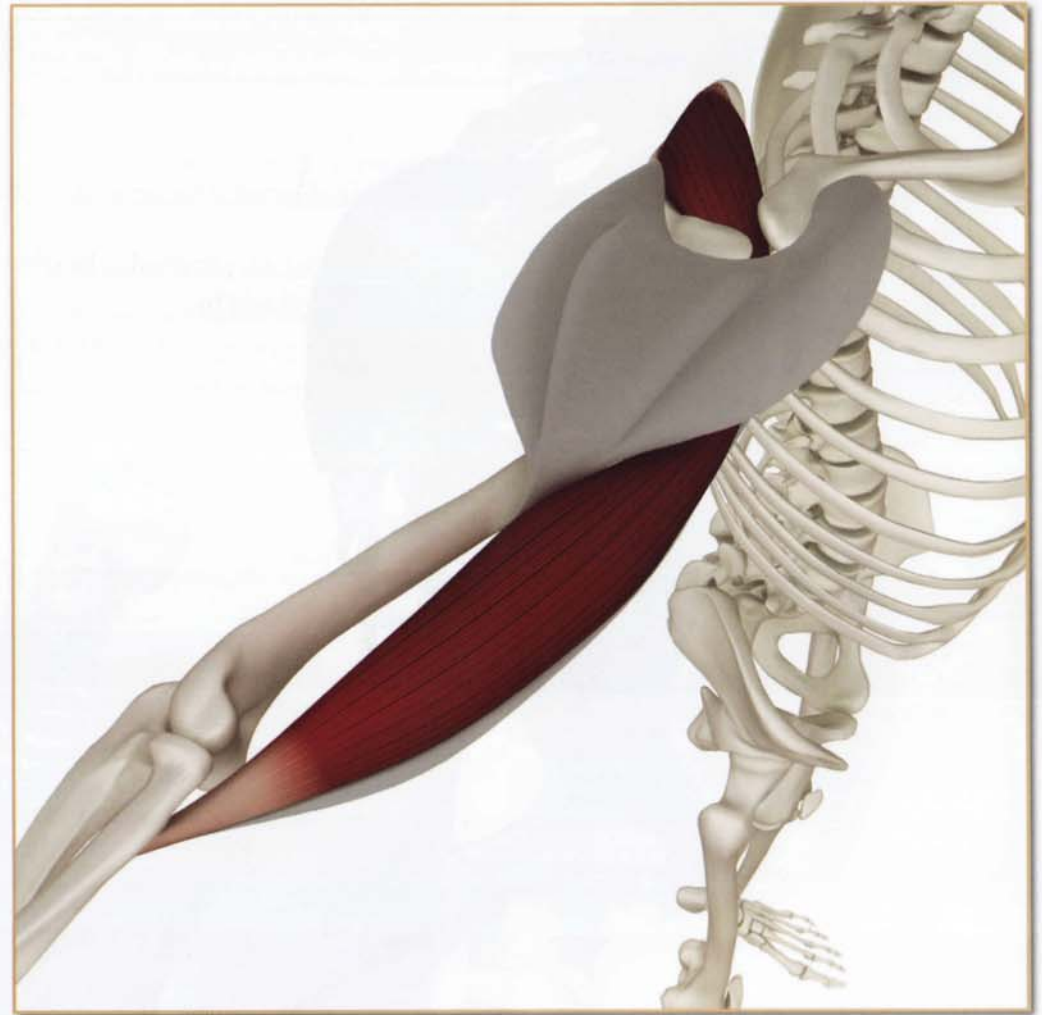Antagonists

Pectoralis major, latissimus dorsi and triceps (long head).



Synergists

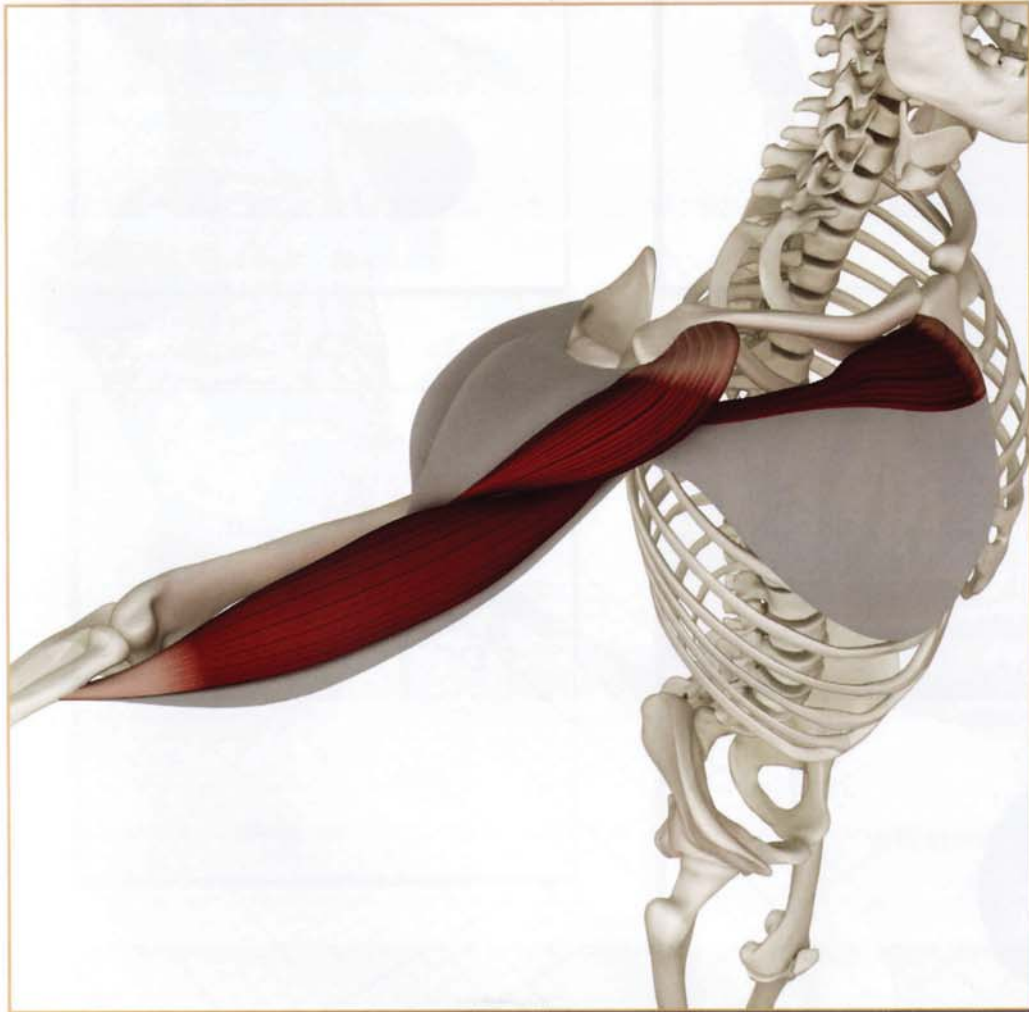
Supraspinatus and biceps (long head).



Deltoids Posterior Section

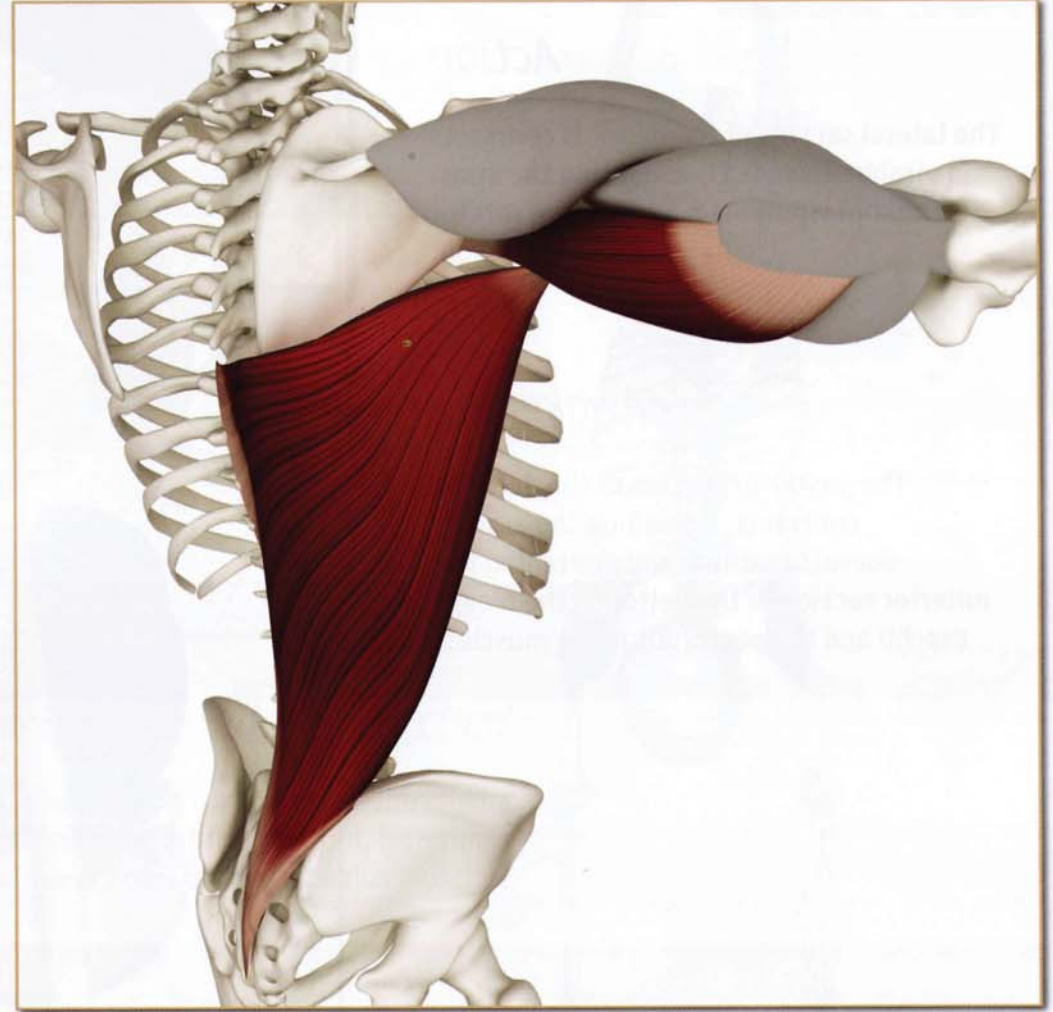
Antagonists

Deltoids (anterior section), biceps (long head) and pectoralis major (clavicular portion).

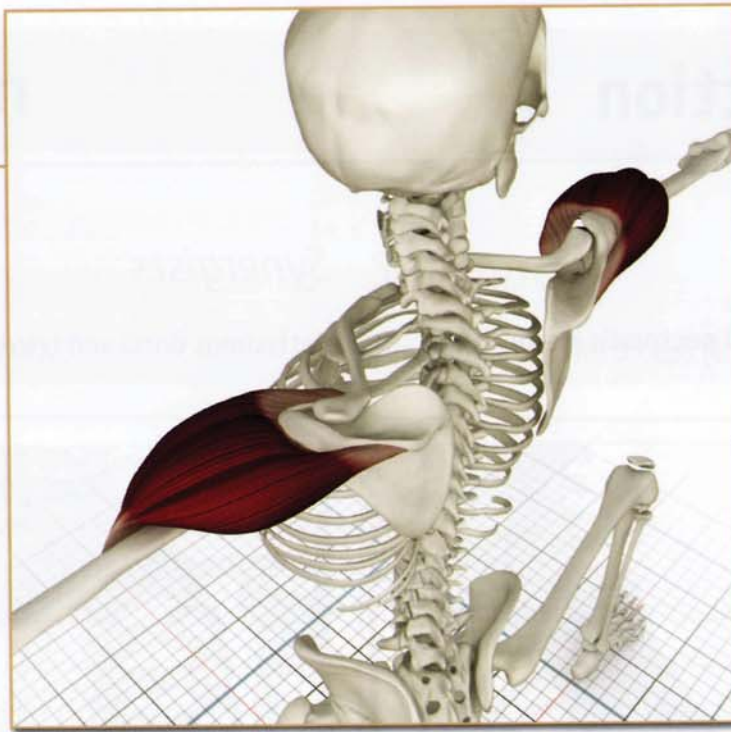

Synergists

Latissimus dorsi and triceps (long head)



Deltoids (DEL-toid)



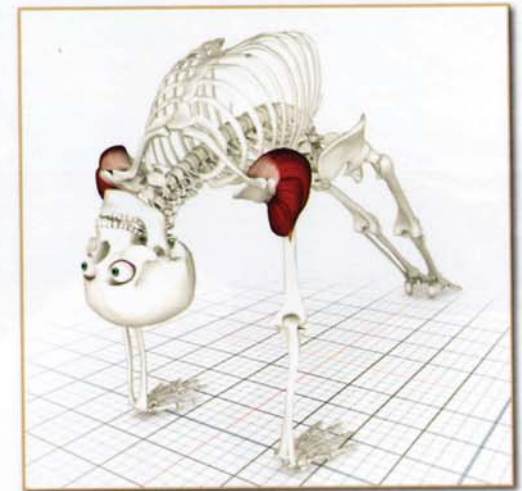
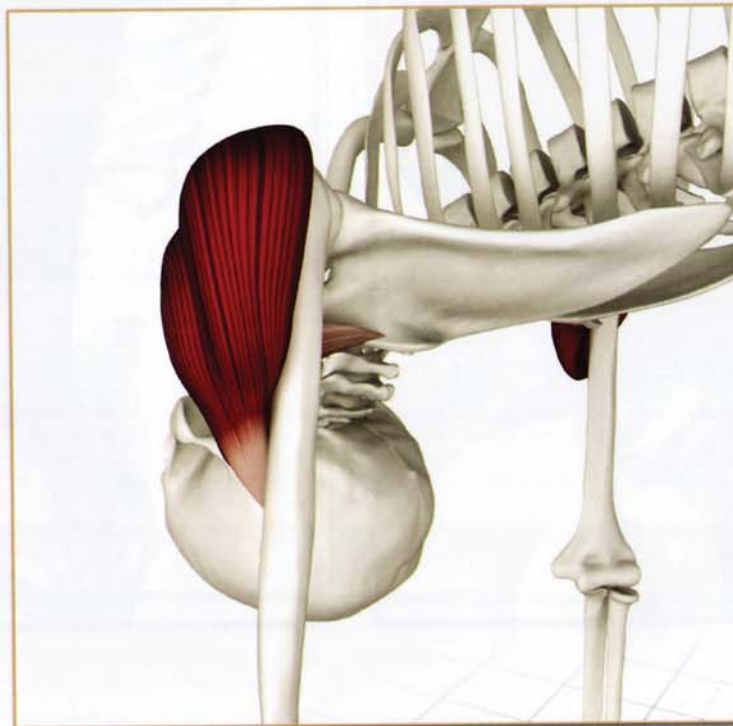
Action

The lateral section of the deltoids contracts in virabhadrasana II, abducting the arms. The supraspinatus muscle of the rotator cuff initiates this action.



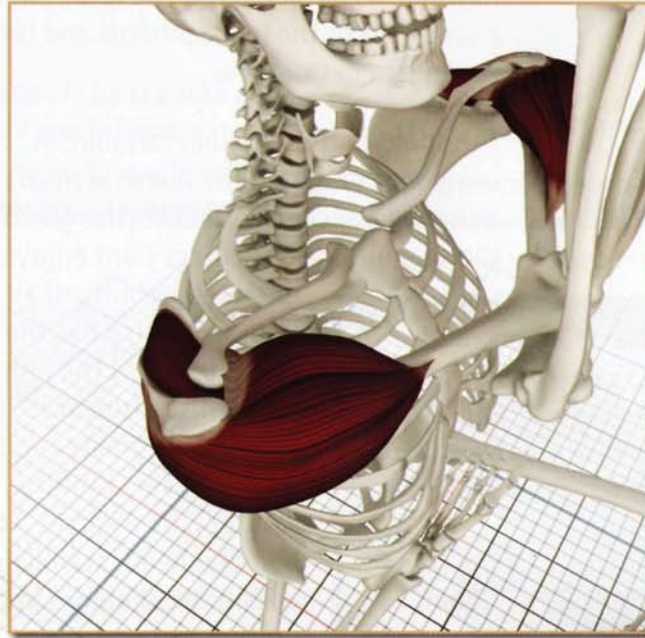
Awakening

The posterior section of the deltoids contracts, extending the arms in purvotthanasana, and stretching the anterior section of the deltoids, the biceps brachii and the pectoralis major muscles.



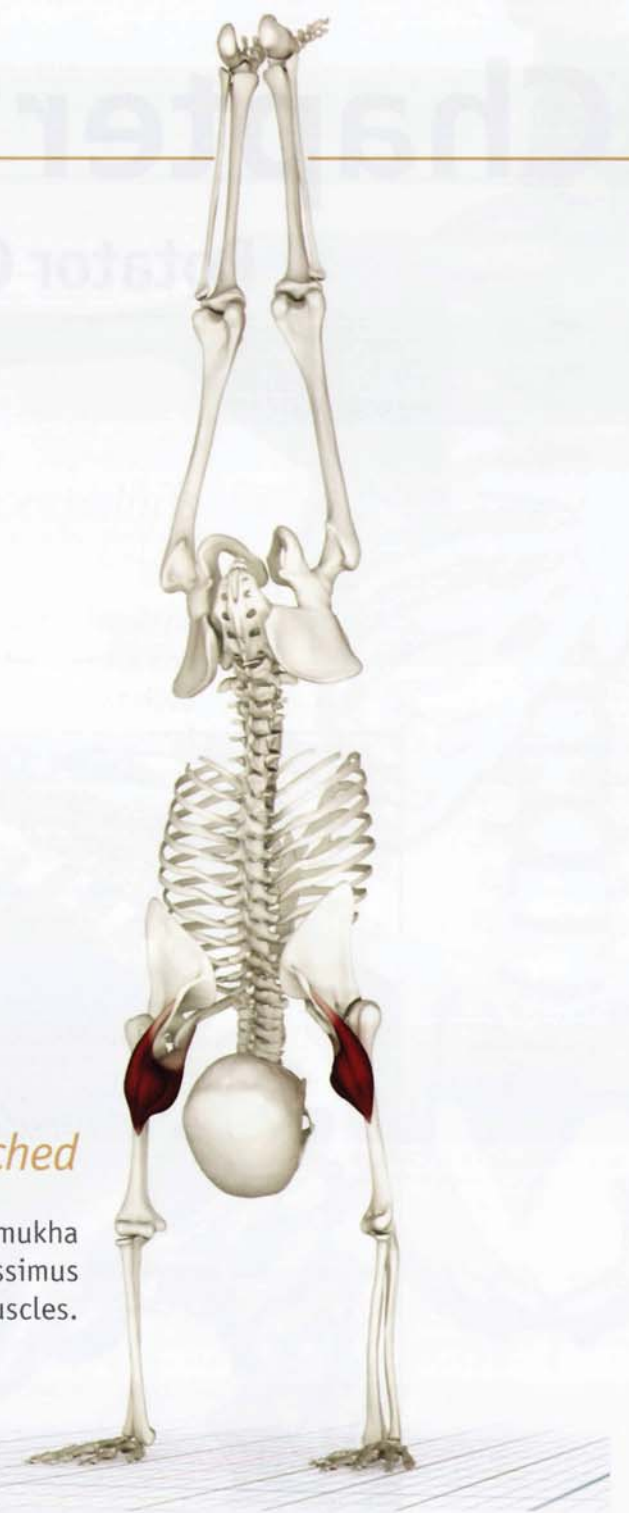Contracted & Stretched

The lateral and posterior sections of the deltoids stretch in vatayanasana. The pectoralis major contracts to accentuate this action.



Contracted & Stretched

The anterior deltoid contracts in adho mukha vrksasana, stretching the posterior deltoid, latissimus dorsi and lower fibers of the trapezius muscles.



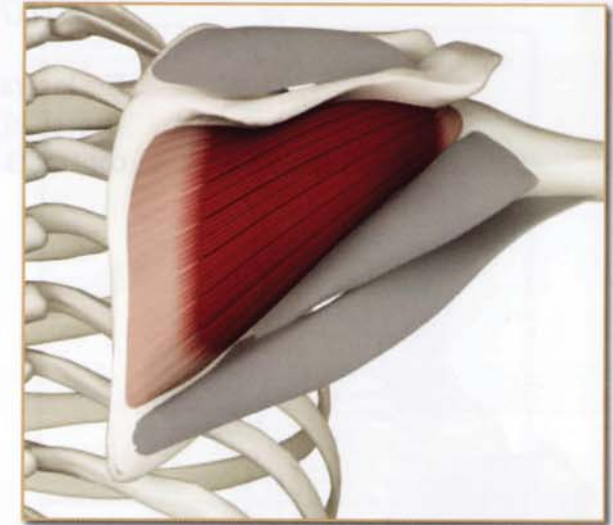
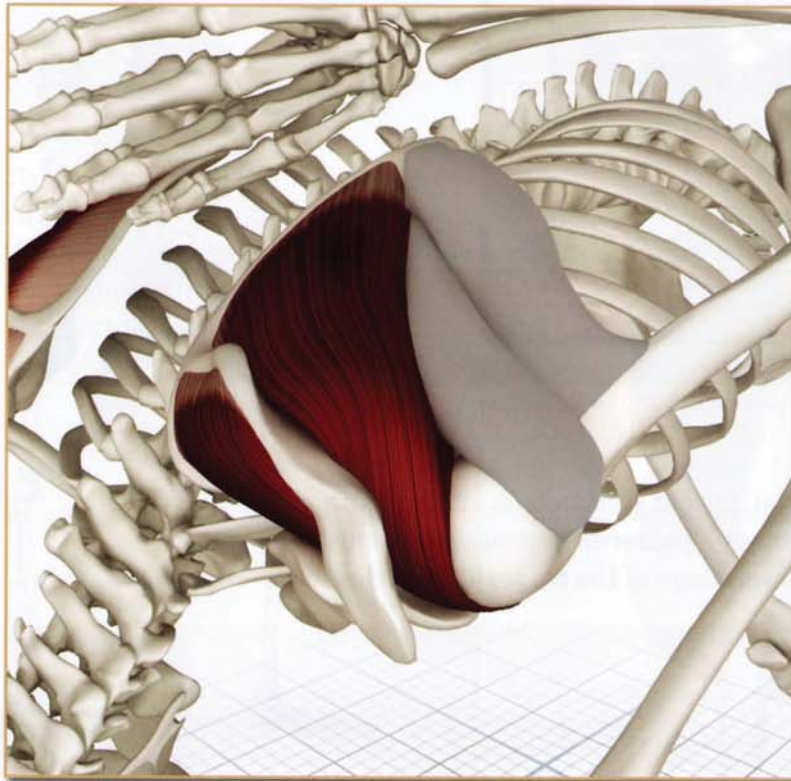
Chapter 17

Rotator Cuff

The rotator cuff is a combination of four muscles: the subscapularis, the infraspinatus, the teres minor and the supraspinatus. The subscapularis and infraspinatus have opposing actions and function as antagonists. The teres minor is a synergist of the infraspinatus and is not covered in detail here.

The shoulder (glenohumeral) joint is composed of a ball (the humeral head) and a shallow saucer-like socket (the glenoid of the scapula). The shoulder joint enjoys the greatest mobility of all the joints, but also has the least stability and is the joint most frequently dislocated. (Like a yin-yang, greater mobility means lesser stability.) The rotator cuff encircles the humeral head, stabilizing it within the shoulder joint.

As with the deep pelvic muscles, we are unaware of the rotator cuff, even though we use its muscles constantly in our daily life. Certain yoga postures awaken our consciousness of these muscles. Once awakened, their contraction and relaxation can be used to refine other postures.



Infraspinatus (in-fruh-spi-NA-t us)

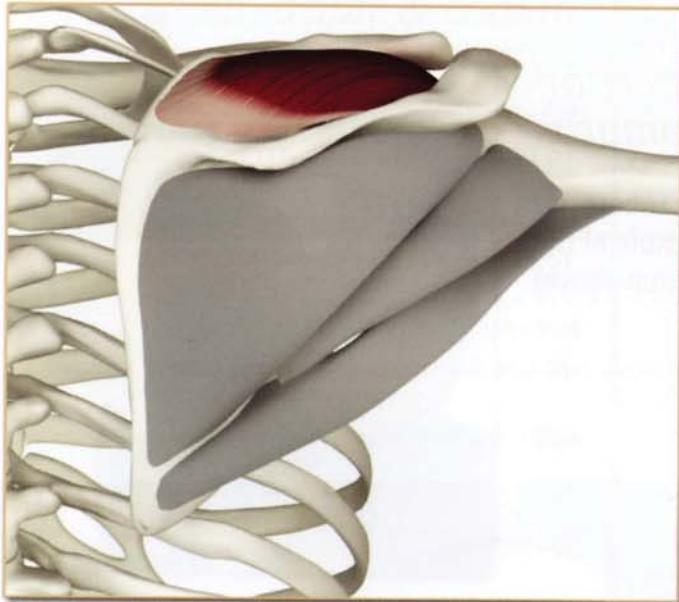
This muscle originates from the back (dorsal) surface of the scapula, inserting on the larger, more lateral greater tuberosity of the humerus. Contraction produces external rotation of the upper arm. The subscapularis and infraspinatus function as classic antagonists. Tightness of the infraspinatus limits internal rotation of the humerus, especially in postures such as *parsvottanasana*. Weakness limits external rotation in poses such as *urdhvadhanurasana*.

Rotator Cuff

Supraspinatus (soo-pruh-spi-NA-tus)

The supraspinatus originates from the back (dorsal) surface of the scapula and inserts on the greater tuberosity of the humerus in front of the infraspinatus. The supraspinatus initiates arm abduction. Injury to this muscle results in the use of accessory muscles such as the trapezius and deltoids to accomplish this action.

Of all the rotator cuff muscles the supraspinatus is the most frequently injured, due to impingement of its tendon on the inferior surface of the acromion process of the scapula. In yoga, impingement can occur in asanas such as dog pose and urdhvadhanurasana. This problem can be avoided by externally rotating the humerus and inwardly rotating the scapula.



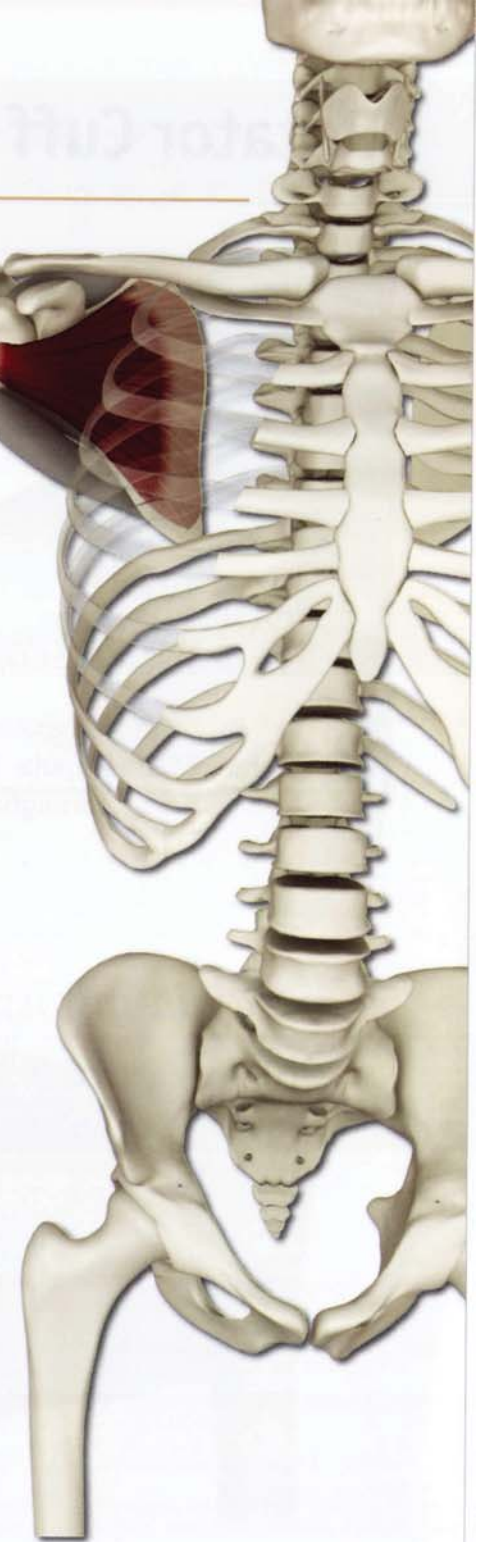Supraspinatus (back view)

Tightness of the supraspinatus limits poses where the arm crosses the chest (such as in garudasana). Injuries may limit abduction of the arm, resulting in a “shrugged” shoulder appearance to poses where the arm is abducted (such as virabhadrasana II).



Subscapularis (sub-skap-u-LAR E-us)

The subscapularis originates from the inside (ventral) surface of the scapula and inserts on a knob-shaped structure called the “lesser tuberosity” of the humeral head. Contracting the subscapularis internally rotates the humerus. Tightness in this muscle limits poses with an external rotation component of the upper arms, such as urdhvadhanurasana. Weakness limits poses such as parsvottanasana.

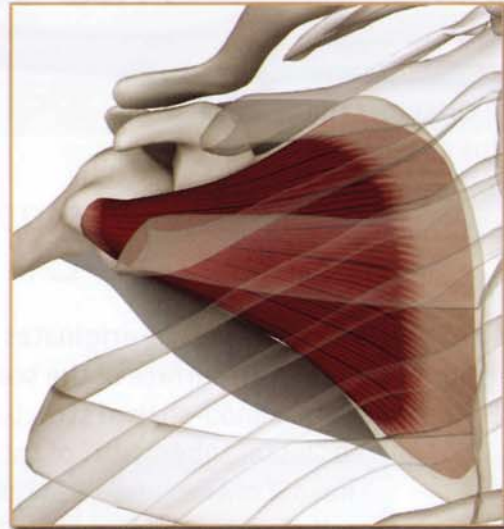


Rotator Cuff

Rotator Cuff

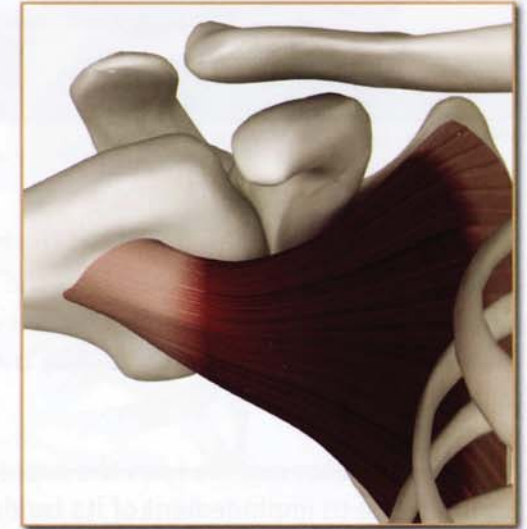
Origin Subscapularis

Subscapular fossa on anterior surface of the scapula. (seen here through the chest)



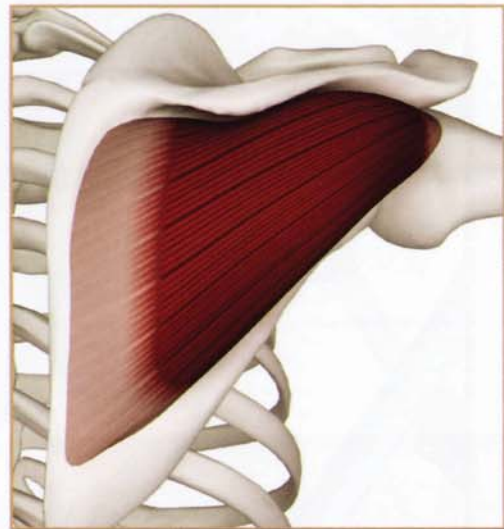
Insertion Subscapularis

Lesser tuberosity of humerus and capsule of the shoulder joint (lower part).



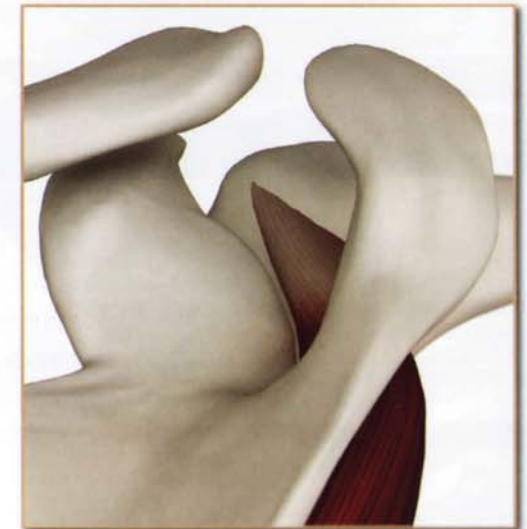
Origin-Infraspinatus

Infraspinous fossa of the scapula.



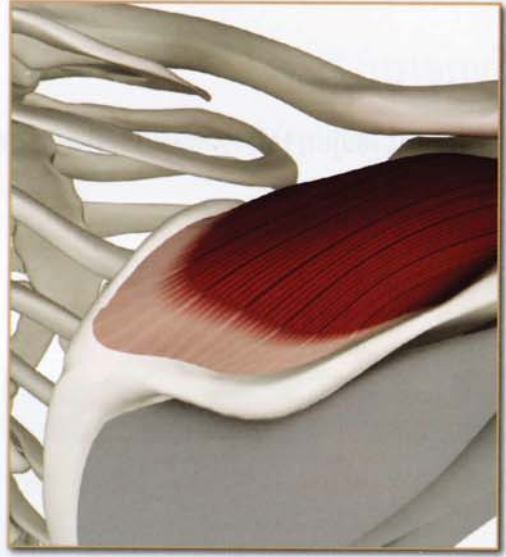
Insertion Infraspinatus

Middle facet of greater tuberosity of the humerus and capsule of the shoulder joint. (shown from above)



*Origin
Supraspinatus
(back view)*

Supraspinous fossa of scapula.

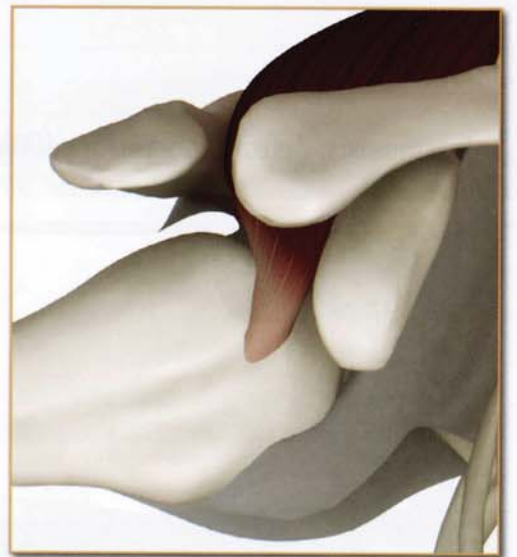


Synergists

Infraspinatus

*Insertion
Supraspinatus
(front view)*

Upper part of greater tuberosity of humerus and capsule of the shoulder joint.



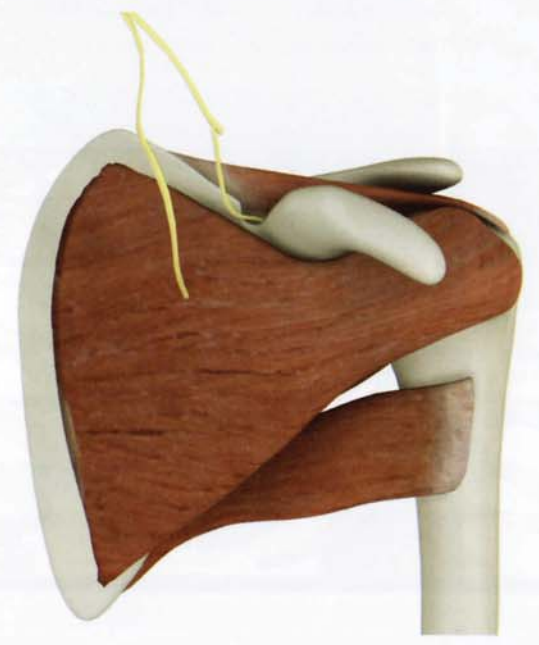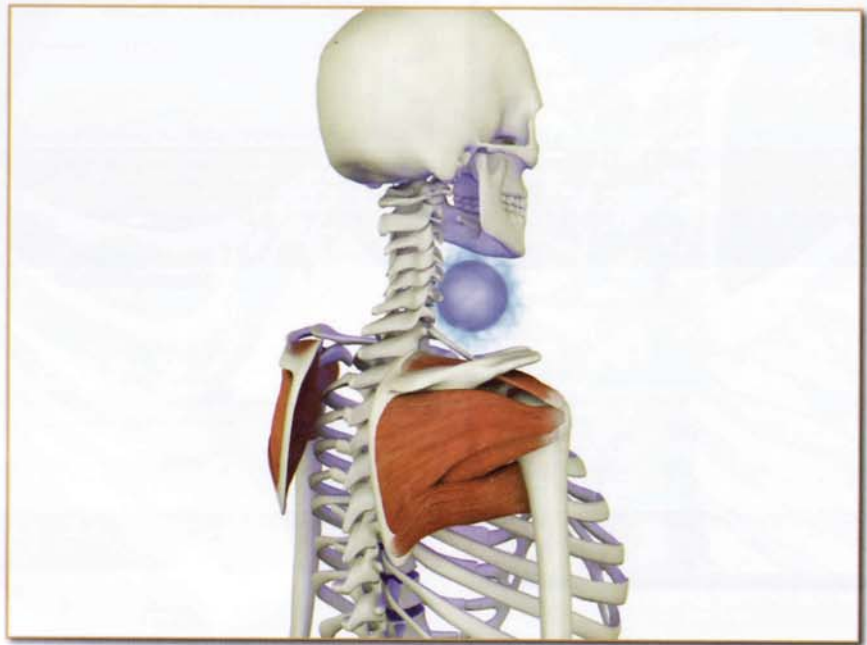Innervation & chakra illuminated

Subscapularis: Upper and lower subscapular nerves (cervical nerves 5 and 6).

Infraspinatus: Suprascapular nerve (cervical nerves 5 and 6).

Supraspinatus: Suprascapular nerve (cervical nerves 5 and 6).

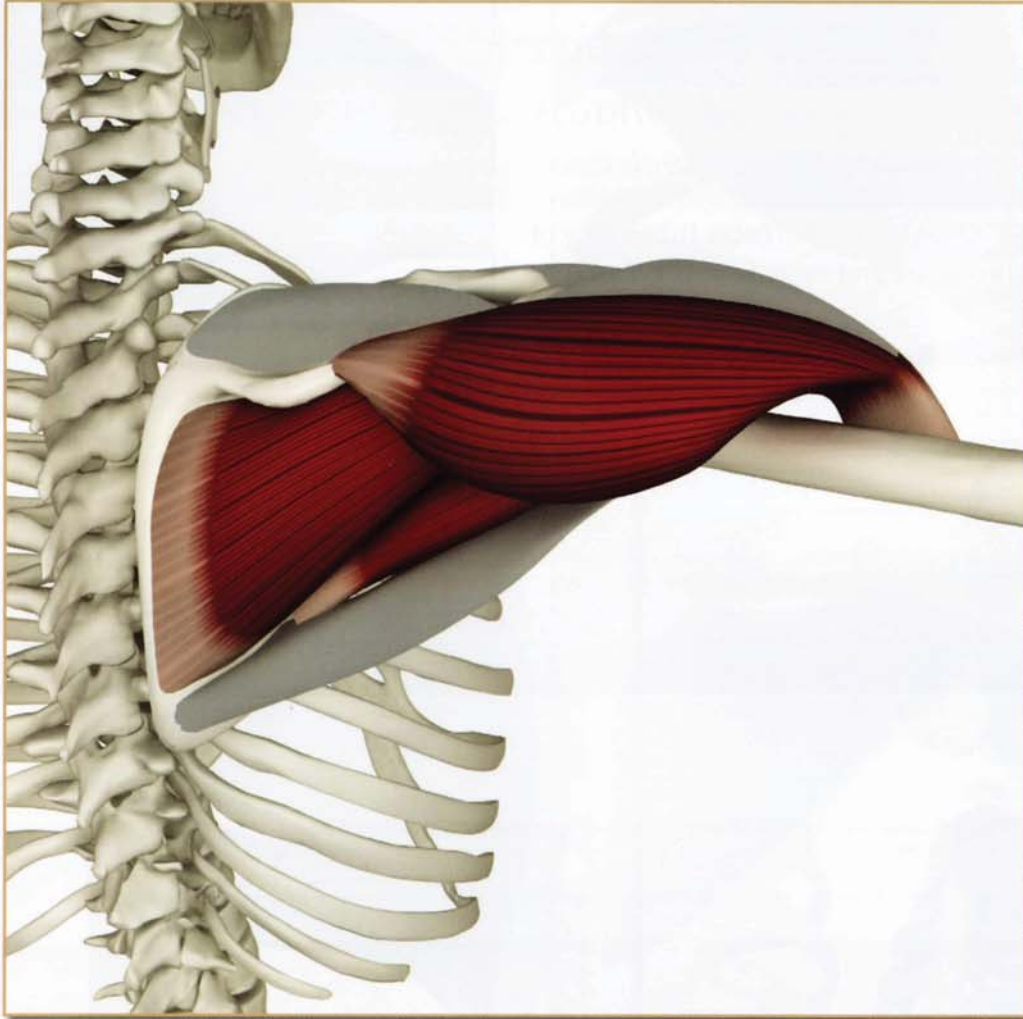
Chakra illuminated: Fifth



Subscapularis

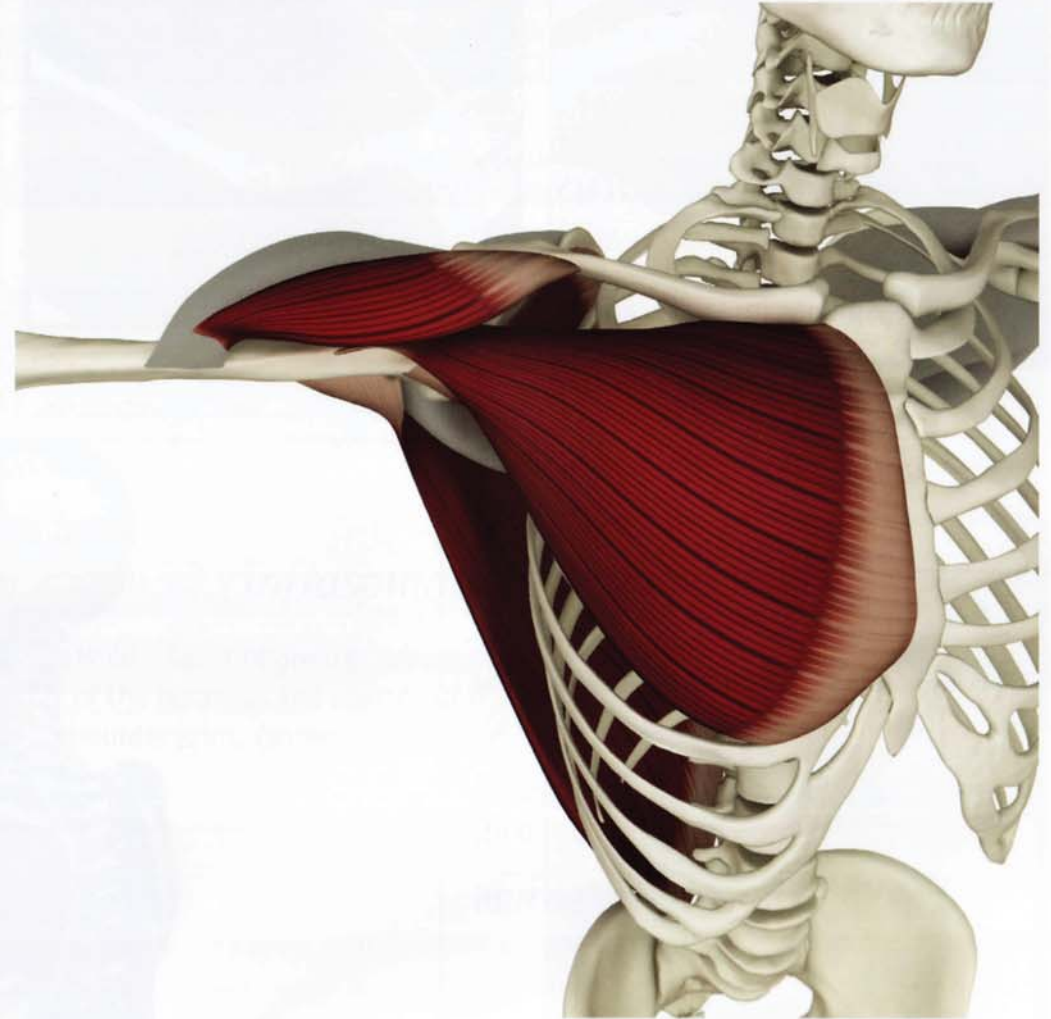
Antagonists

Infraspinatus, deltoid (posterior section) and teres minor.



Synergists

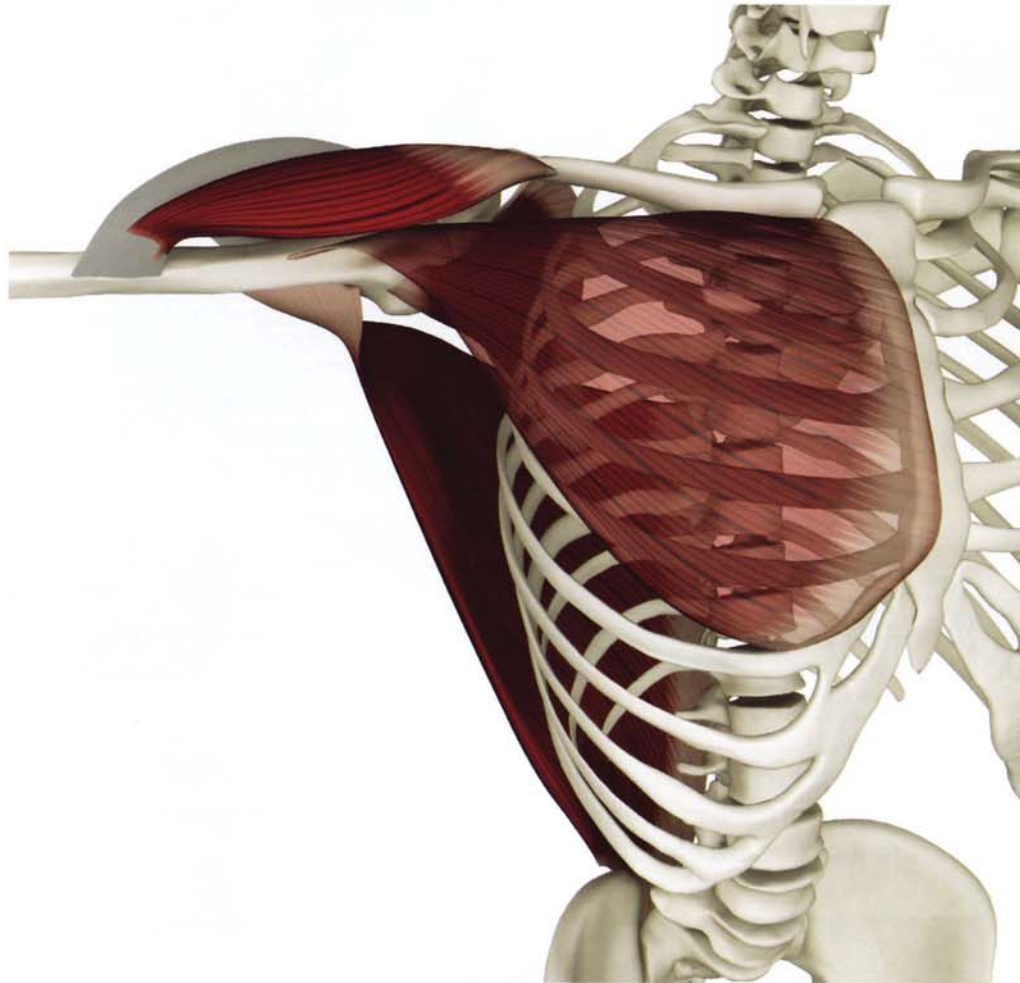
Pectoralis major, latissimus dorsi and deltoid (anterior section).



Infraspinatus & Infraspinatus

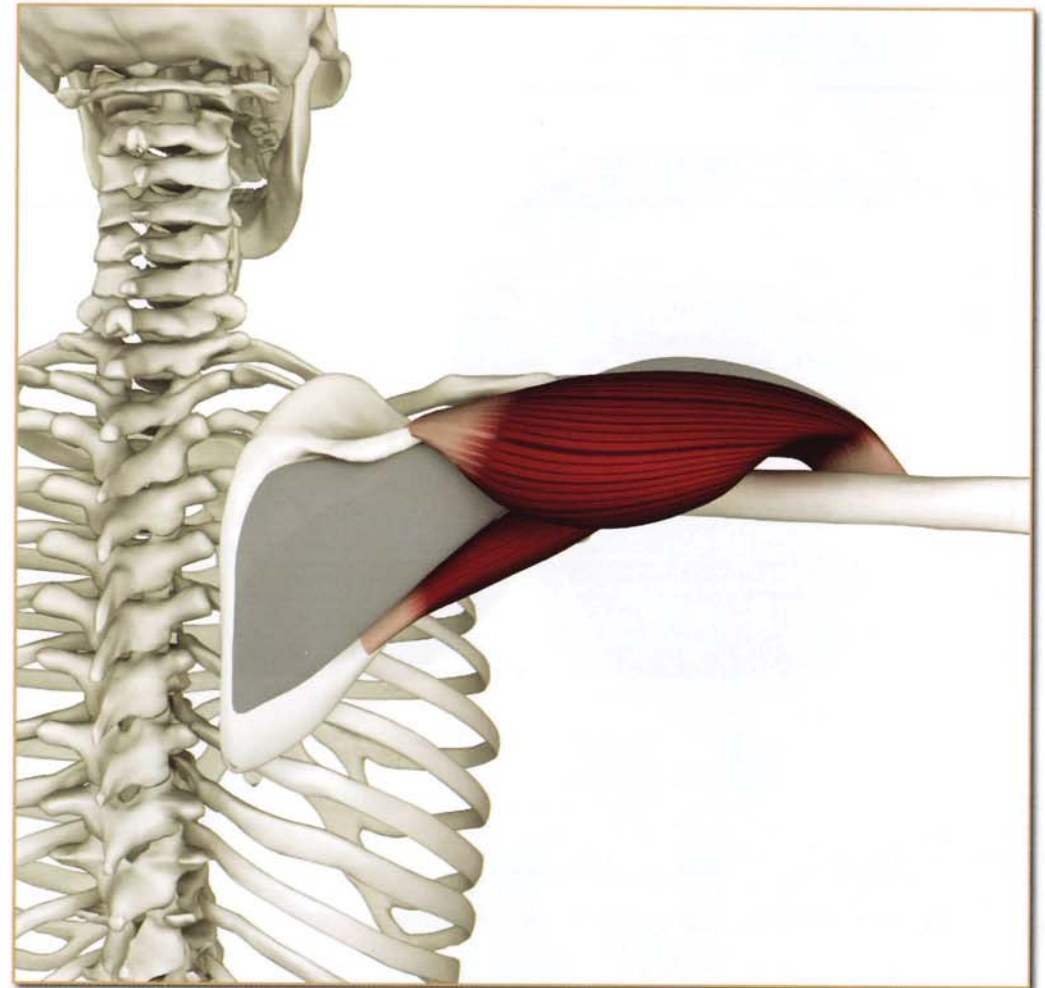
Antagonists

Subscapularis, latissimus dorsi, pectoralis major and deltoid (anterior section).



Synergists

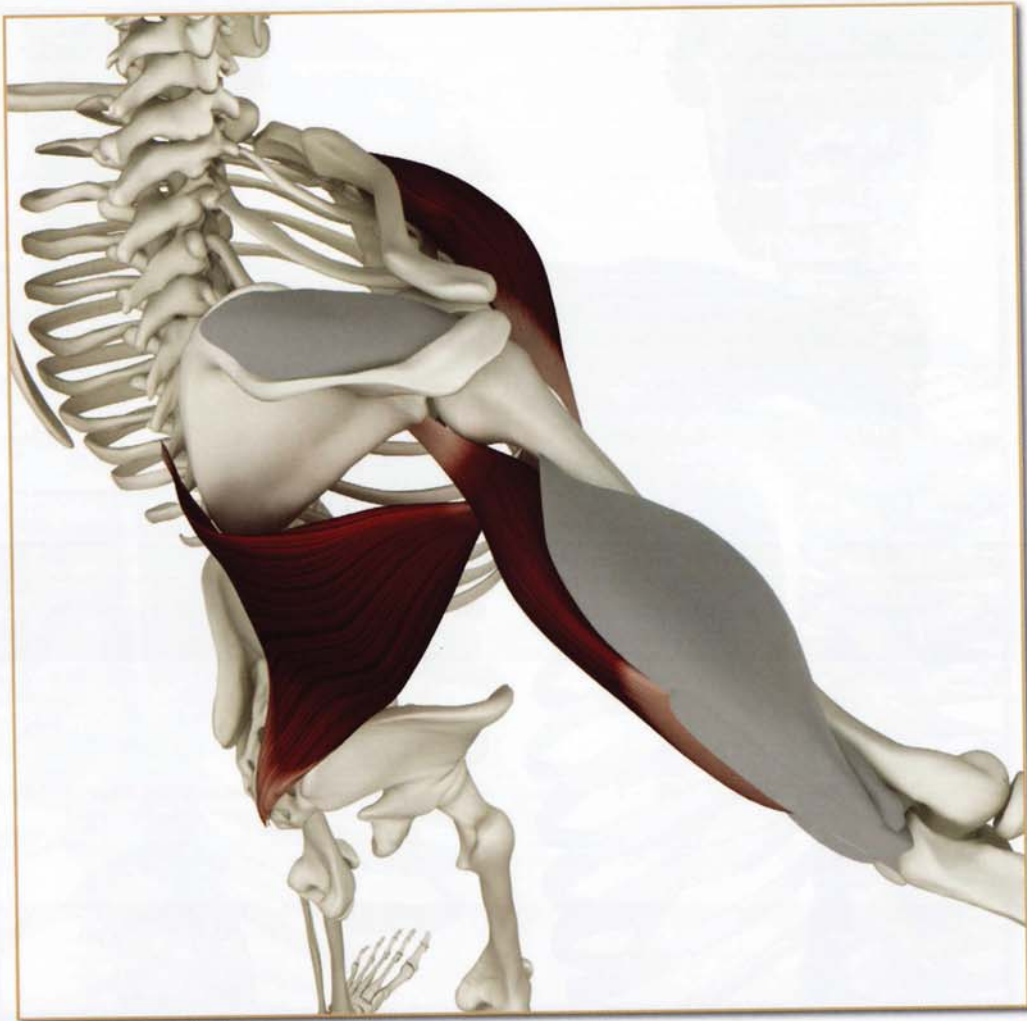Teres minor and deltoid (posterior section).



Supraspinatus

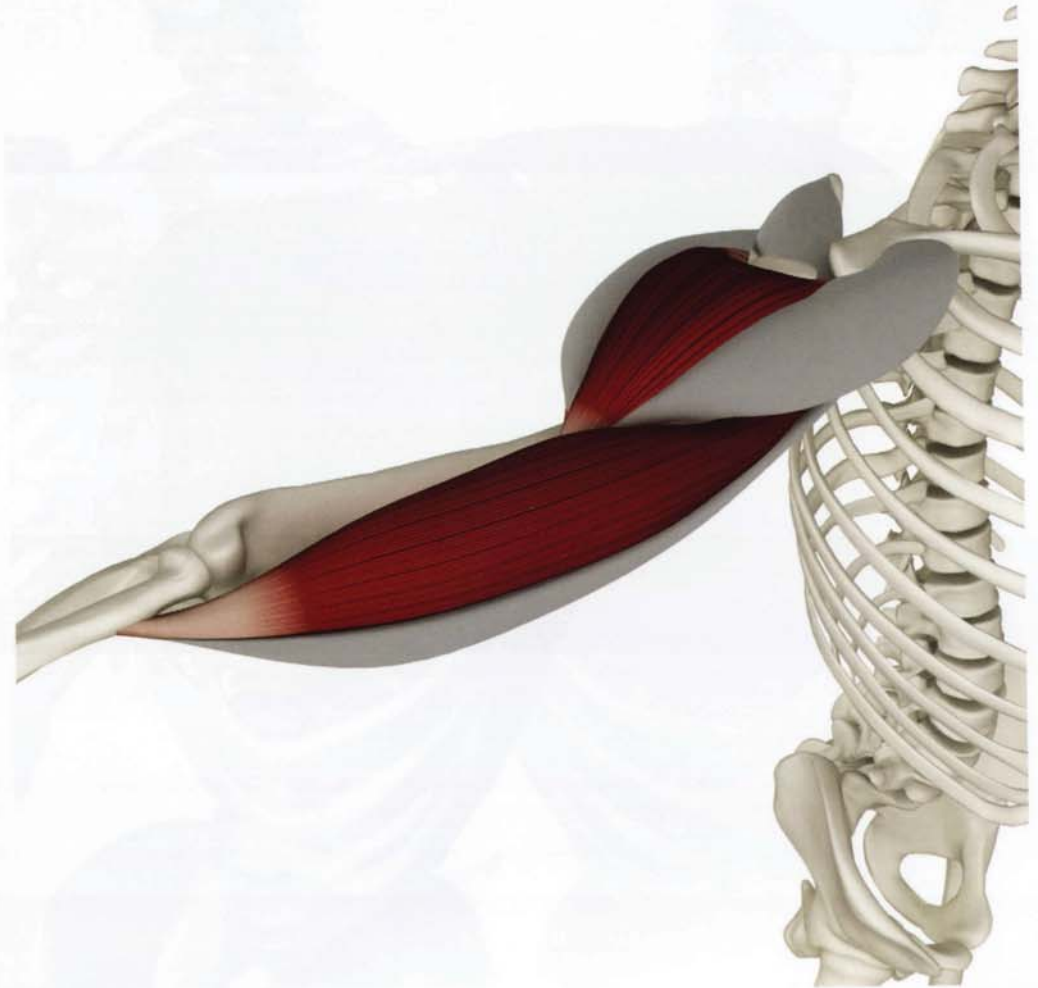Antagonists

Pectoralis major, latissimus dorsi and triceps (long head).



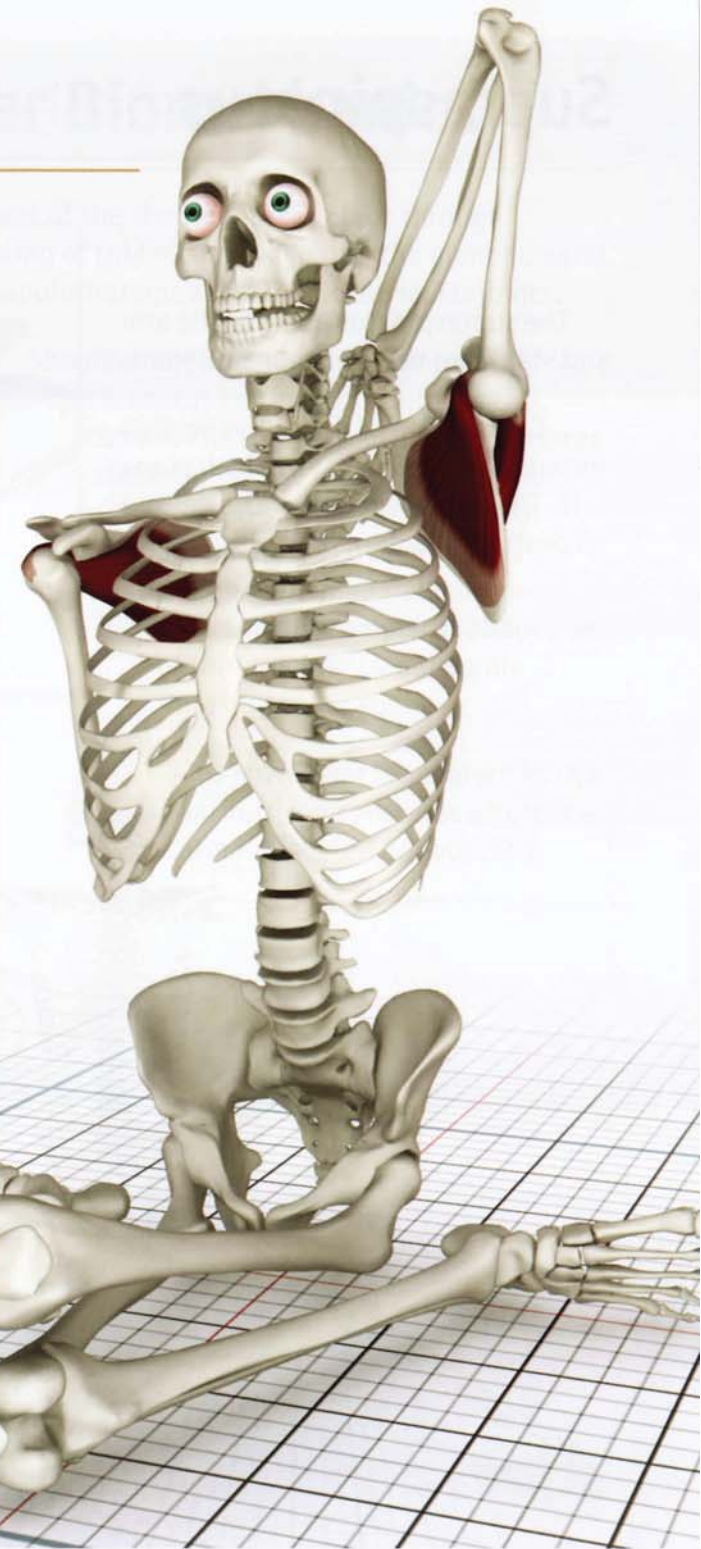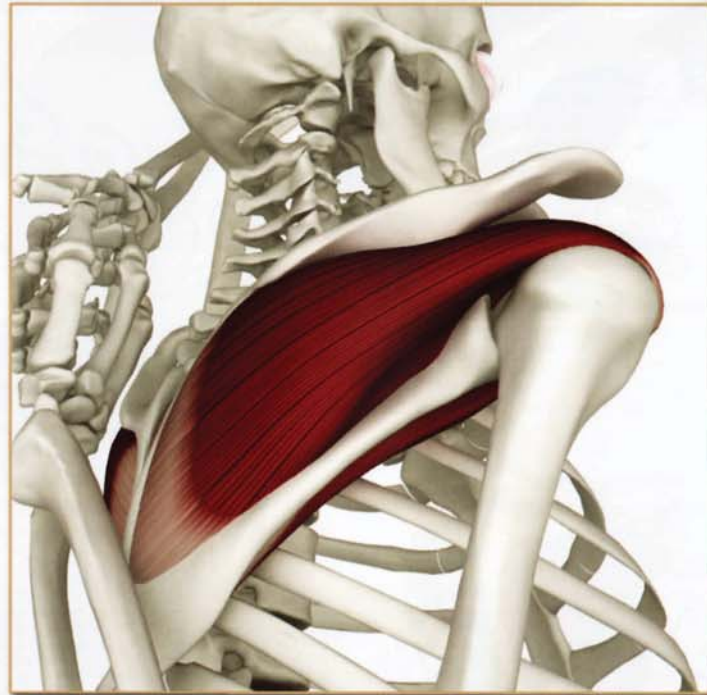
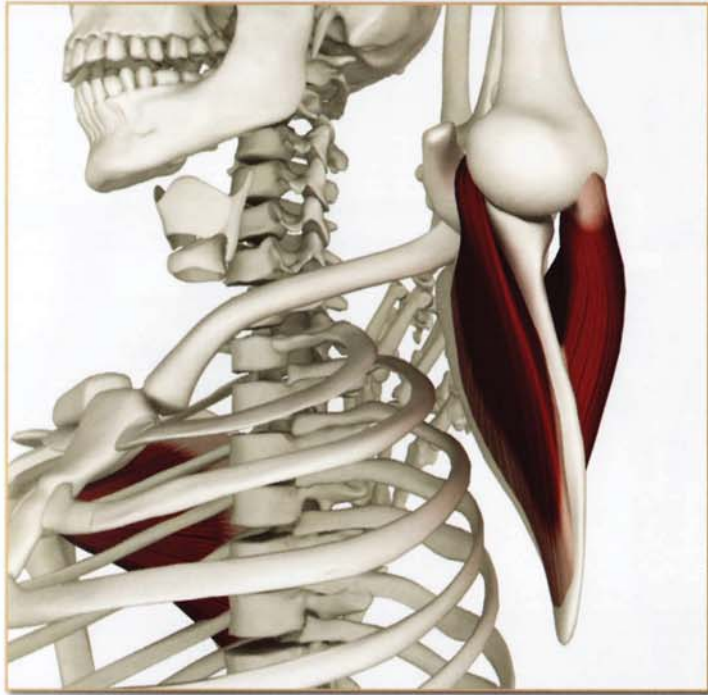Synergists

Deltoid (lateral section) and biceps (long head).



Subscapularis & Infraspinatus

Shoulder Dislocation



Contracted & Stretched


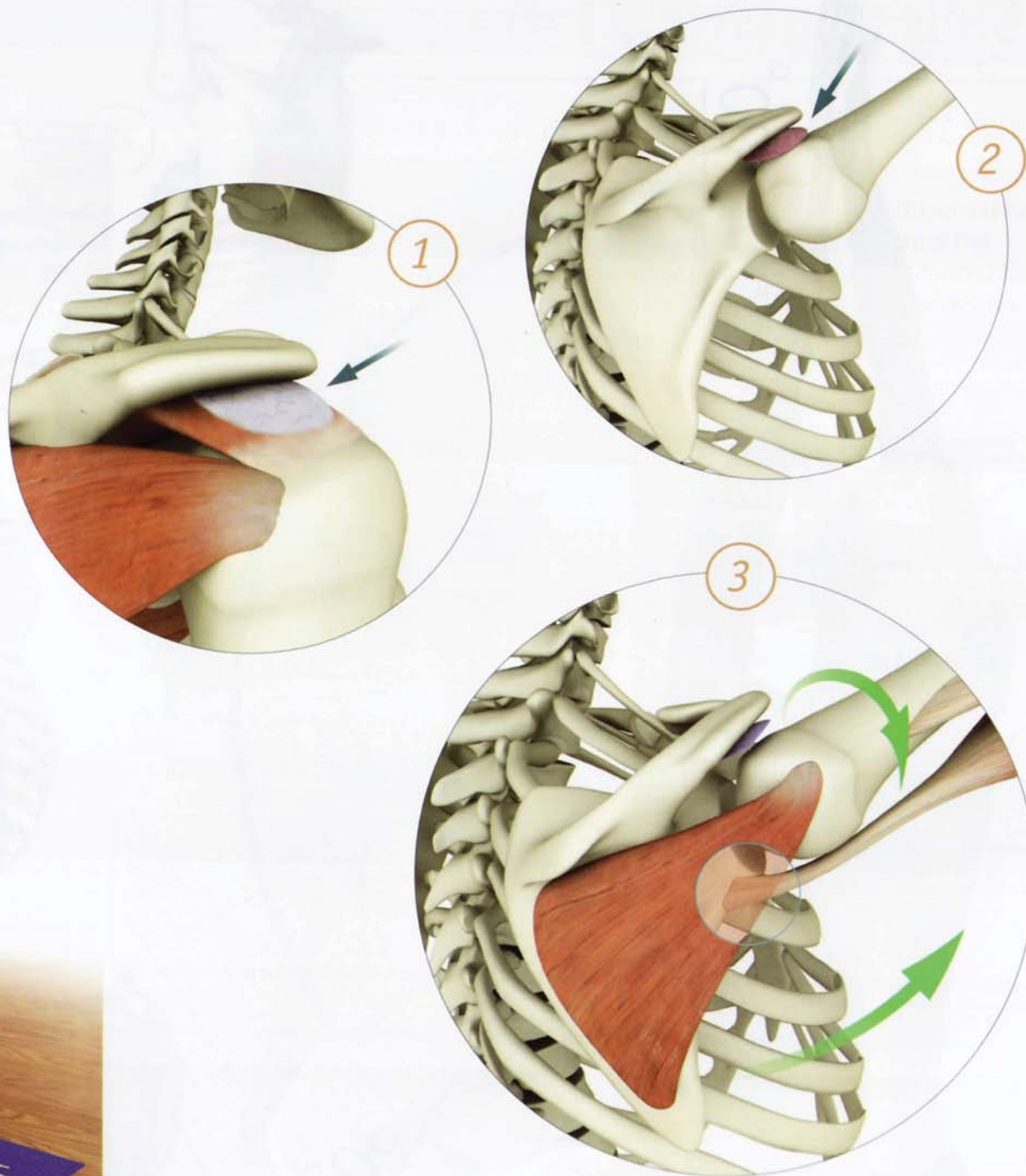
Gomukhasana B: The upper arm infraspinatus contracts, stretching the subscapularis. The lower arm subscapularis contracts, stretching the infraspinatus.

Subacromial Impingement

The subacromial bursa is a sac-like fluid-filled structure that facilitates the gliding of the rotator cuff under the acromion. Impingement involves compression of the subacromial bursa between the greater tuberosity of the humerus and the acromion. This can result in shoulder pain.


Contracting the infraspinatus externally rotates the humerus and draws the greater tuberosity away from the acromion. Contracting the long head of the triceps rotates the acromion towards the midline, away from the greater tuberosity. Combining contraction of both of these muscles creates space between the acromion and the greater tuberosity, assisting to prevent impingement of the bursa.

Contract these muscles to externally rotate the humerus and outwardly rotate the scapula when performing postures involving overhead movements.

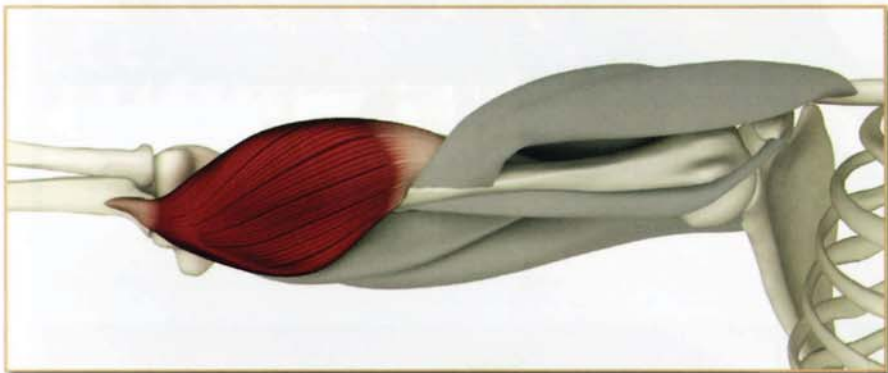


Chapter 18

Biceps Brachii



Biceps



Brachialis

This is a two-headed fusiform muscle. The short head originates from the coracoid (crow's beak) process of the scapula, near the insertion of the pectoralis minor. When the elbow is fixed, contracting the short head tilts the scapula forward. The long head originates from the top of the glenoid of the scapula, curving over the humeral head and into the bicipital groove, (a trough into which it is tethered by a ligament). Contracting the long head with the elbow fixed depresses the humeral head, stabilizing it in the joint.

Both heads combine to form one tendon inserting on the bicipital tuberosity of the radius. When the biceps contract, the forearm rotates into supination (palm up) position. Further contraction flexes the elbow.

Tightness in this muscle limits poses such as purvottonasana. Weakness limits poses such as sarvangasana.

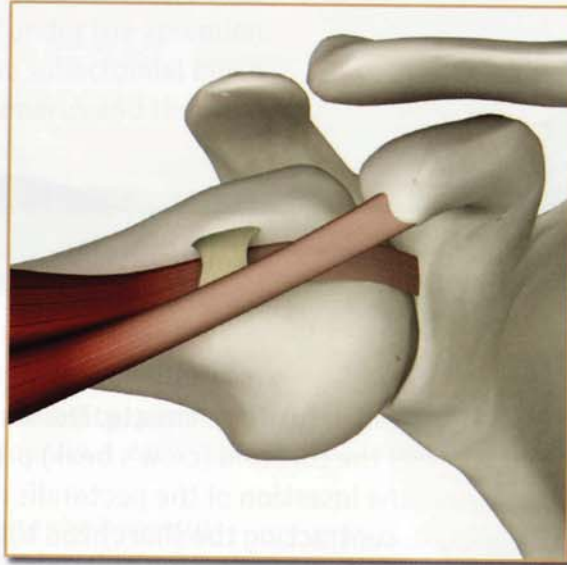
The brachialis muscle acts in synergy with the biceps, flexing the elbow.

Biceps Brachii (BI-seps BRA-ke-I)

Origin

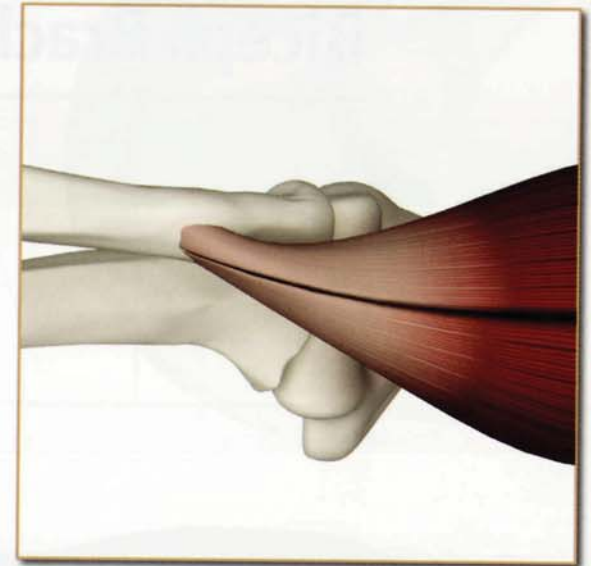Long Head: Supraglenoid tubercle.

Short Head: Tip of coracoid process of the scapula.



Insertion

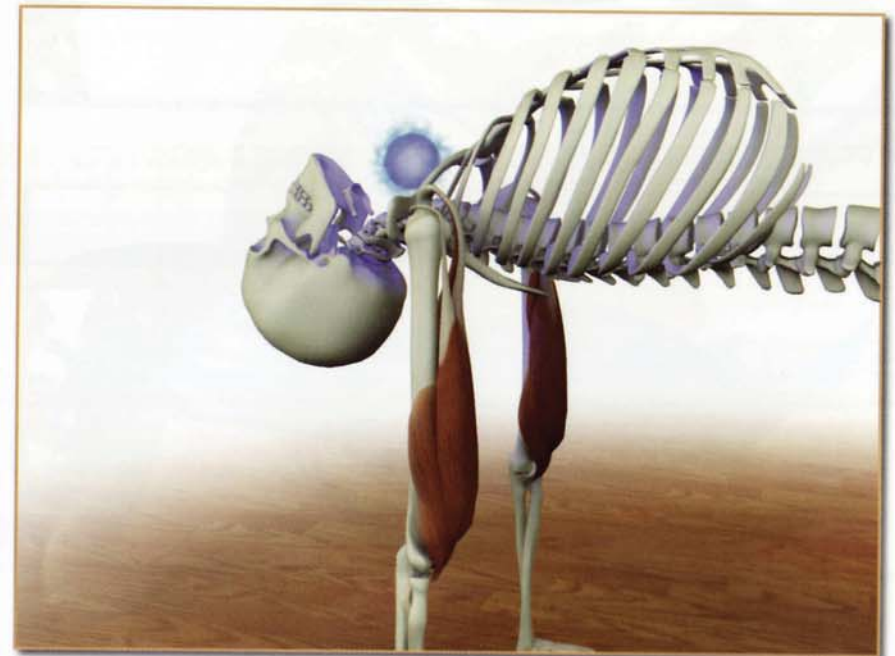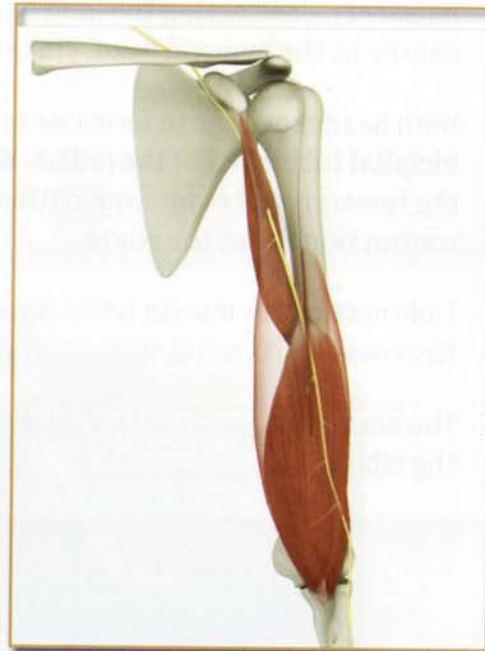Radial tuberosity.



Innervation & chakra illuminated

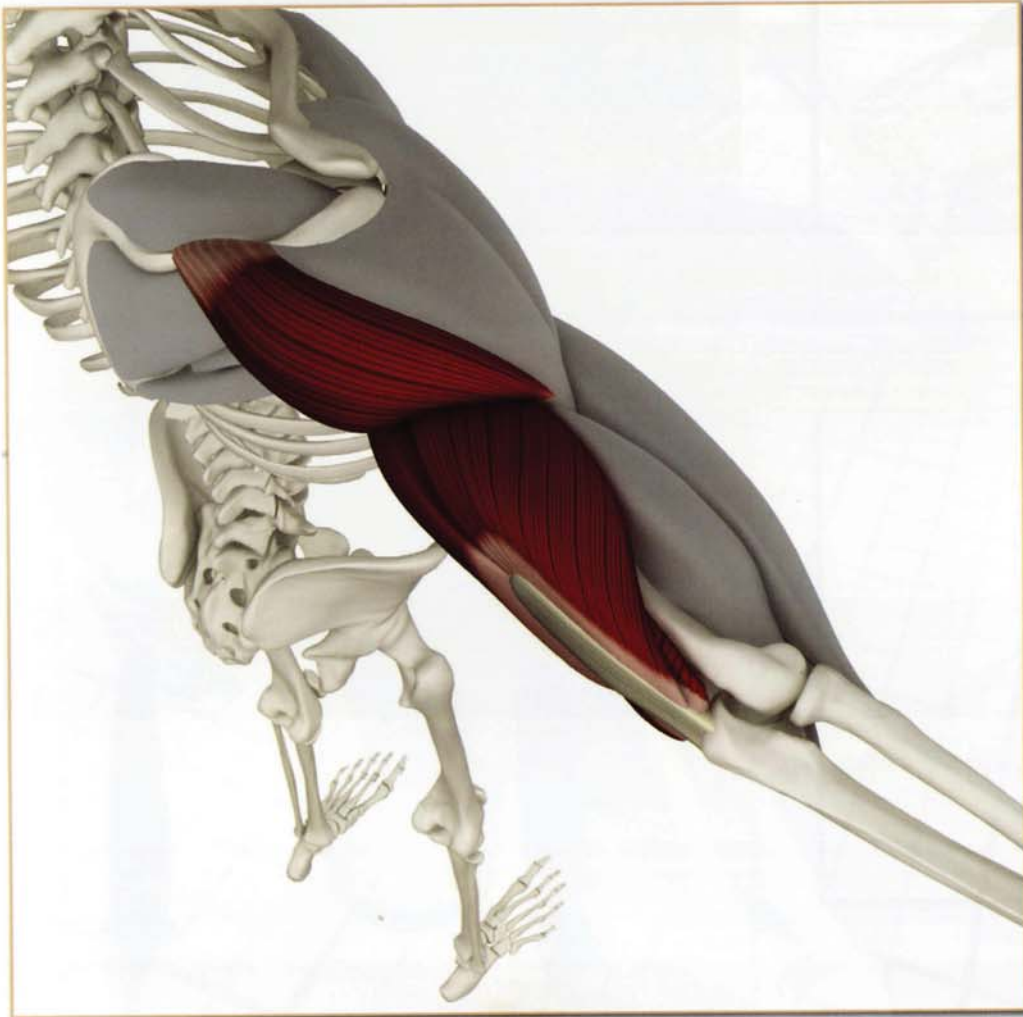
Musculocutaneous nerve (cervical nerves 5 and 6)

Chakra illuminated: Fifth



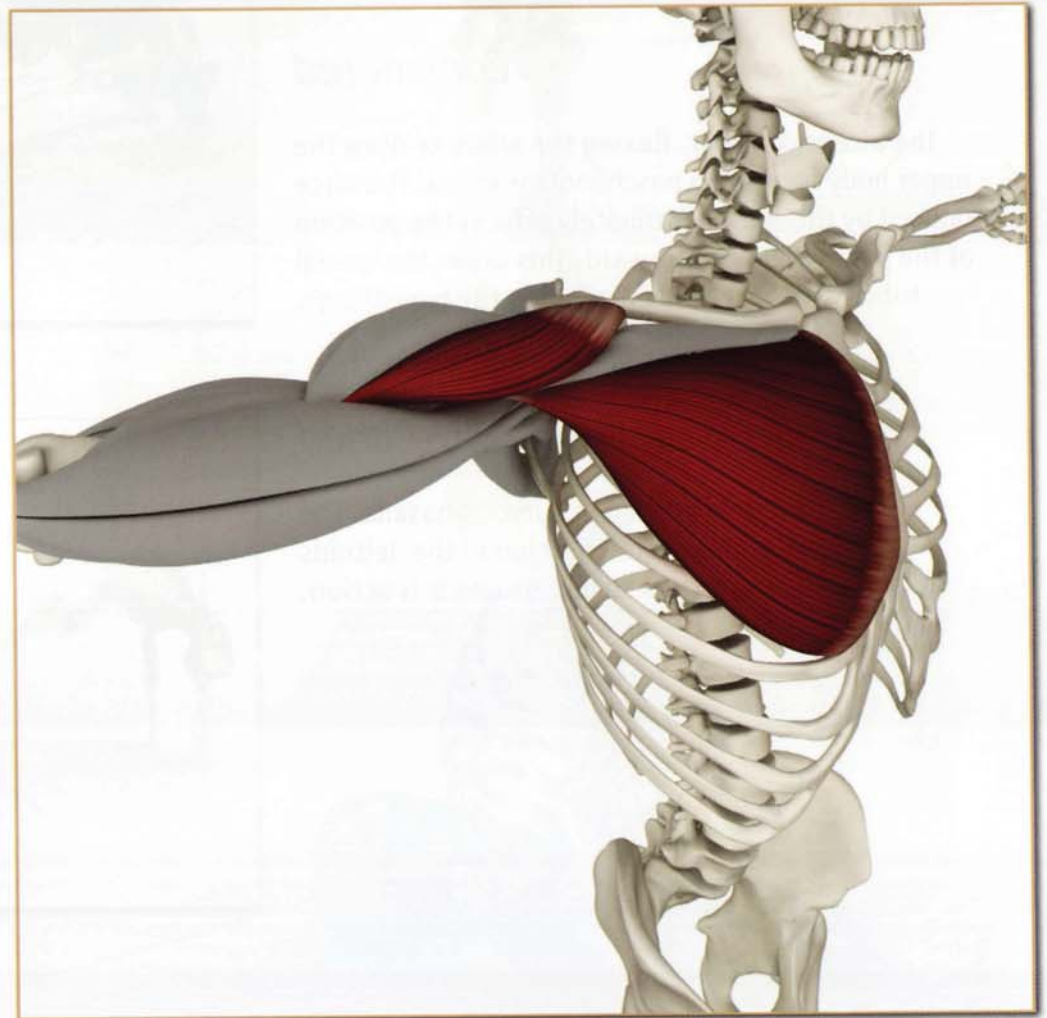
Antagonists

Triceps and deltoid (posterior section).



Synergists

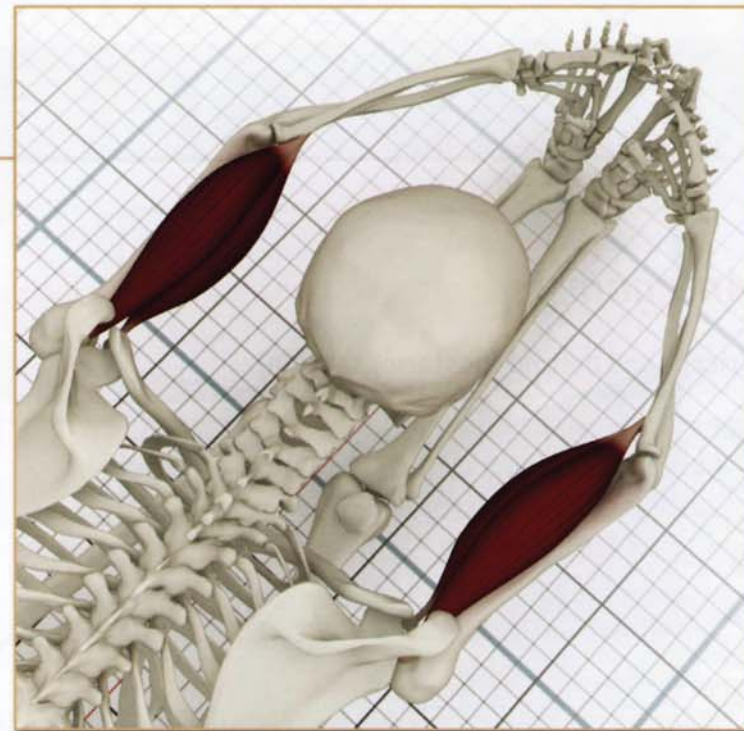
Deltoid (anterior section) and pectoralis major (sternocostal portion).



Biceps Brachii (BI-seps BRA-ke-I)

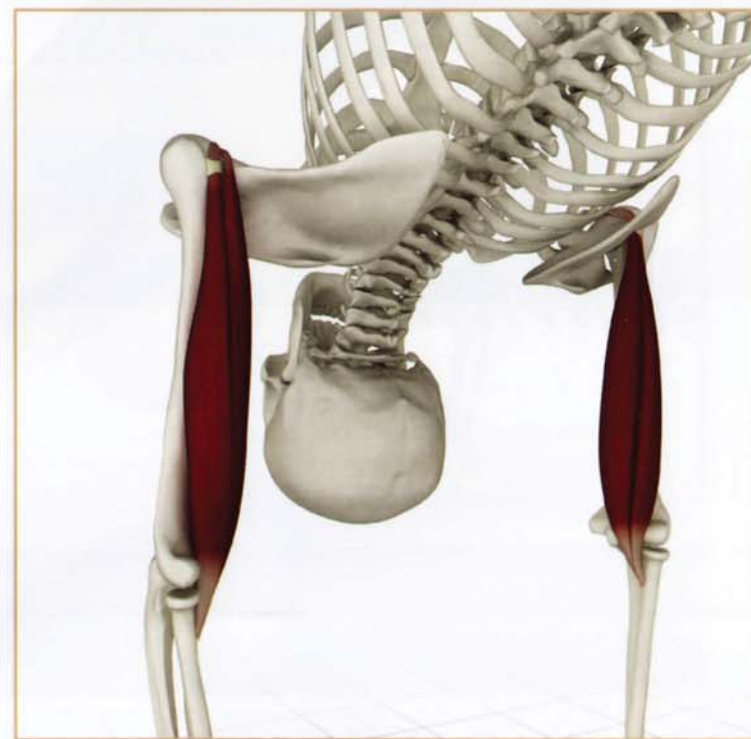Contracted

The biceps contract, flexing the elbow to draw the upper body forward in paschimottanasana. The force produced by this action ultimately affects the position of the pelvis, tilting it forward. This draws the ischial tuberosity backward, stretching the hamstrings.



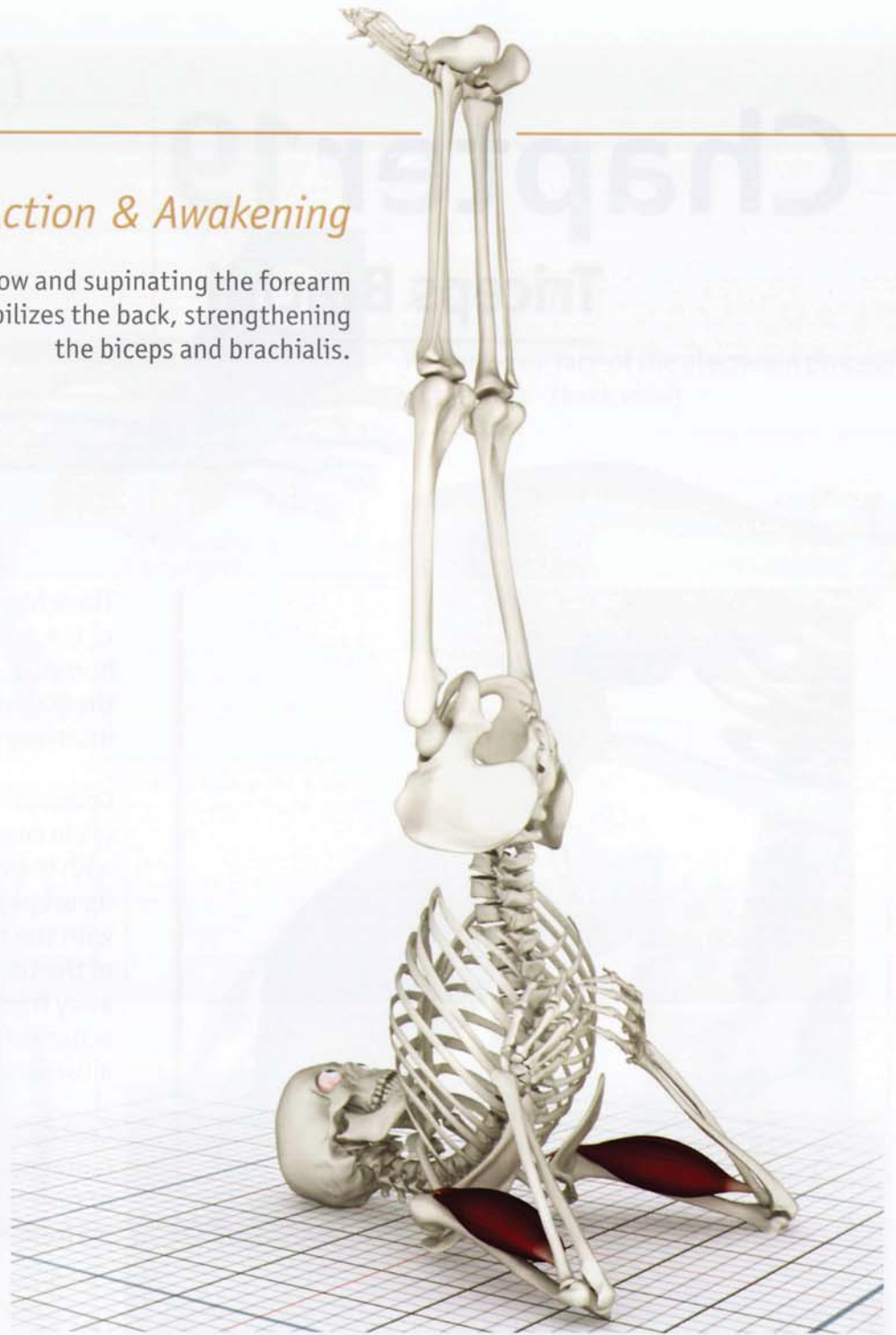
Stretched

The biceps stretch in purvottanasana. The triceps and posterior section of the deltoids contract to accentuate this action.



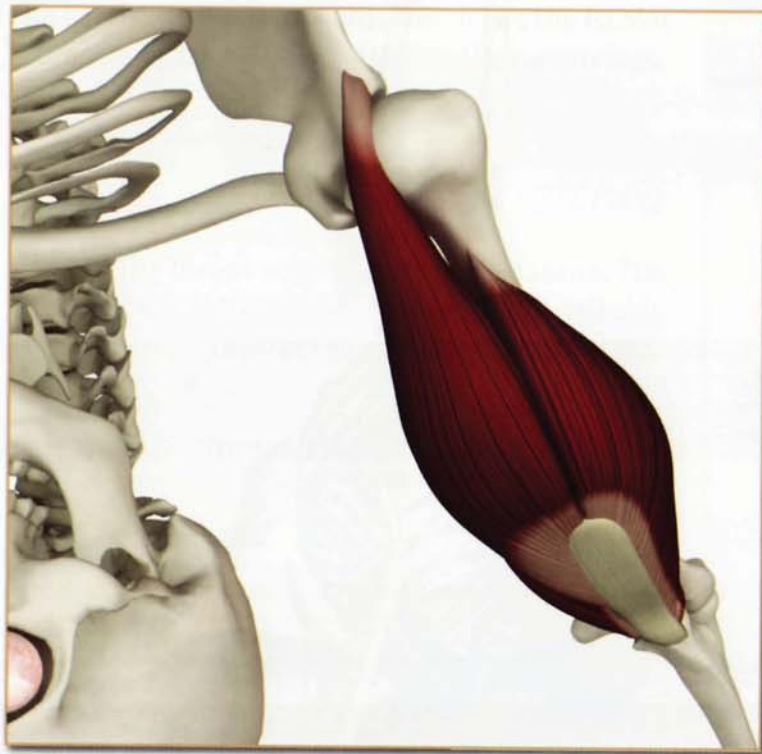
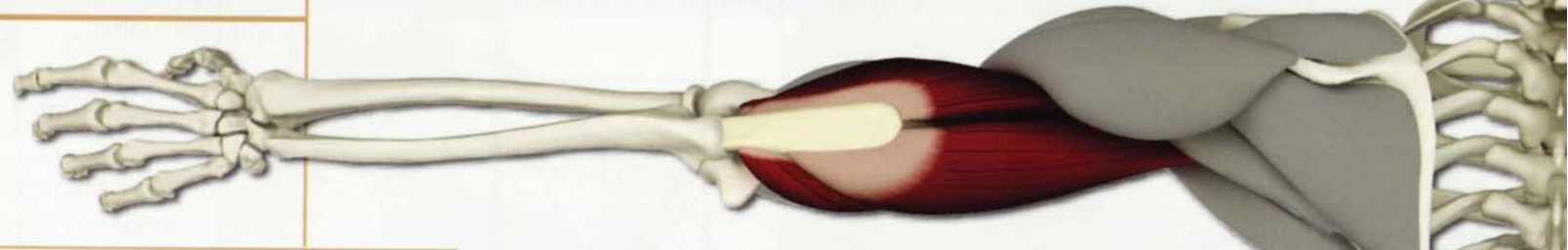
Action & Awakening

The biceps contract, flexing the elbow and supinating the forearm in sarvangasana. This action stabilizes the back, strengthening the biceps and brachialis.



Chapter 19

Triceps Brachii



The triceps brachii presents a three-headed muscle on the back of the arm. The medial and short heads originate from the humerus. The long head originates from the inferior border of the glenoid. All three heads combine to form one distal tendon, inserting on the olecranon process of the ulna (forearm bone).

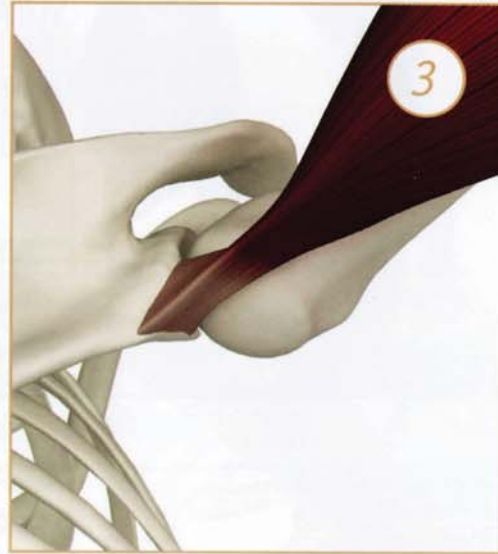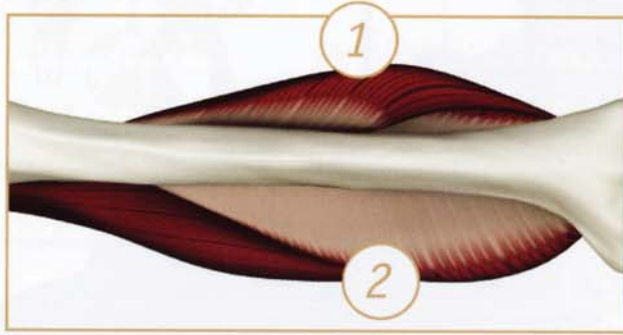
Contraction of all three heads produces extension of the elbow (as in downward facing dog pose). Contraction of the long head with the forearm fixed rotates the scapula upward (by pulling on its origin). This rotation increases contact of the humeral head with the shallow glenoid, stabilizing the joint. This contraction of the triceps also moves the acromion process medially and away from the humeral head, preventing impingement of the acromion on the humeral head. This protects the rotator cuff muscles in poses like the backbend and dog.

Contraction of the triceps opens the front of the elbow (antebrachial fossa) and relieves blockages in the minor chakra of the elbow. Weakness in the triceps limits the ability to perform the various arm balancings.

Triceps Brachii (TRI-seps BRA-ke-I)

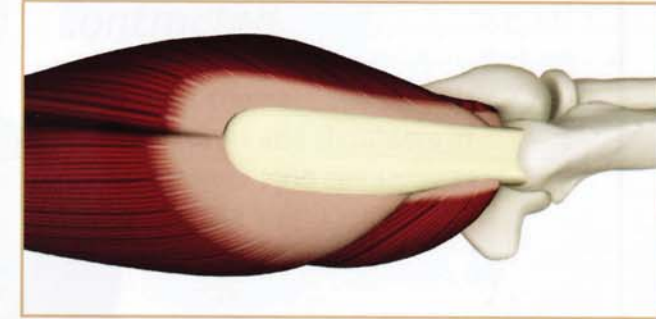
Origin

- 1) *Lateral Head*: Upper half of the posterior surface of humeral shaft.
- 2) *Medial Head*: Posterior shaft of the humerus, distal to the radial groove.
- 3) *Long Head*: Infraglenoid tubercle of the scapula. (looking into the armpit)



Insertion

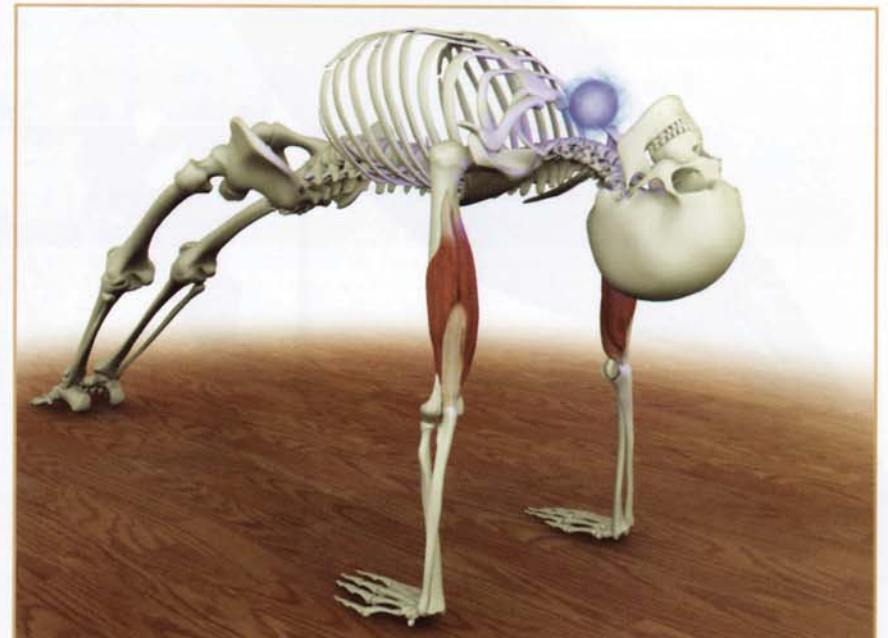Posterior surface of the olecranon process of the ulna. (back view)



Innervation & chakra illuminated

Radial nerve (cervical nerves 7 and 8).

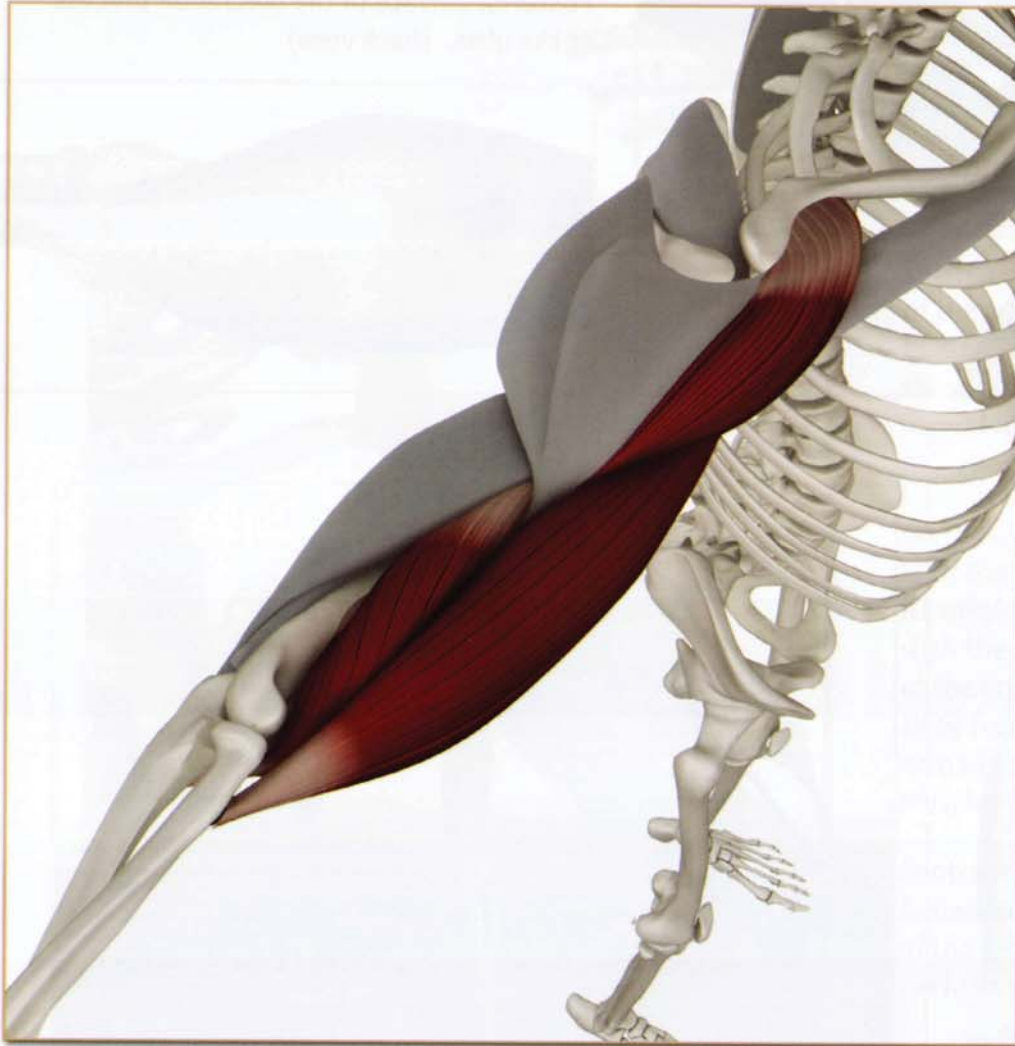Chakra illuminated: Fifth



Triceps Brachii (TRI-seps BRA-ke-I)

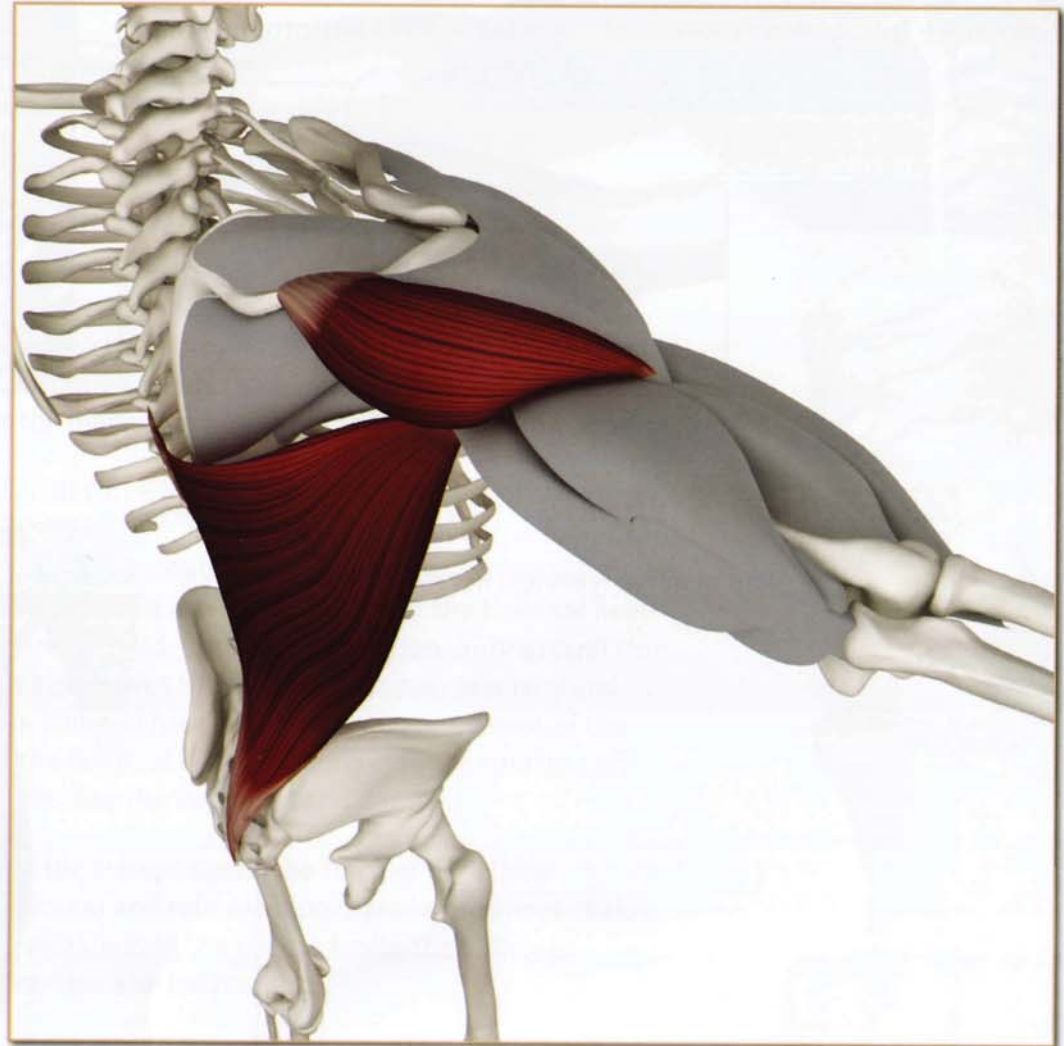
Antagonists

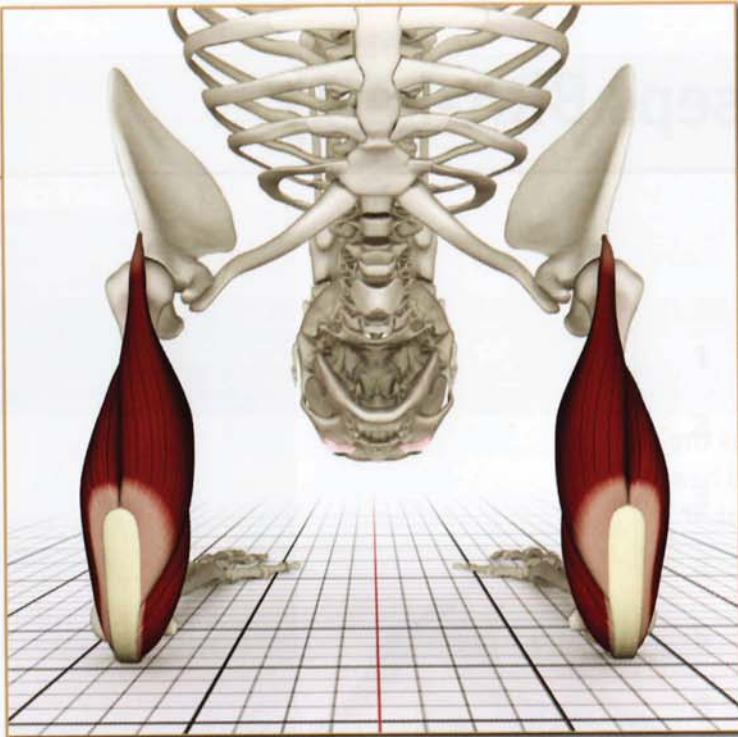
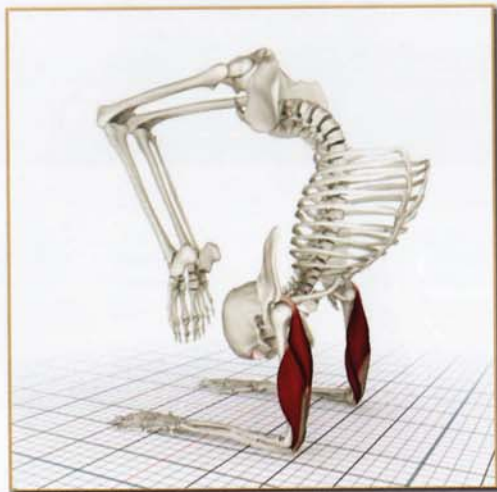Biceps and deltoid (anterior section).



Synergists

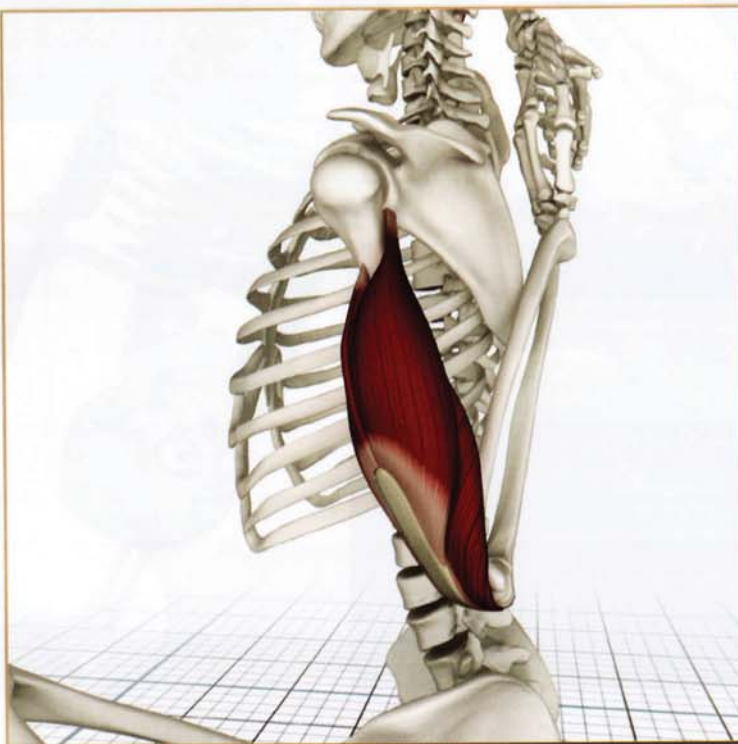
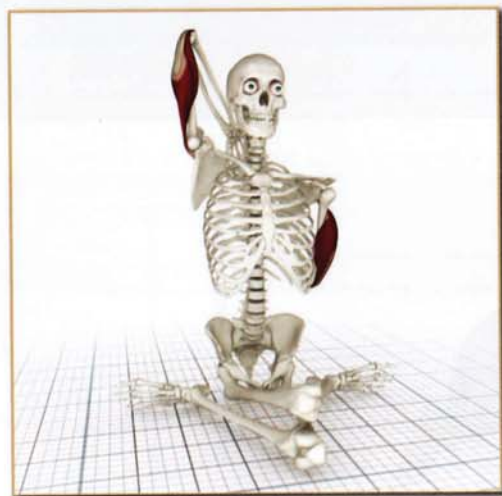Latissimus dorsi and deltoid (posterior section).





Contracted

The triceps contract and stabilize the upper arms and shoulders in vrischchikasana (and similar asanas such as pincha mayurasana).



Stretched

The upper and lower arm triceps stretch in gomukhasana B.

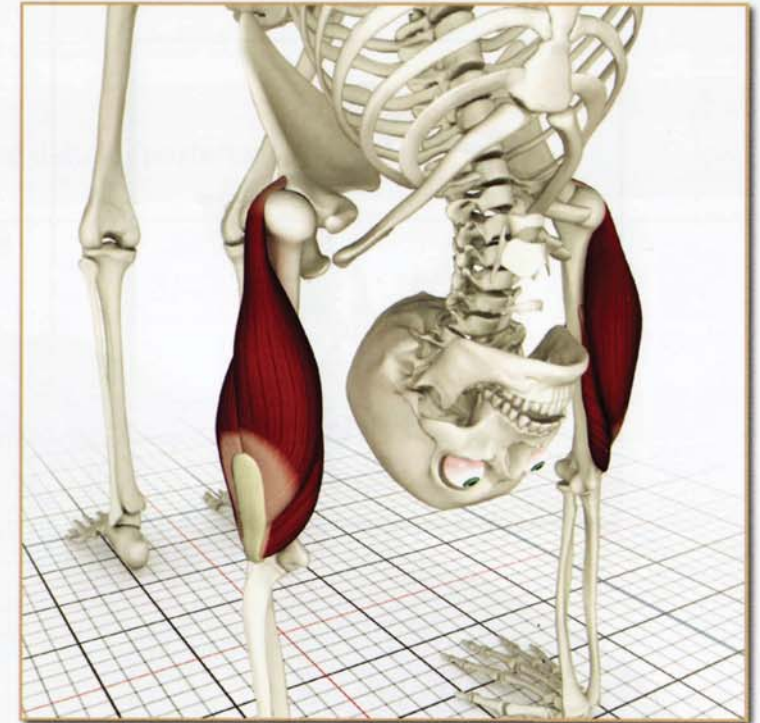
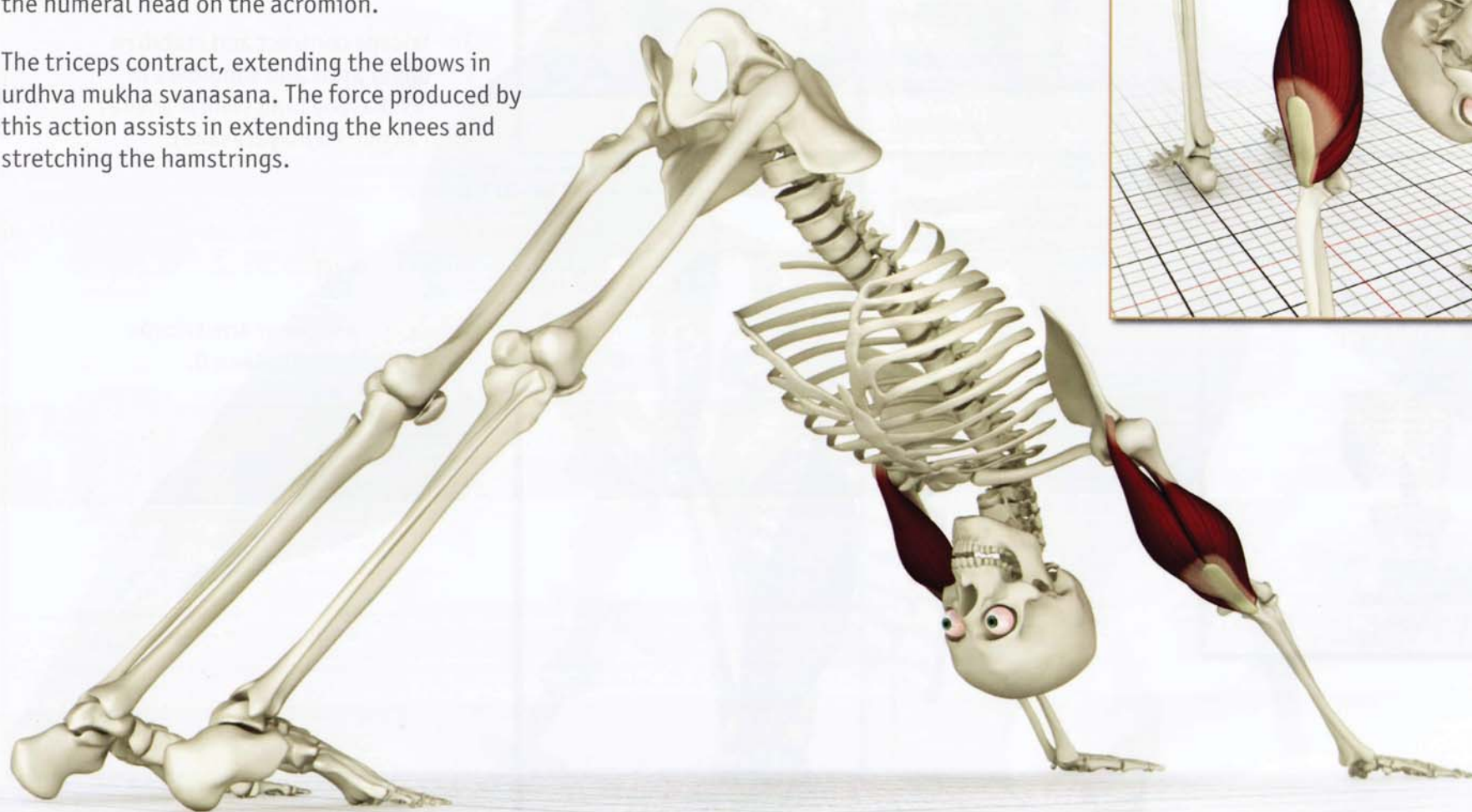Triceps Brachii (TRI-seps BRA-ke-I)

Action & Awakening


The triceps contract, extending the elbows in urdhvadhanurasana.

The long head of the triceps also upwardly rotates the scapula, increasing contact between the humeral head and the glenoid. This aids to prevent impingement of the humeral head on the acromion.

The triceps contract, extending the elbows in urdhva mukha svanasana. The force produced by this action assists in extending the knees and stretching the hamstrings.



Test your anatomy*



- 1 _____
- 2 _____
- 3 _____
- 4 _____
- 5 _____
- 6 _____

- 1 _____
- 2 _____
- 3 _____
- 4 _____



*Please see www.bandhayoga.com for answers...

Test your anatomy*



Action 8 Awakening

The cobra series
Awakening

The 2nd level of the
awakening, focusing
on the spine, the
the 5th level of the

The cobra series
without the hands
Awakening

- 1 _____
- 2 _____
- 3 _____
- 4 _____
- 5 _____
- 6 _____

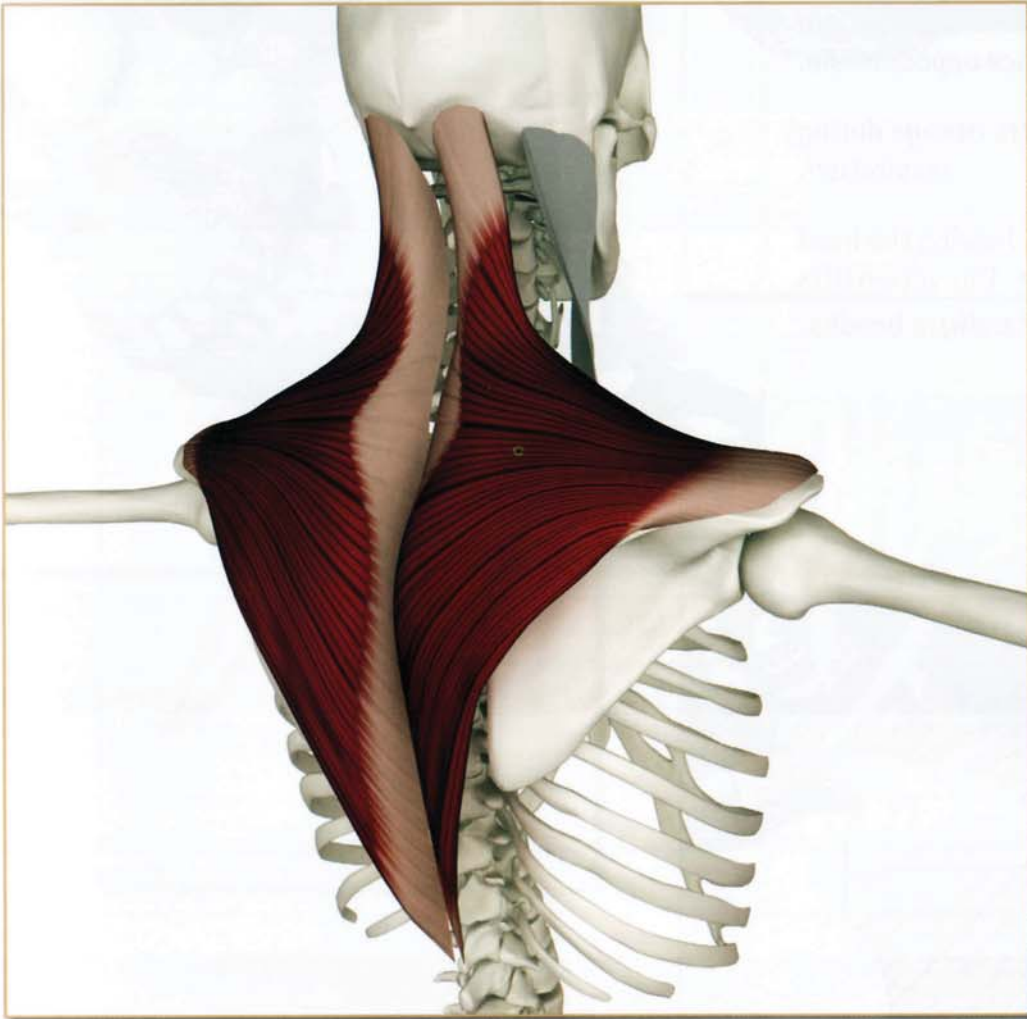


- 1 _____
- 2 _____
- 3 _____
- 4 _____
- 5 _____

*Please see www.bandhayoga.com for answers...

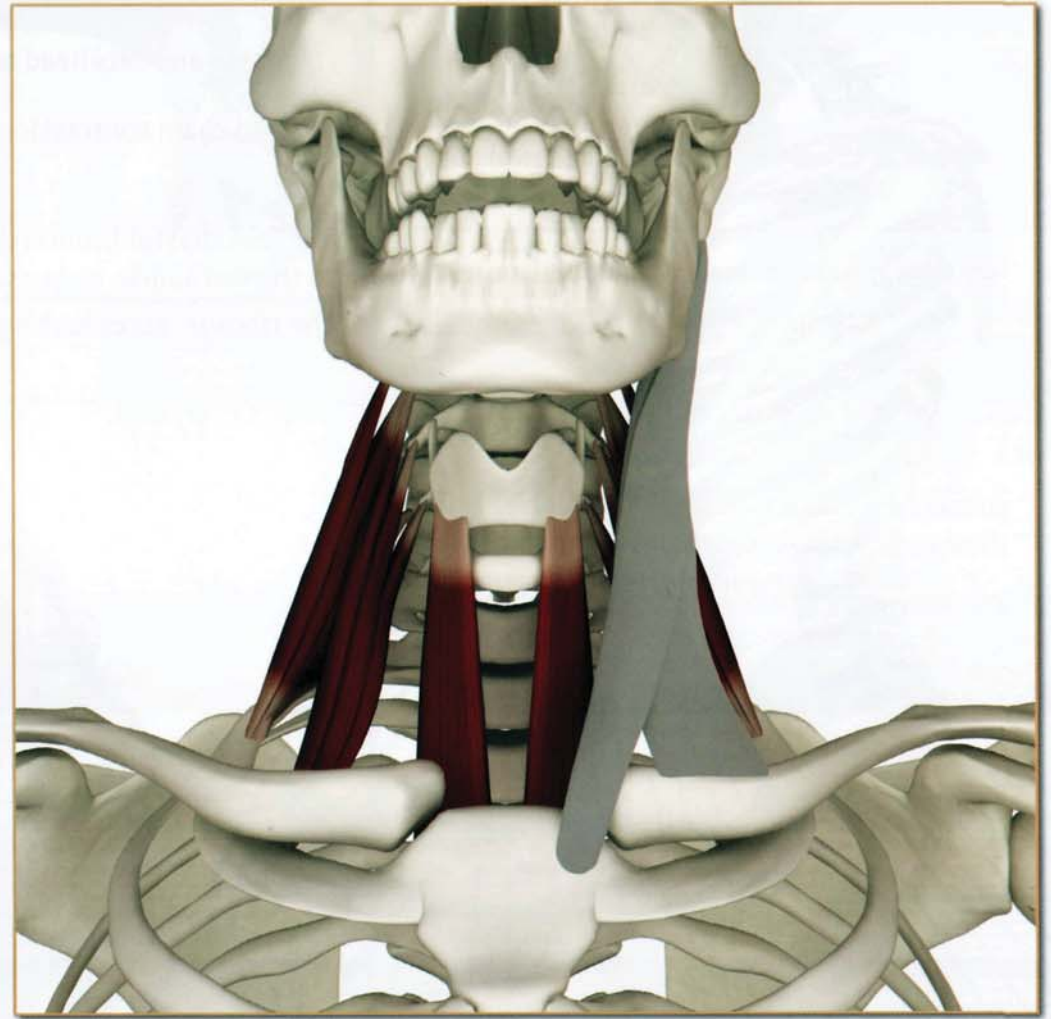
Antagonists

Trapezius and dorsal neck muscles.



Synergists

Longus colli and longus capitus.



Sternocleidomastoid (ster-no-kli-do-MAS-toid)

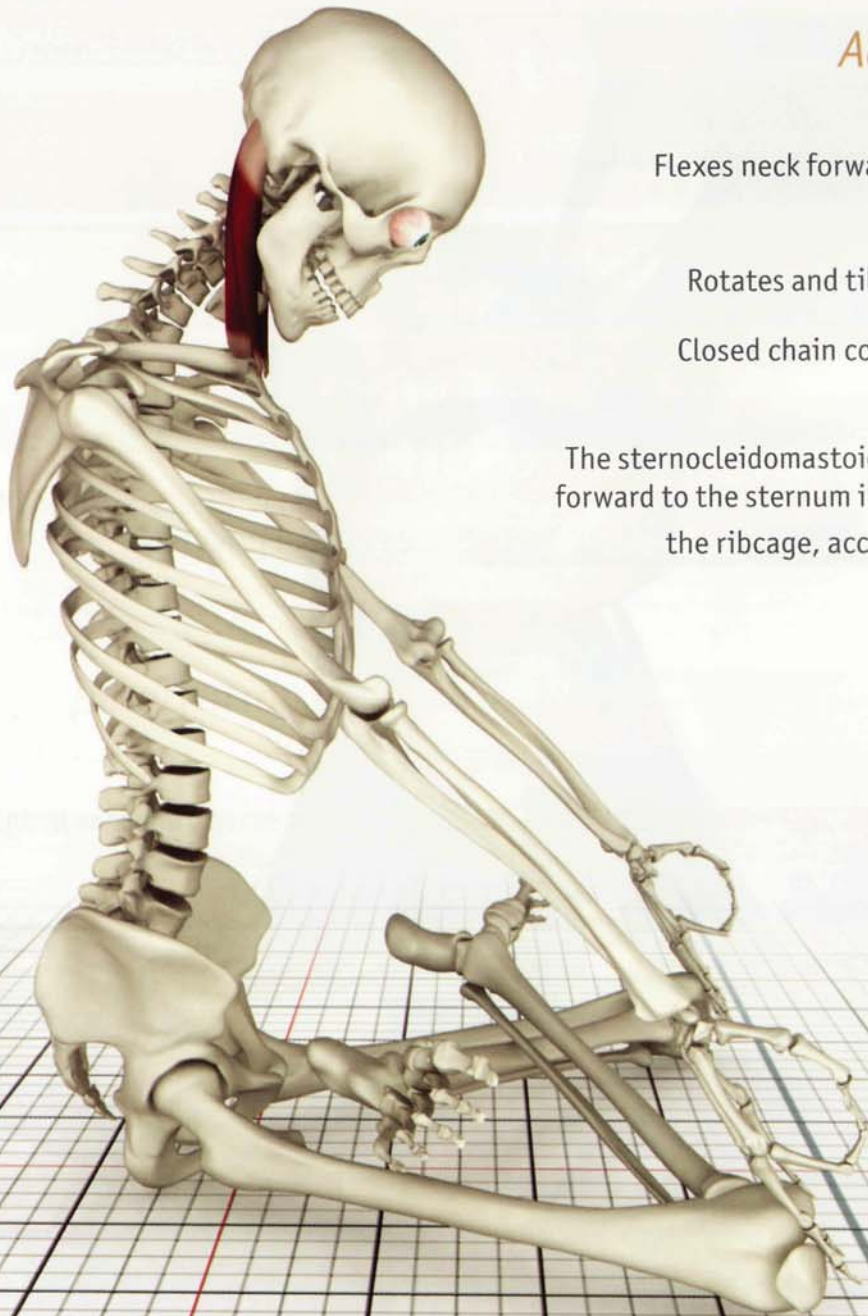
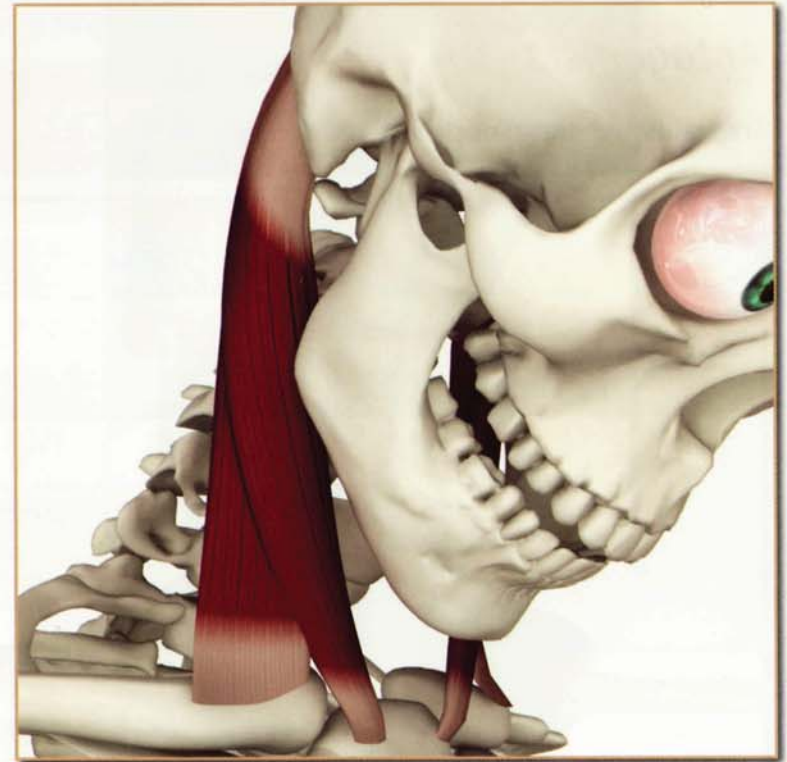Action & Awakening

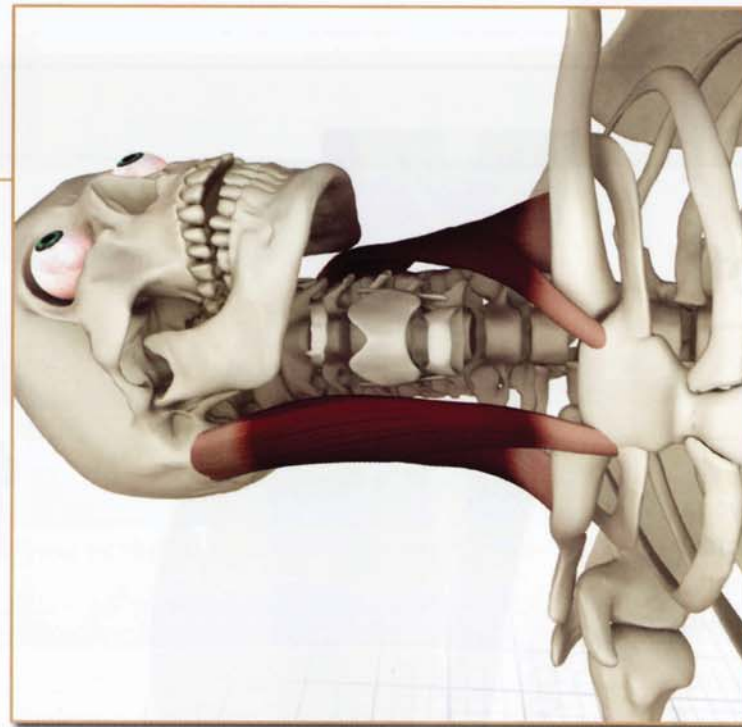
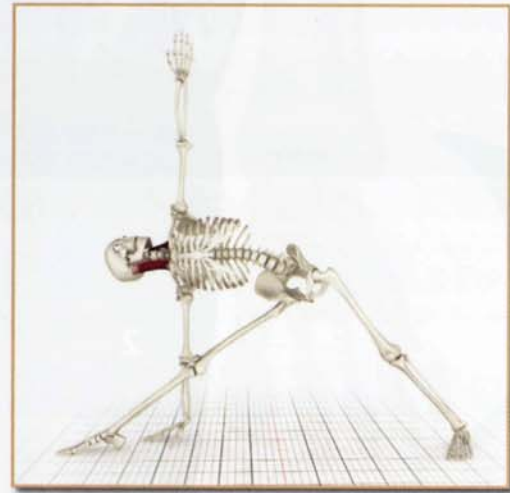
Bilateral contraction:
Flexes neck forward and draws chin downward.

Unilateral contraction:
Rotates and tilts head to face opposite side.

Closed chain contraction lifts ribcage during
respiration.

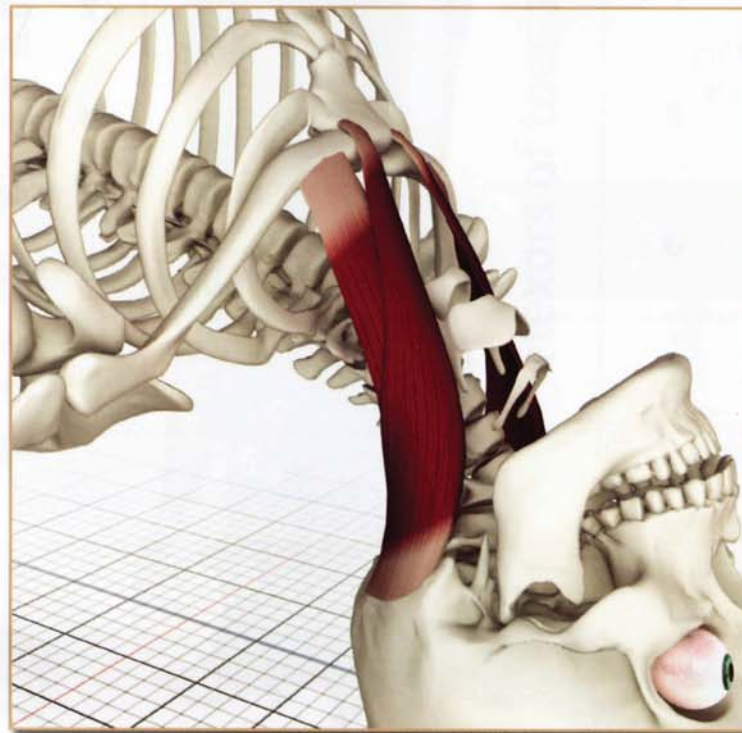
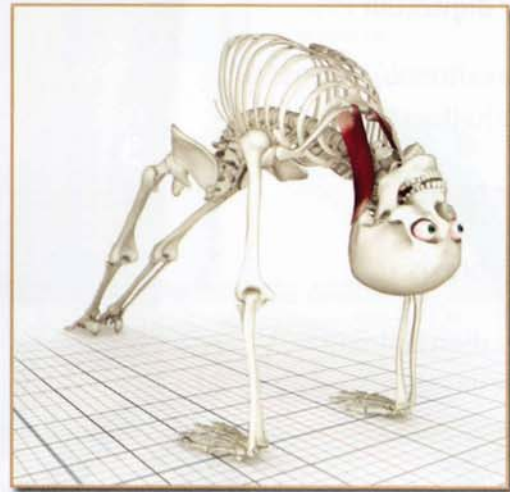
The sternocleidomastoid contracts, drawing the head forward to the sternum in padmasana. This action lifts the ribcage, accentuating jalandhara bandha.





Contracted

The lower side sternocleidomastoid contracts in utthita trikonasana, lengthening the upper side sternocleidomastoid and turning the head.



Stretched

The dorsal neck muscles and upper trapezius contract in purvottanasana, stretching both sternocleidomastoid muscles.

Chapter 21

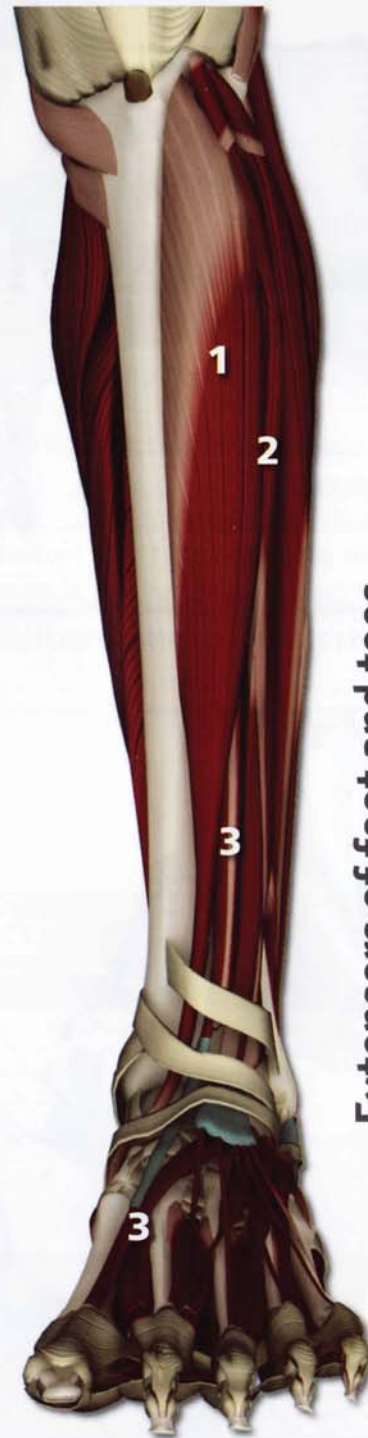Lower Leg and Foot

The lower leg and foot form the foundation for many yoga poses. For this reason it is important to have a functional understanding of the major muscles of the lower leg and foot. Minor chakras are present in the foot that contribute to illuminating the first and second major chakras.

For ease of understanding it is useful to divide the many muscles in this region into groups identified by their function.

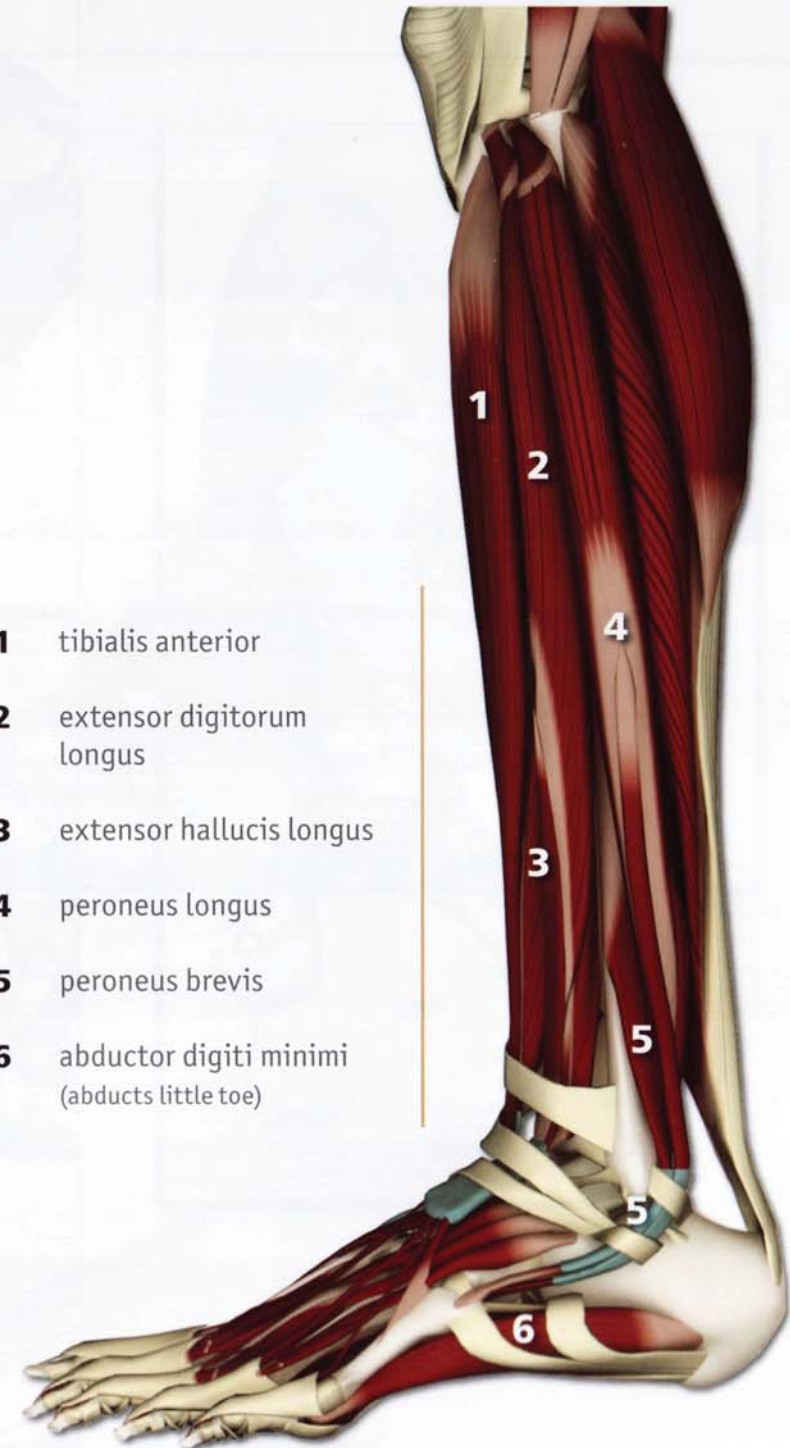The major functions include flexing, extending, everting and inverting the foot. In the foot itself the muscles are categorized into flexors and extensors of the toes.

These illustrations demonstrate the major muscles performing these actions.

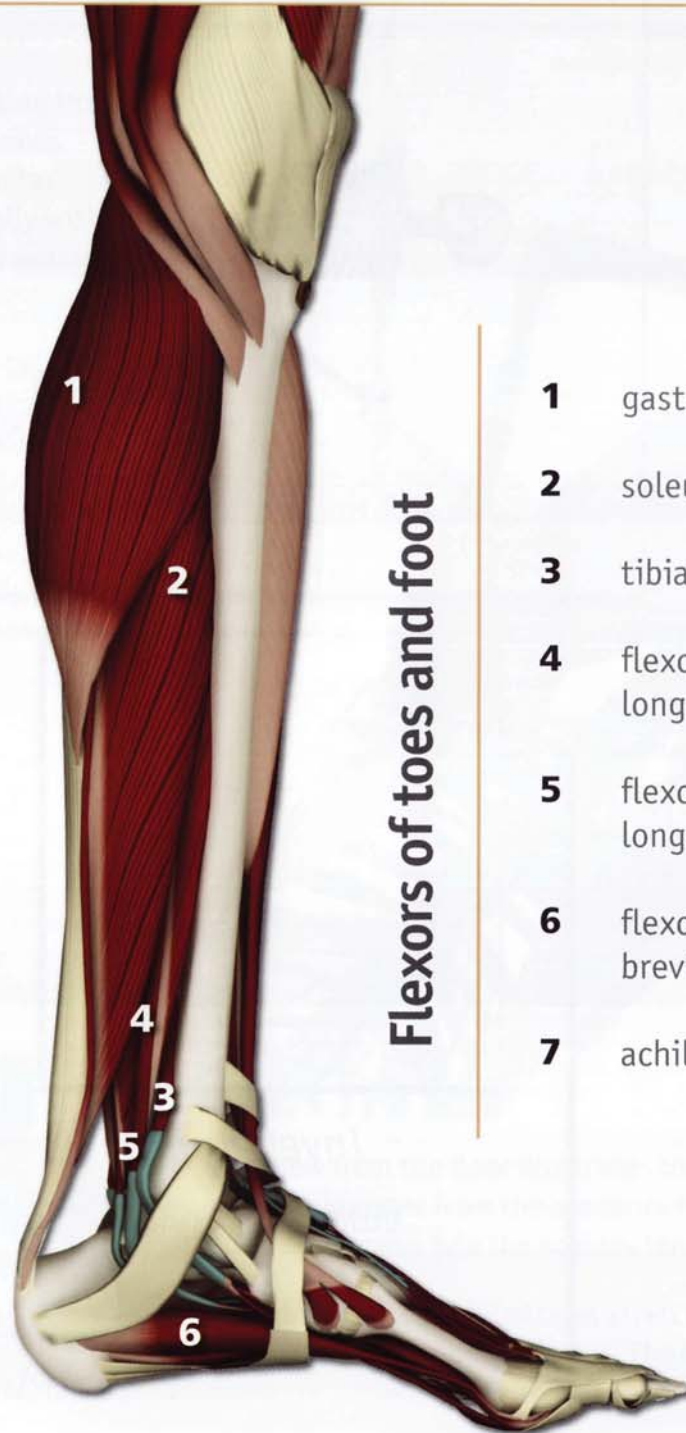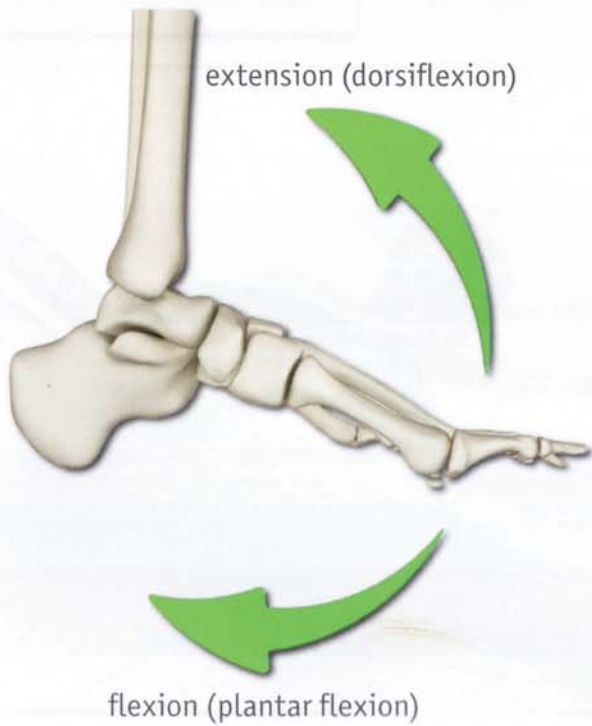
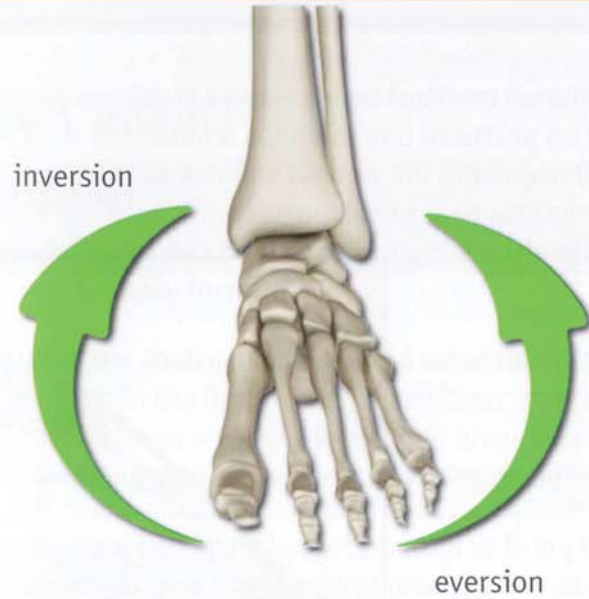


Extensors of foot and toes

- 1 tibialis anterior
- 2 extensor digitorum longus
- 3 extensor hallucis longus
- 4 peroneus longus
- 5 peroneus brevis
- 6 abductor digiti minimi (abducts little toe)

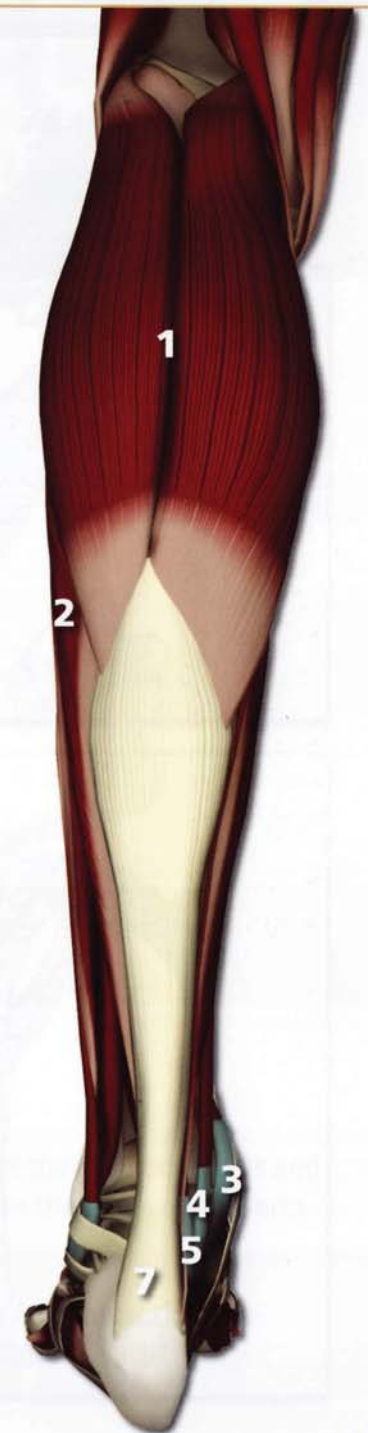


Lower Leg and Foot



Flexors of toes and foot

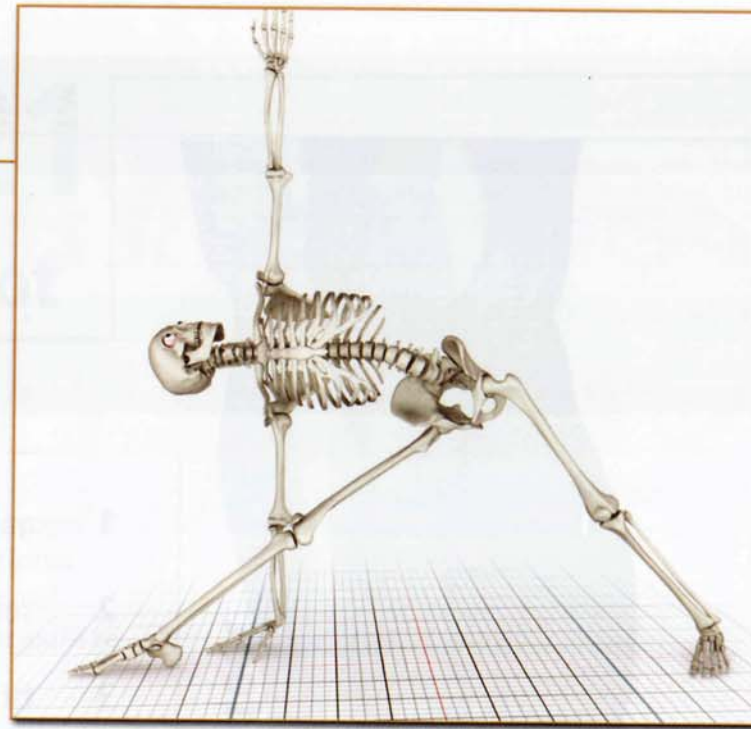
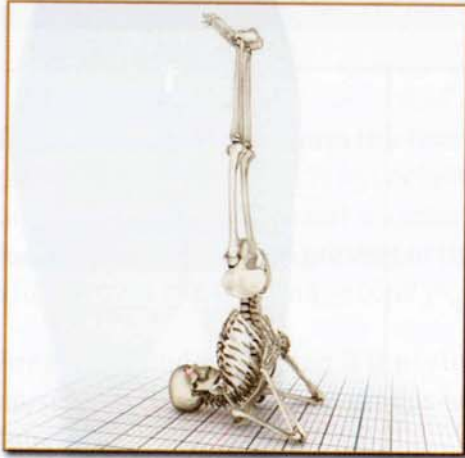
- 1 gastrocnemius
- 2 soleus
- 3 tibialis posterior
- 4 flexor digitorum longus
- 5 flexor hallucis longus
- 6 flexor hallucis brevis
- 7 achilles tendon



Movement: Foot

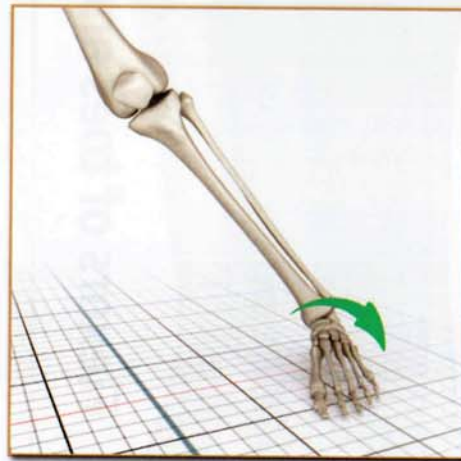
Eversion

Sarvangasana



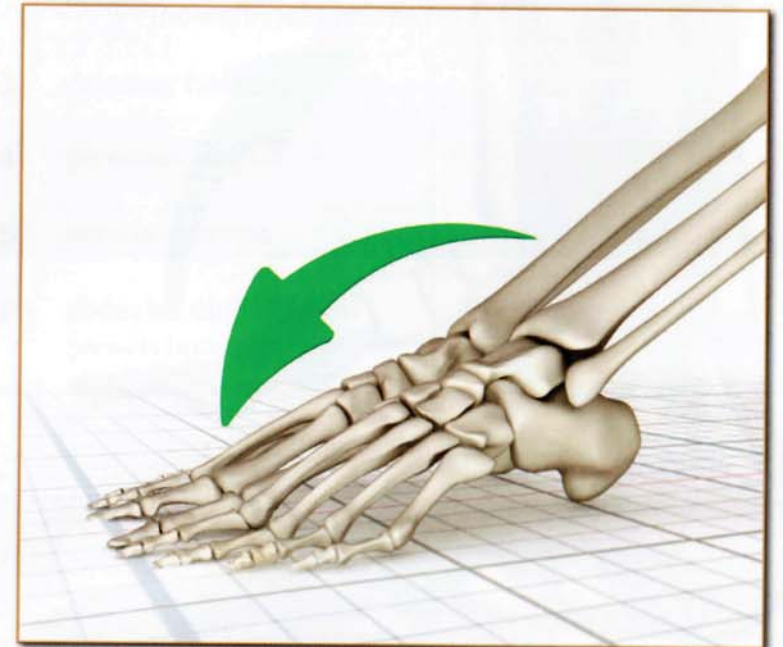
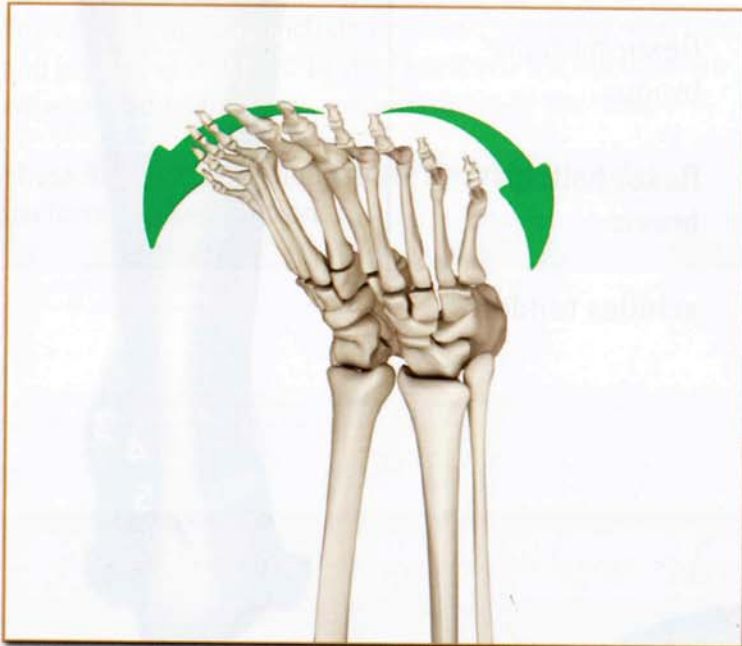Plantar Flexion

Purvottonasana



Inversion

Utthita Trikonasana



Gastrocnemius

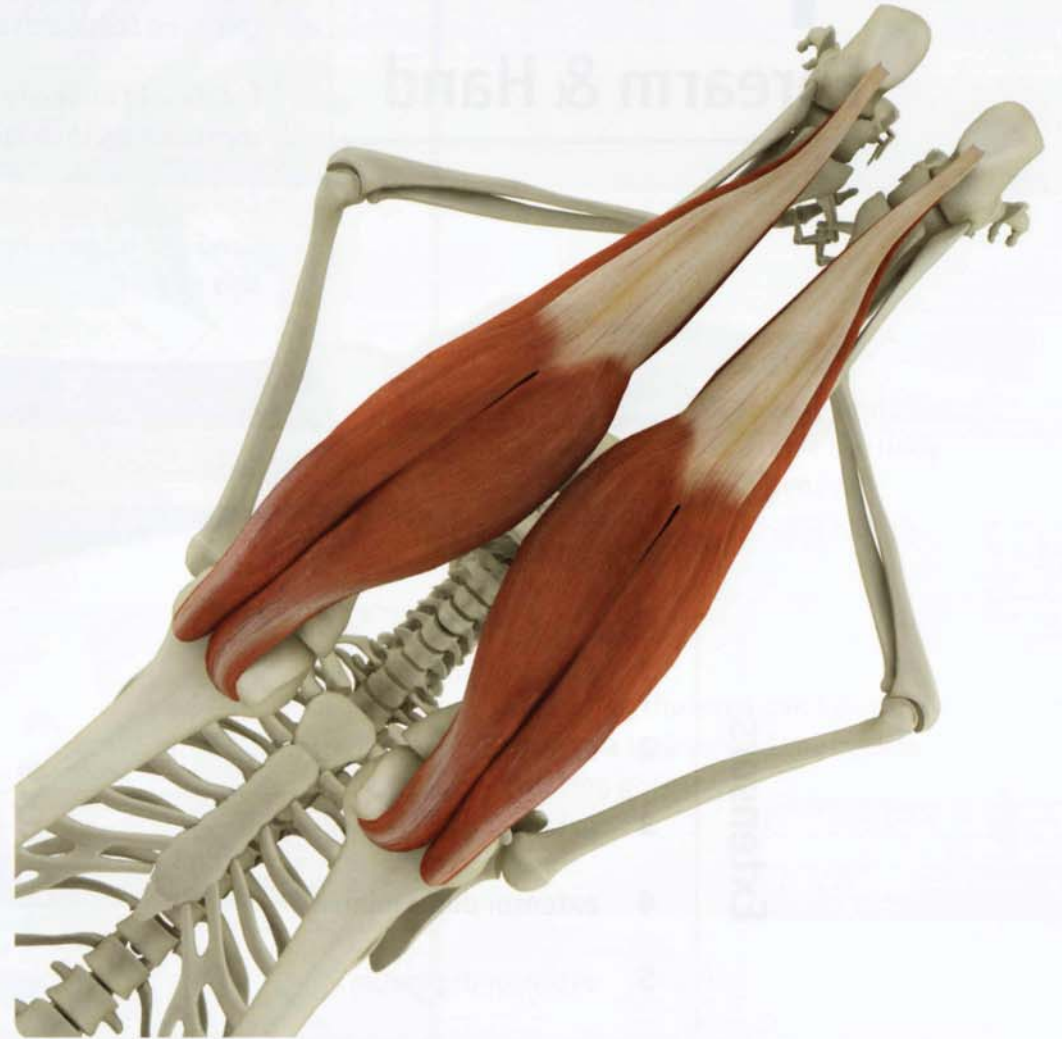The gastrocnemius is a two-headed fusiform muscle originating from the backs of the femoral condyles and inserting on the calcaneus (heel bone) via the Achilles tendon. Its primary action is plantar flexion of the foot. The gastrocnemius also acts synergistically with the hamstrings to flex the knee during the push-off phase of walking, propelling the body forward.

Tightness in the gastrocnemius limits extension of the knee (as with tightness in the hamstrings). Facilitated stretching of the gastrocnemius is an effective method to break through limitations in forward-bending postures where the knees straighten.

Use the forward bend *paschimottanasana* to bring the gastrocnemius out to full length and then resist plantar flexion of the feet by pulling them towards the head with the hands. Hold this for a few moments and then extend the knees and draw the feet upward.



paschimottanasana



This view from the floor illustrates the polyarticular nature of the gastrocnemius and how it originates from the posterior femoral condyles, crosses the knee, and inserts on the calcaneus (via the achilles tendon).

Paschimottanasana illustrates stretching the gastrocnemius by contracting the quadriceps to extend the knees. The hands dorsiflex the ankles.

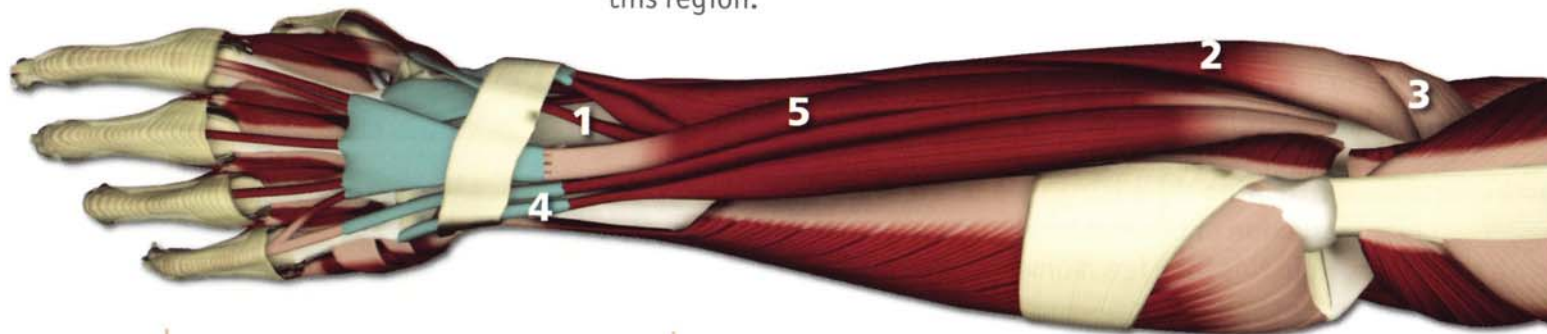Chapter 22

Forearm & Hand

The muscles of the forearm and hand connect the upper body with the lower body in yoga. They also stabilize the body in balancing poses and inversions. Minor chakras are present in the hand that contribute to illuminating the fourth and fifth major chakras.

For ease of understanding it is useful to divide the many muscles in this region into groups identified by their function.

The major functions include flexing and extending the wrist and complex movements of the hand and fingers. For the purpose of this chapter we illustrate the flexors and extensors of this region.



Extensors

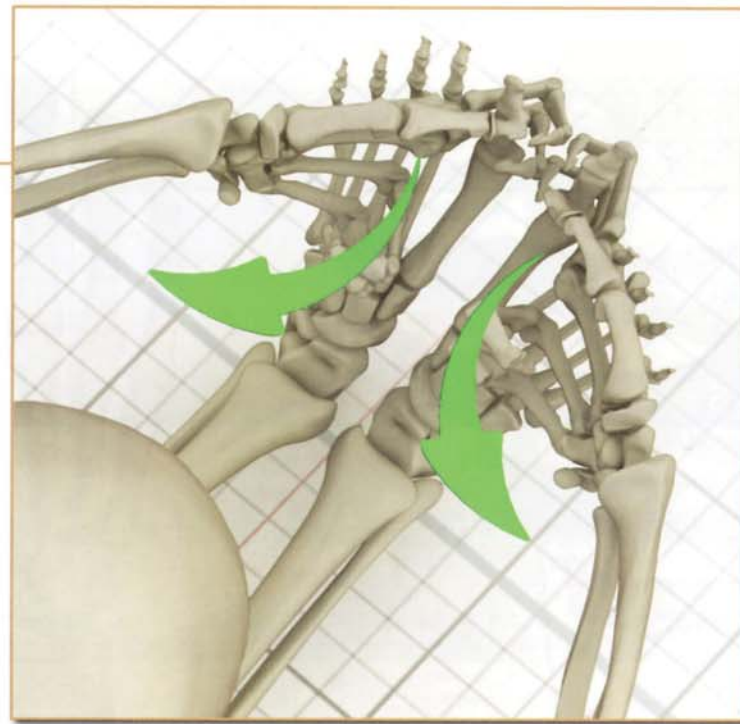
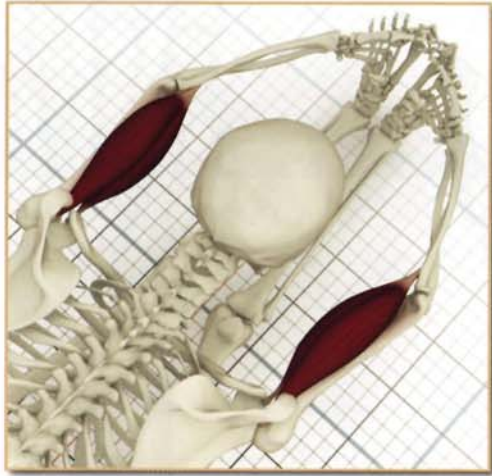- 1 extensor pollicis longus
- 2 extensor carpi radialis brevis
- 3 extensor carpi radialis longus
- 4 extensor digiti minimi
- 5 extensor digitorum

Flexors

- 6 flexor carpi ulnaris
- 7 flexor digitorum profundus
- 8 pronator teres
- 9 flexor digitorum superficialis
- 10 flexor carpi radialis

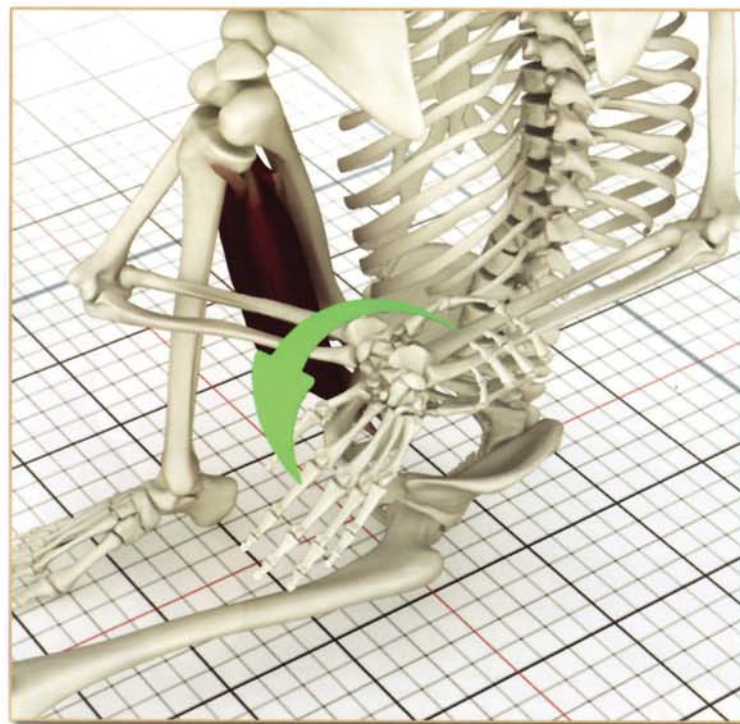



Movement



Flexed

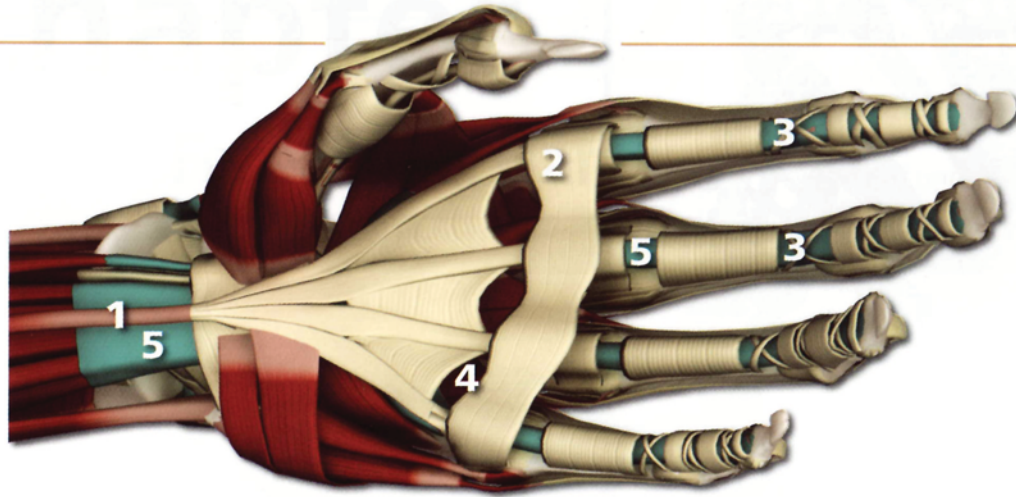
The fingers, wrist and forearms flex to grip the feet and draw the body deeper into forward bends.



Extended

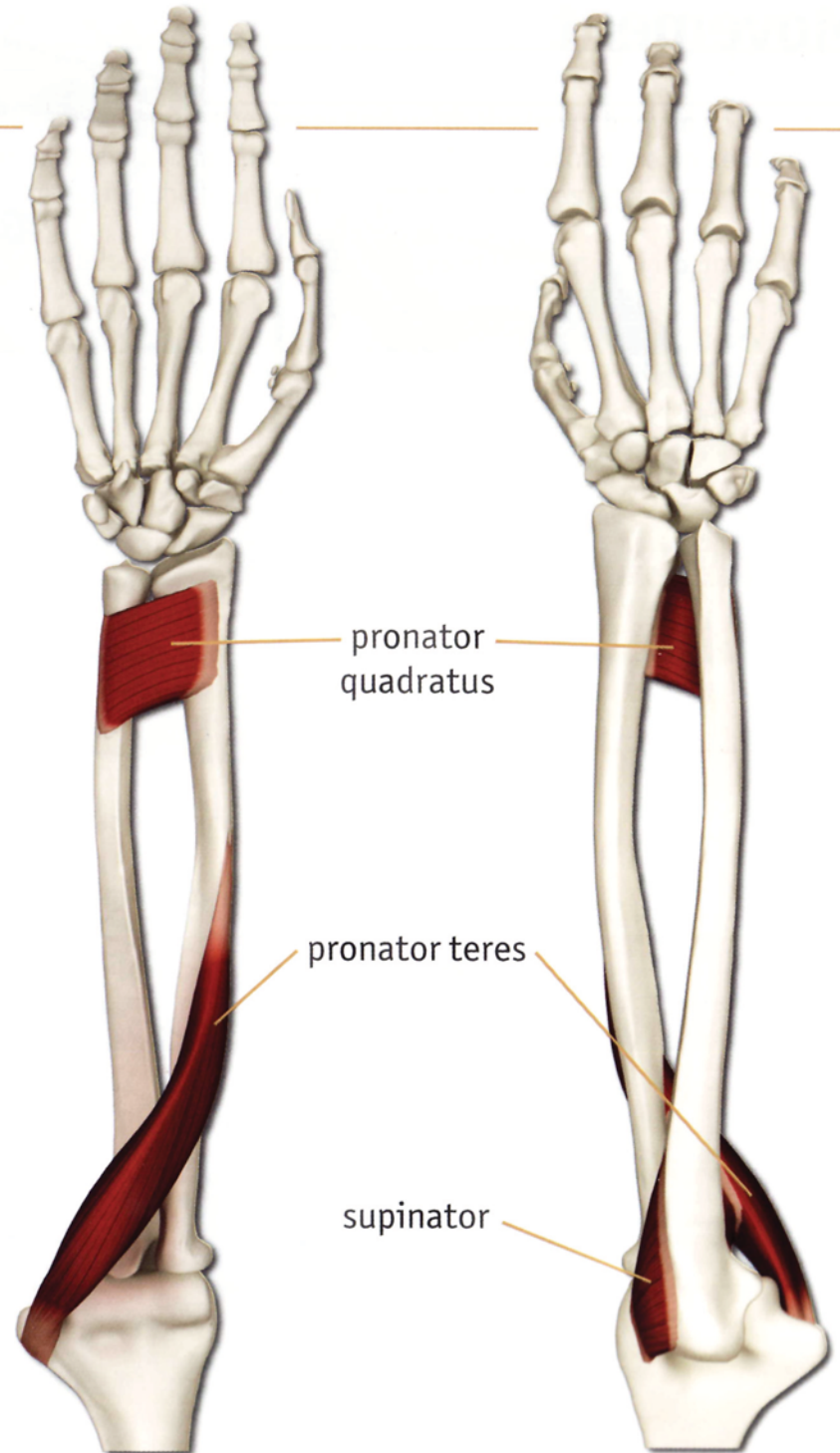
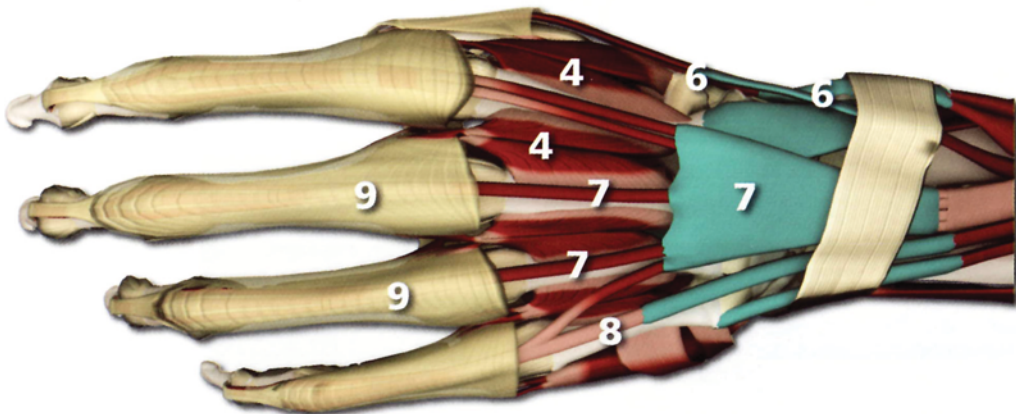
Extending the wrist can be used to form a lock behind the back in twisting poses.

Forearm & Hand



- 1** palmaris longus
- 2** palmar arch
- 3** flexor digitorum profundus
- 4** intrinsic muscles (adductors and abductors)

- 5** flexor digitorum superficialis
- 6** extensor and abductor pollicis
- 7** extensor digitorum
- 8** extensor digiti minimi
- 9** digital sheaths

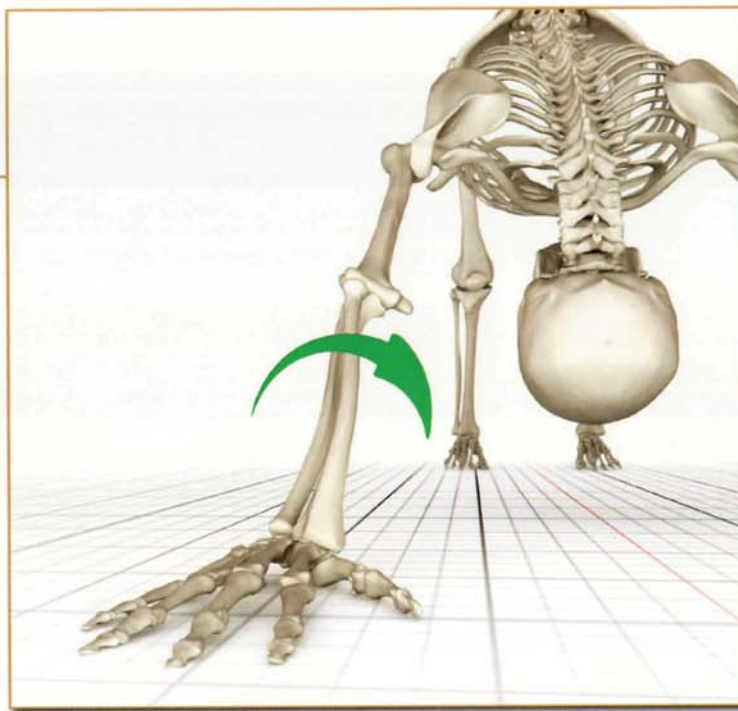



pronator quadratus

pronator teres

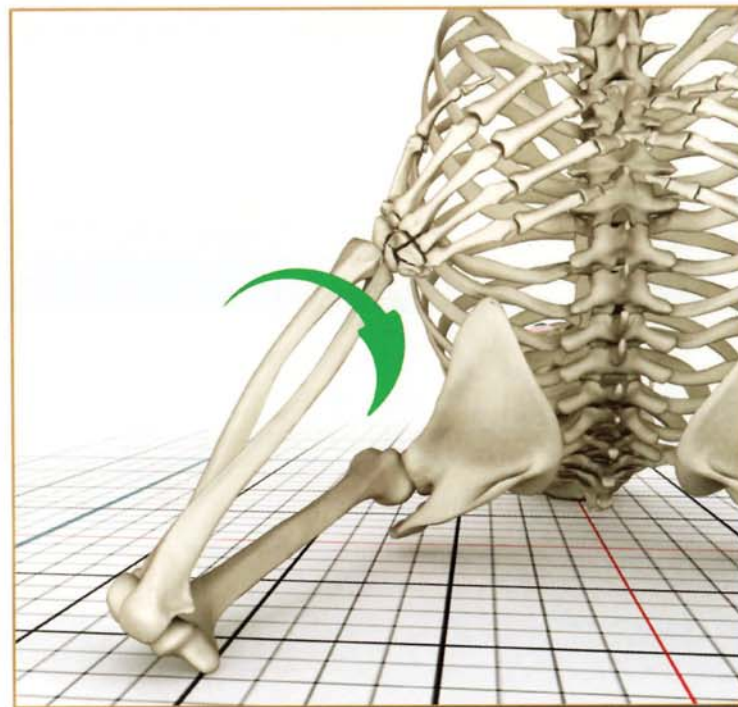
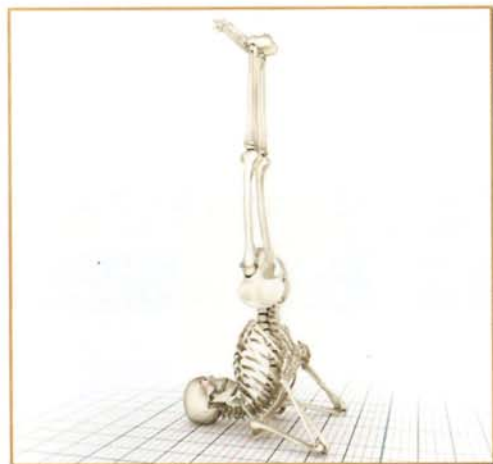supinator

Movement



Pronation

The pronator teres and pronator quadratus muscles of the forearm contract, turning the palm down.



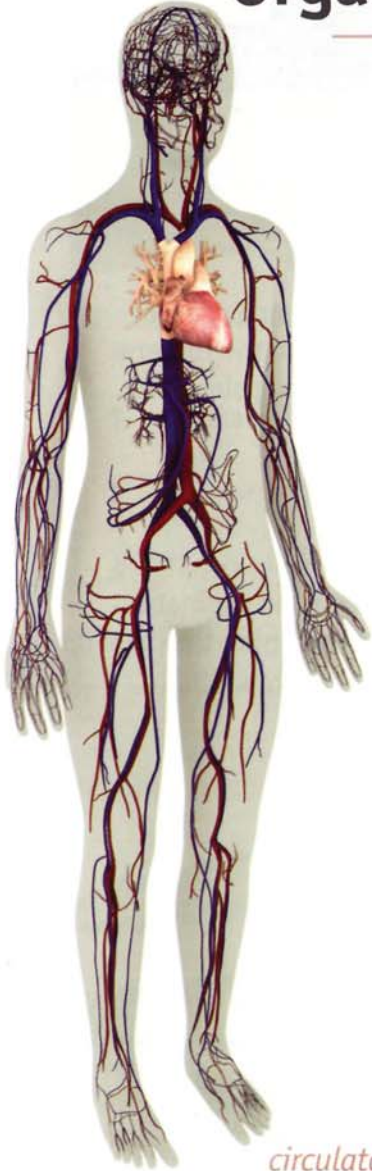
Supination

The biceps brachii and supinator muscles contract turning the palm up.

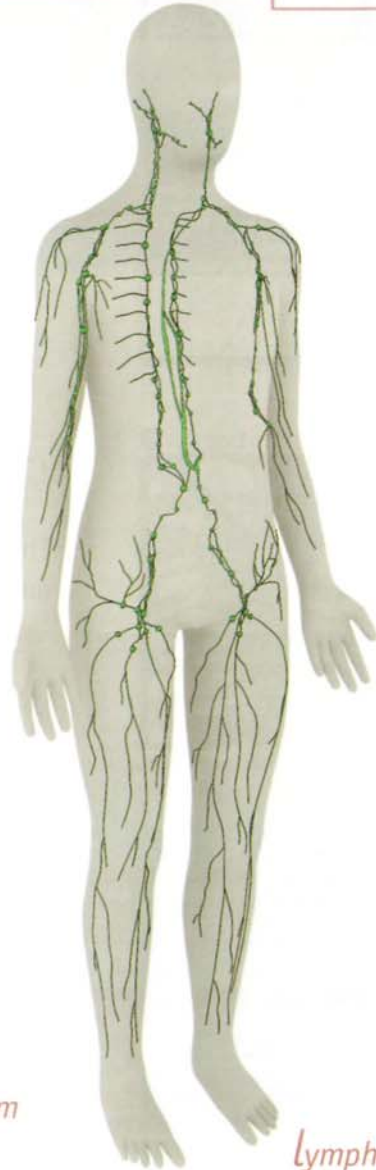
Chapter 23

Myofascial & Organ Planes


A connective tissue sheath encapsulates and separates individual muscles and organs. A thin layer of body fluid coats these sheaths, facilitating the gliding of muscles over neighboring structures. This fluid is apparent in the shiny appearance of muscles and organs during surgery.



circulatory system



lymphatic system



The Myofascial Planes

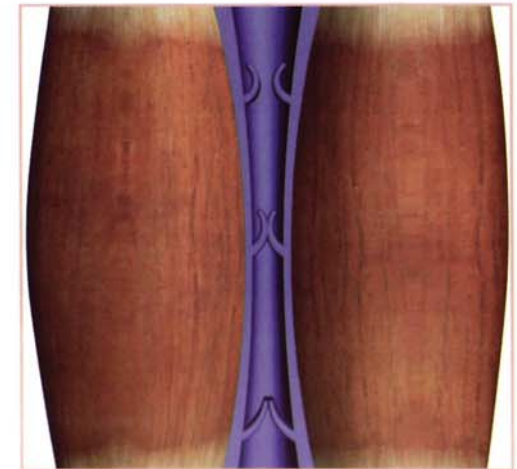
The space between the muscles is called the myofascial plane. Blood vessels, nerves and lymphatics lie in this space and within the connective tissue sheaths themselves.

Blood vessels and lymphatics have one-way valves that direct the flow of body fluids to the larger central vessels. Toxins within the blood and lymphatic fluid are then transported to lymph nodes and organs such as the liver, facilitating their removal.



The One-way Valve System

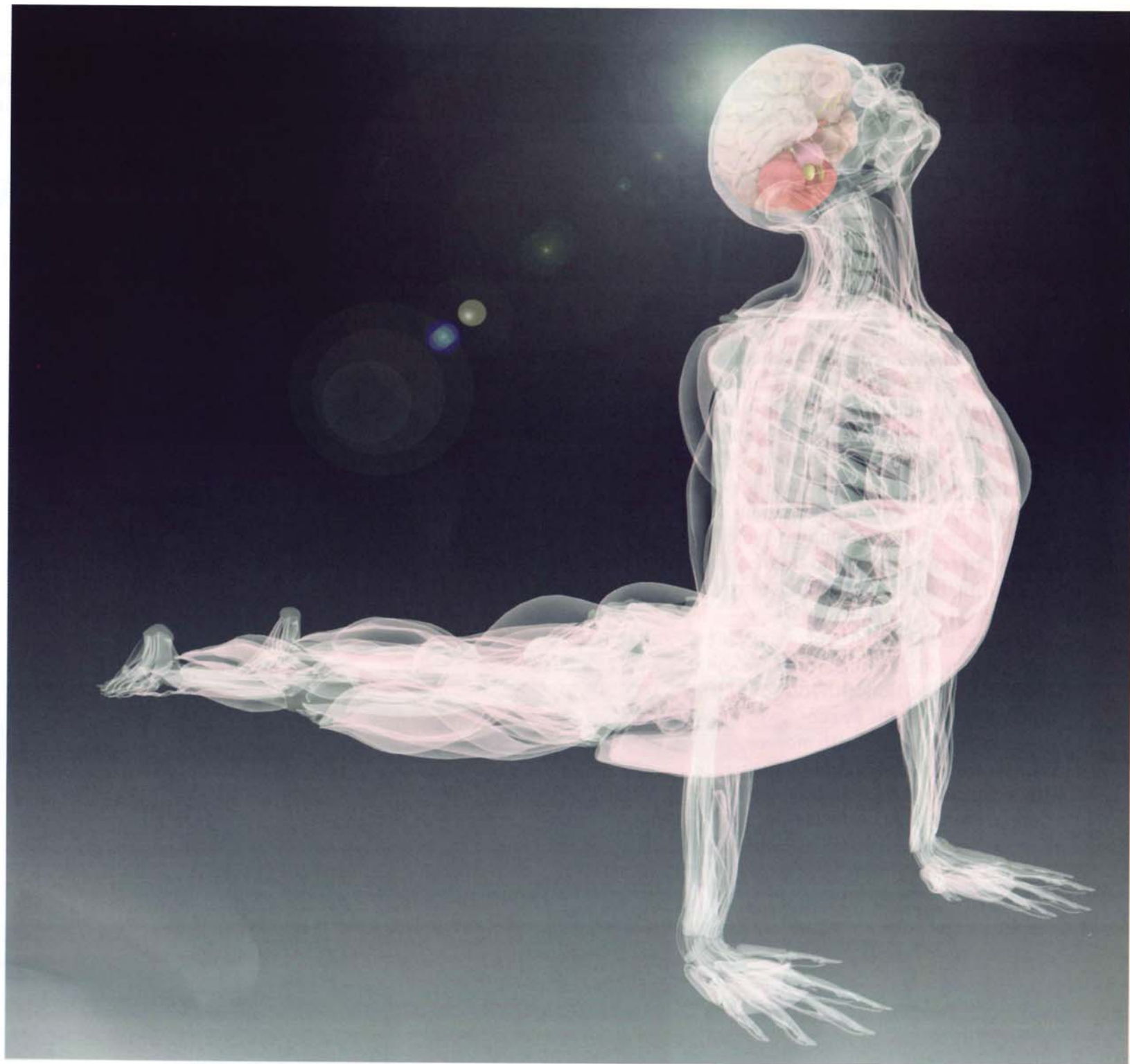
Massage stimulates nerves and mobilizes fluids within the myofascial and organ planes. Contraction and relaxation of muscles during the yoga practice has a similar effect on nerve conduction and fluid transport. The pumping action of the muscles propels body fluids through the one-way valve system of the vessels.



Fascia

The fascial planes are a lattice-like matrix of thin sheets of connective tissue that cover the organs and muscles. Sensory nerves are found throughout the various fascial planes and are stimulated by stretching the fascia in yoga postures. This nerve stimulation can evoke emotional and energetic releases during the practice of yoga.

This image illustrates the fascial planes and their movement in urdhva mukha svanasana.

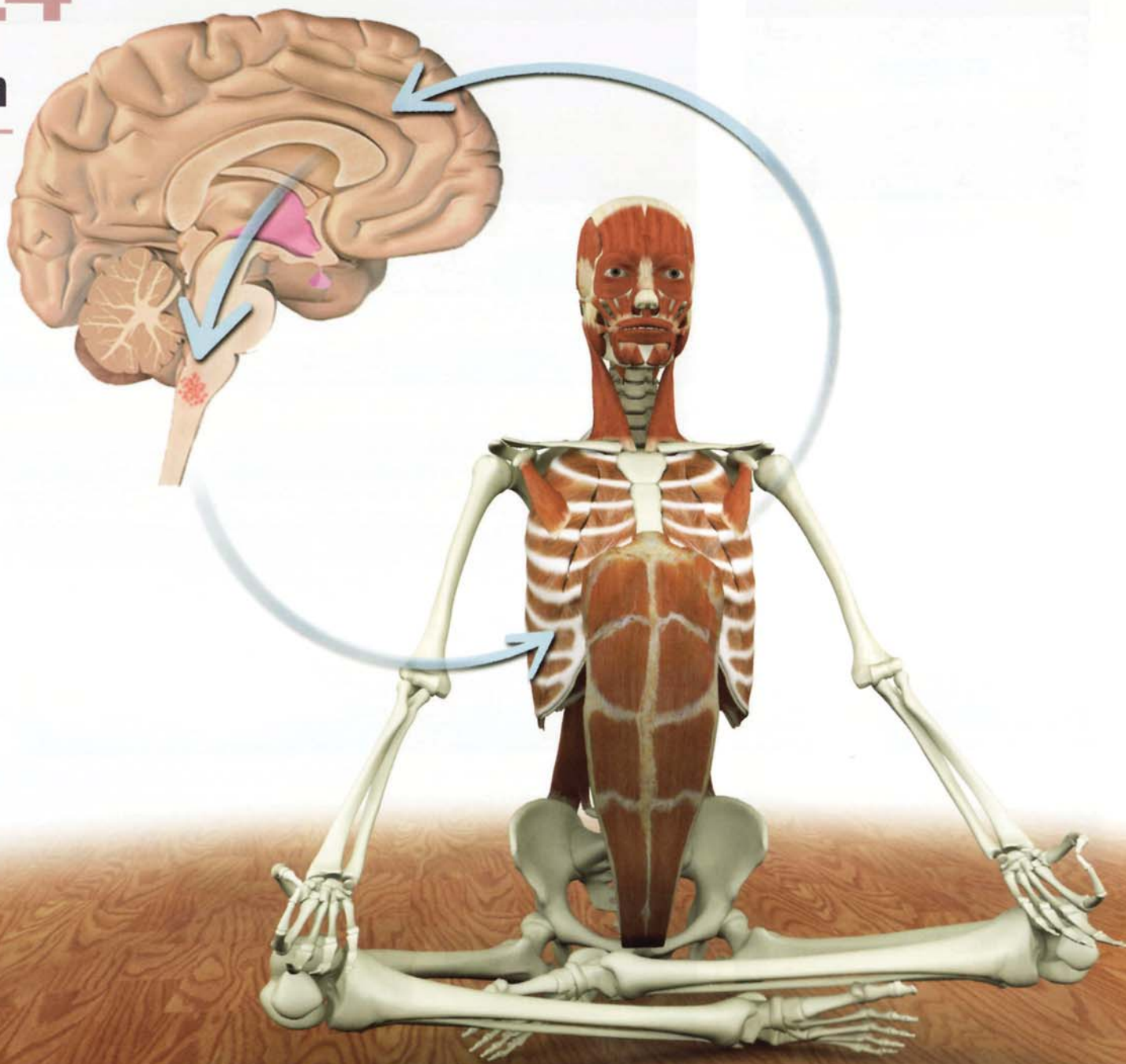


Chapter 24

The Breath Connection

Regions of the brain such as the brainstem are highly evolved for survival, controlling complex functions such as respiration with speed and precision that is far beyond the comprehension of the conscious mind. Great instinctive power is stored in these regions of the brain. Hatha Yogic breathing techniques “yoke” or connect the conscious mind to the primal instinctive regions of the brainstem.

Athletes and martial arts practitioners access the breath’s primal force by timing moments of exertion with forced exhalation. Yogis refine this by coordinating the rhythm of the breath with movements in the asanas, generally coupling inhalation with expansion and exhalation with deepening. Pranayama perfects this process.



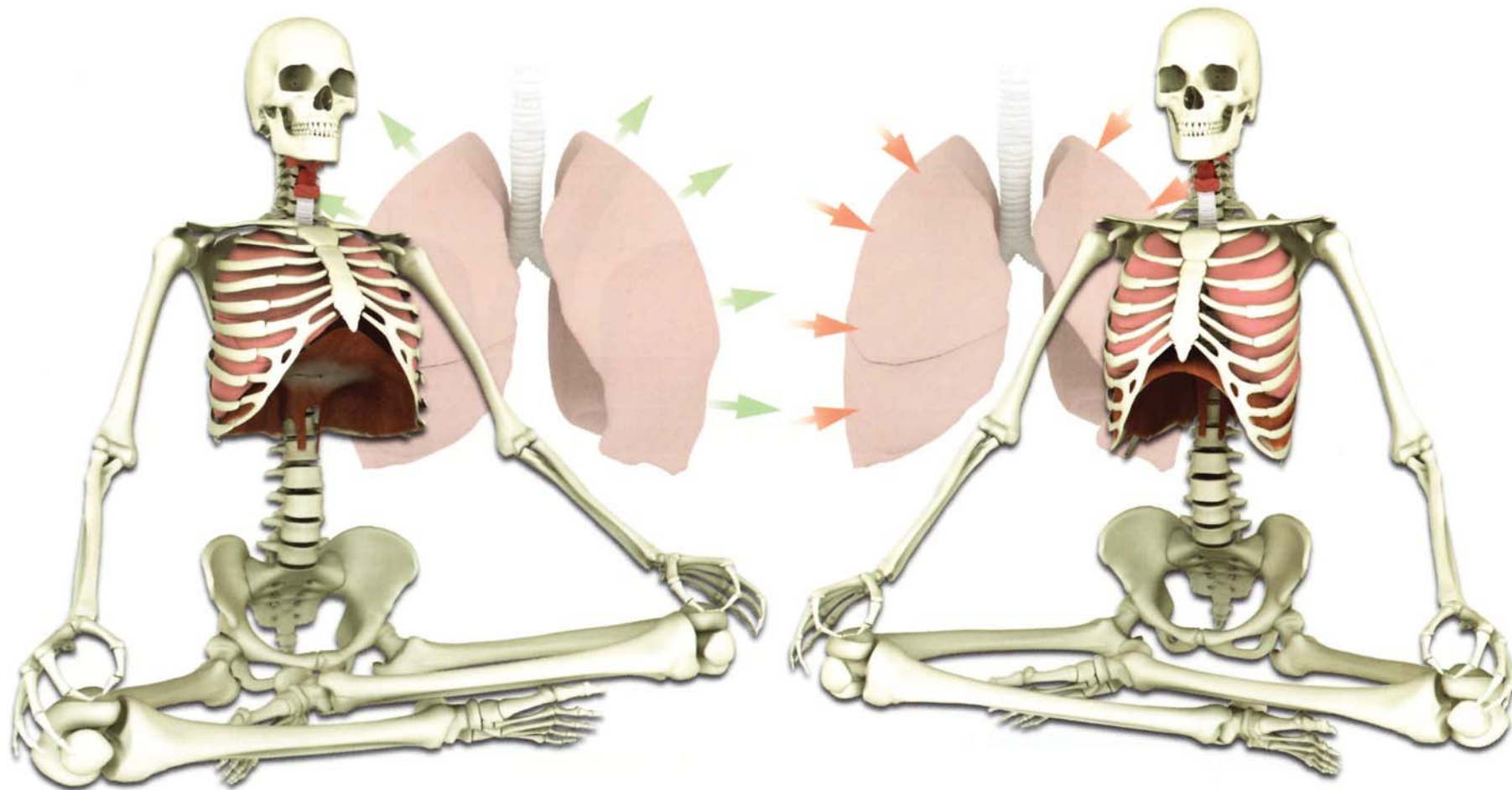
Inhalation and Exhalation

The diaphragm is the prime mover for inhalation and exhalation. It is a thin half-dome shaped muscle that separates the thoracic abdominal cavities. Contracting the diaphragm expands the chest, creating a negative inspiratory pressure in the thorax, and drawing air into the lungs through the trachea. Contracting the diaphragm also gently massages the abdominal organs.

Unlike most other skeletal muscles, the diaphragm rhythmically contracts and relaxes under the control of the autonomic nervous system, via the phrenic nerve. We are unaware of the diaphragm, unless we consciously think about its function.

Yogic breathing techniques such as pranayama involve consciously contracting the diaphragm and controlling the breathing, thereby connecting the conscious and unconscious mind.

These images demonstrate the diaphragm contracting and relaxing. The lungs are elastic and expand when the diaphragm contracts during inhalation. Like a balloon the lungs passively empty during exhalation as the diaphragm relaxes.



Ujayi Breath

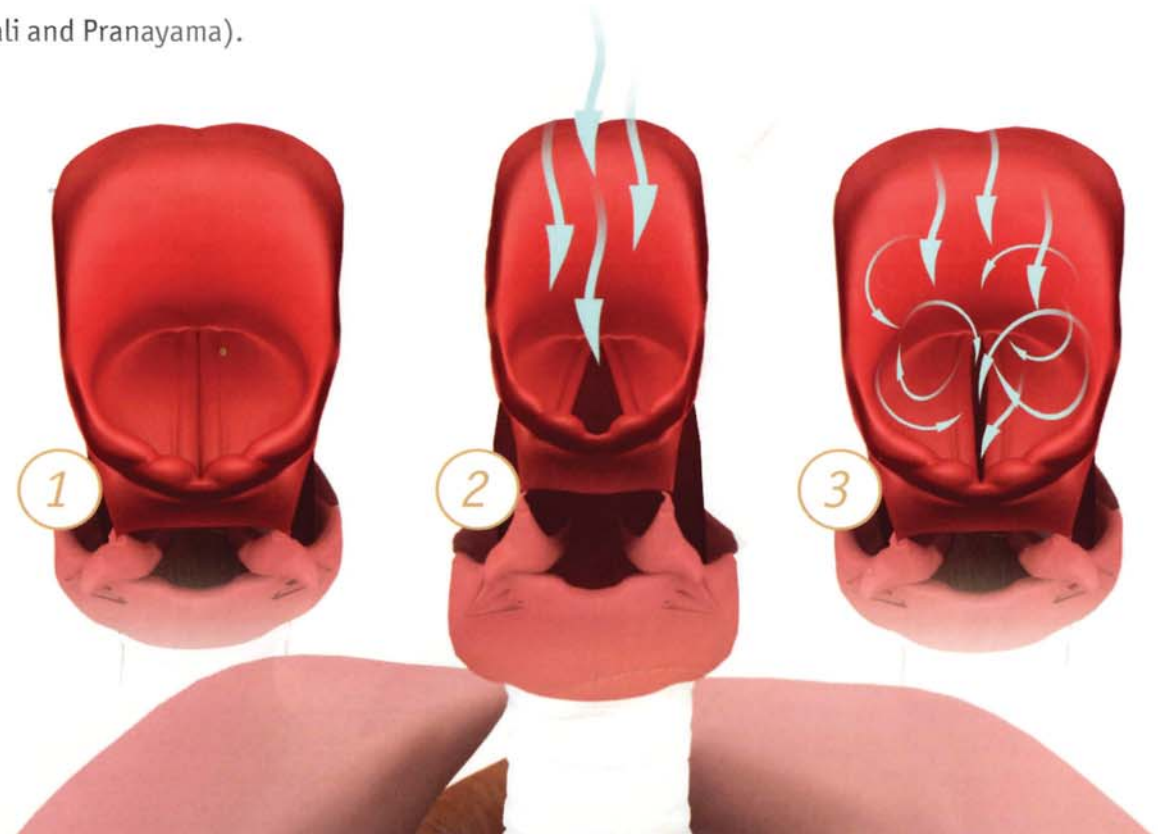
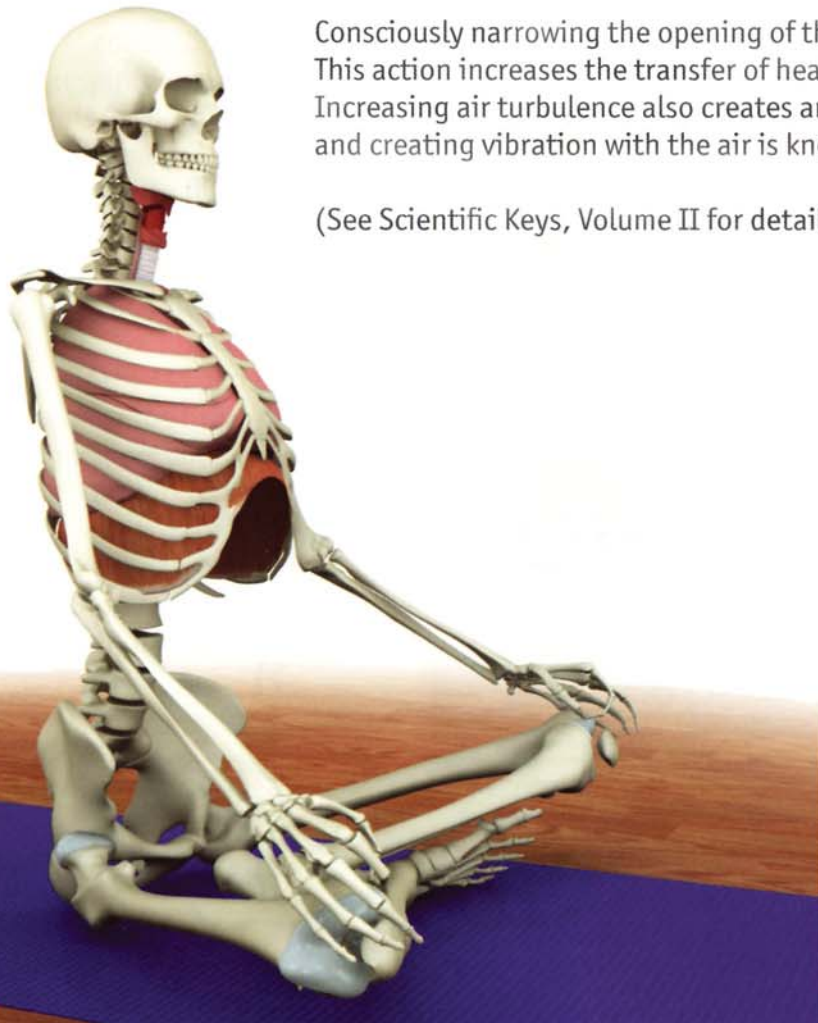When we breathe, the air passes through the nasal sinuses and pharynx into the trachea and on to the lungs, oxygenating the blood and removing carbon dioxide. The pharynx and nasal passages are lined with blood-rich mucosa. The nasal sinuses create turbulence, increasing the amount of air contacting the mucosa. This process warms the air before it passes into the lower parts of the respiratory tract.

The glottis is a muscular aperture below the pharynx and nasal passages. Opening and closing the glottis regulates the flow of air into the lower respiratory tract. Normally we control the opening and closing of the glottis unconsciously.

Yogic breathing techniques involve consciously regulating airflow through the glottis. For example, we seal the glottis when performing Nali so that the negative inspiratory pressure generated by contracting the diaphragm draws the abdominal contents upward instead of drawing breath into the trachea.

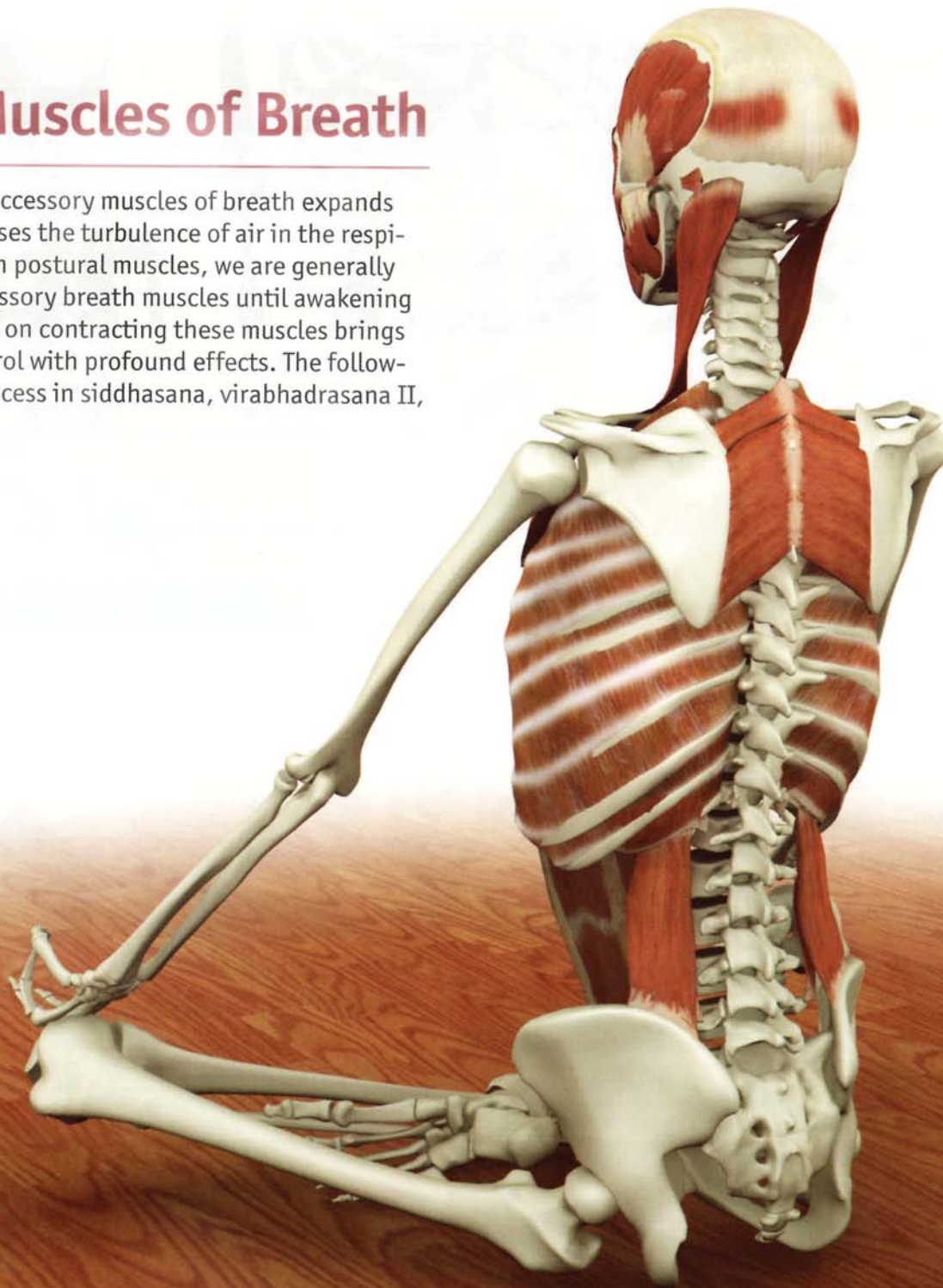
Consciously narrowing the opening of the glottis increases the turbulence of the air passing through the nasal and pharyngeal cavities. This action increases the transfer of heat to the air from the blood-rich mucosal lining, raising the temperature of the air above normal. Increasing air turbulence also creates an audible vibration similar to that of a flame leaping up from a fire. This process of increasing heat and creating vibration with the air is known as Ujayi breathing and is fundamental to the practice of Pranayama or "Breath of Fire."

(See Scientific Keys, Volume II for details on Nali and Pranayama).



Accessory Muscles of Breath

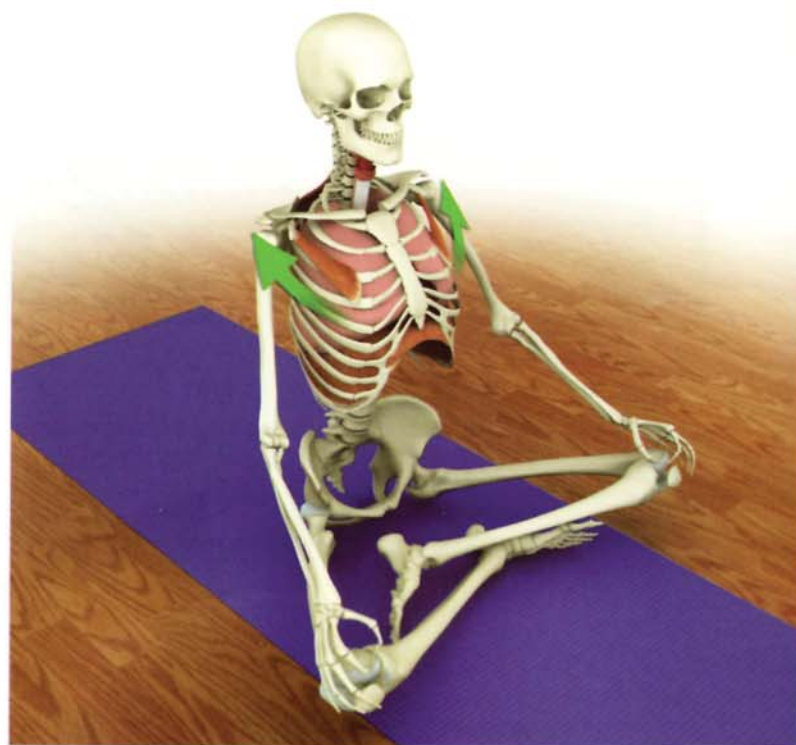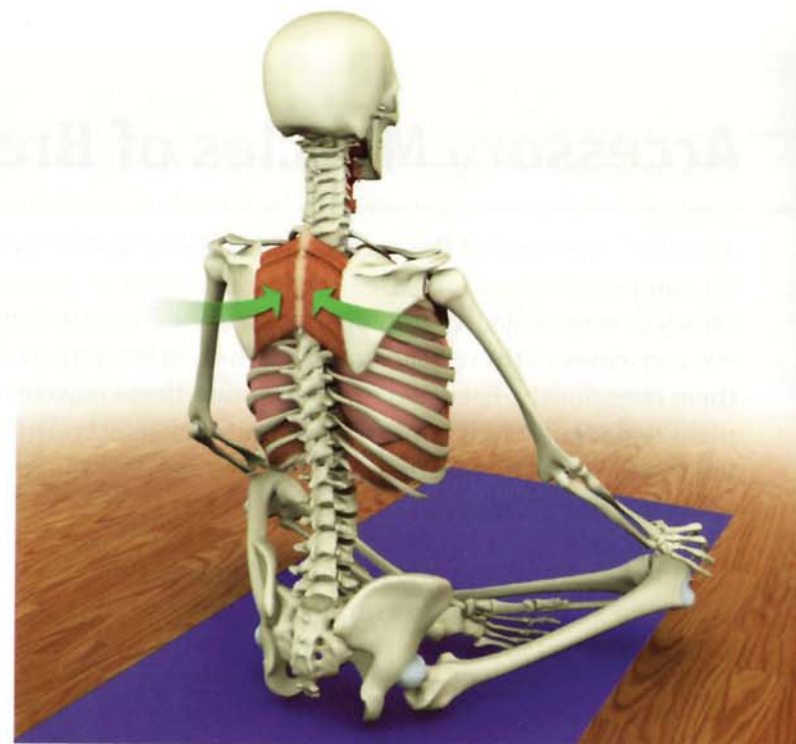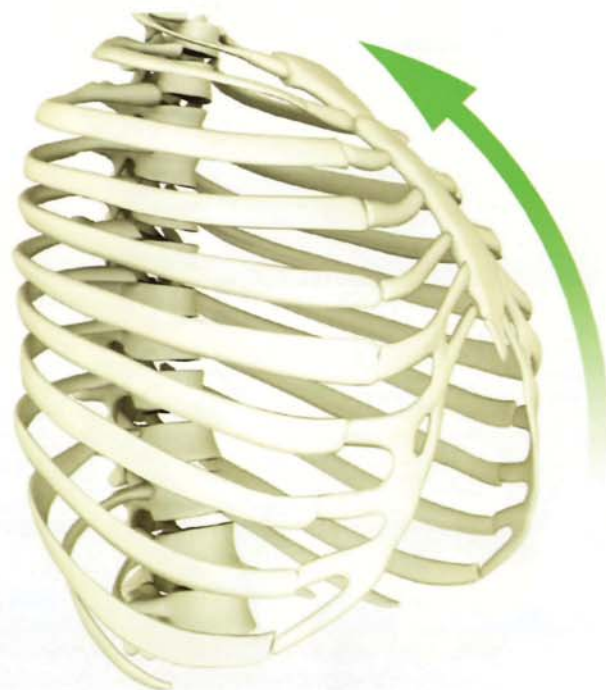
Accessing the force of the accessory muscles of breath expands the lung volume and increases the turbulence of air in the respiratory passageways. As with postural muscles, we are generally not conscious of these accessory breath muscles until awakening them consciously. Focusing on contracting these muscles brings them under conscious control with profound effects. The following pages illustrate this process in siddhasana, virabhadrasana II, tadasana and utthanasana.



Thoracic Bellows

Begin awakening the accessory muscles of breath by drawing the scapula towards the midline. Hold this position and then attempt to roll the shoulders forward by contracting the pectoralis minor. This closed chain contraction lifts and opens the lower ribcage like a bellows and expands the lung volume.

Begin by practicing in siddhasana and then apply this technique to other postures such as twists that constrict the volume of the thoracic cavity.



Accessory Muscles of Breath

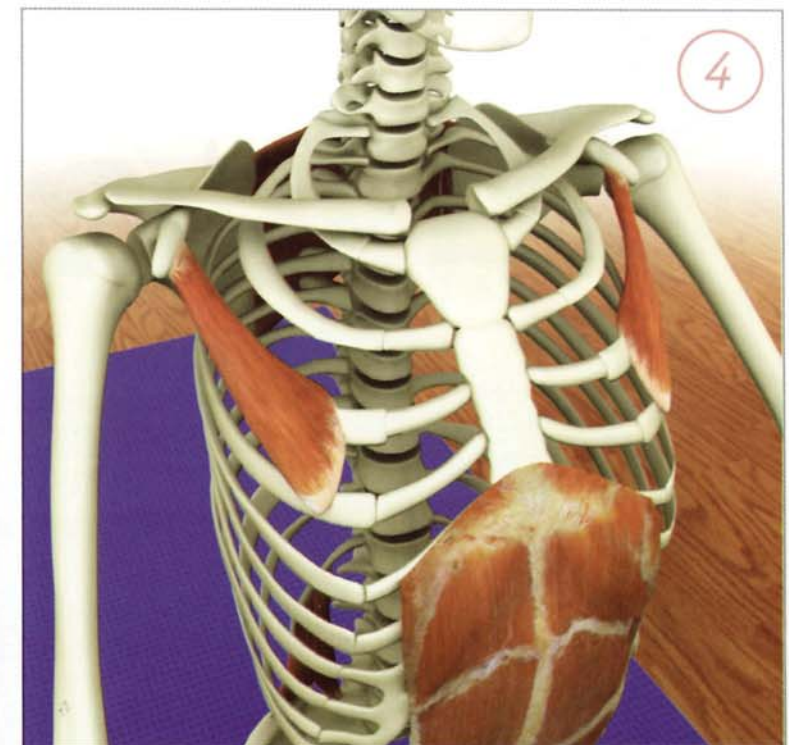
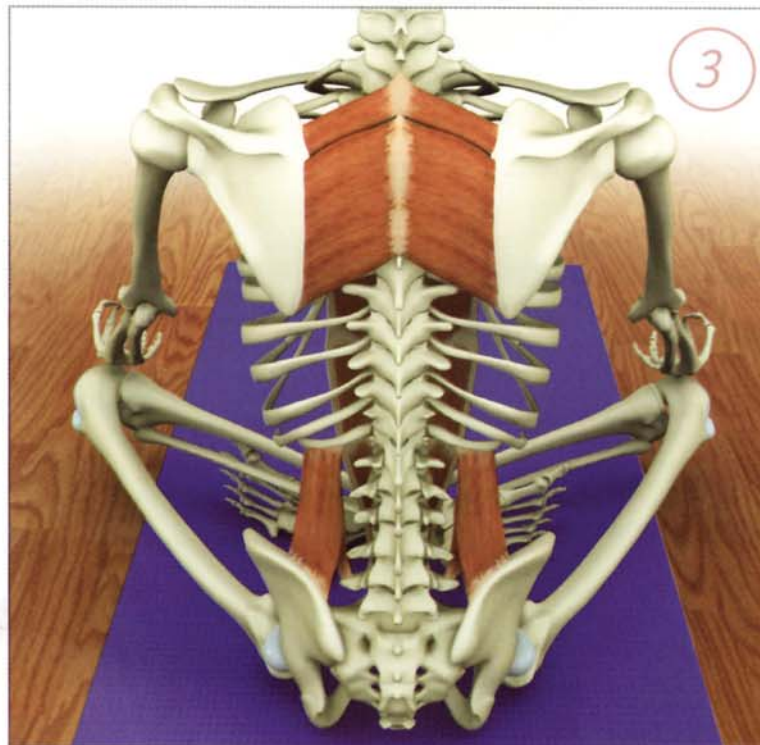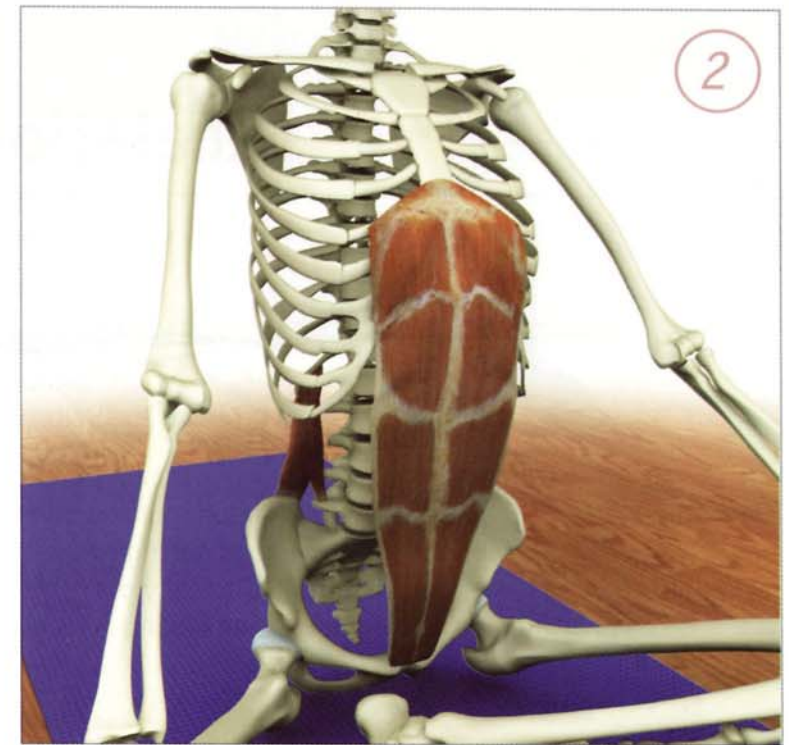
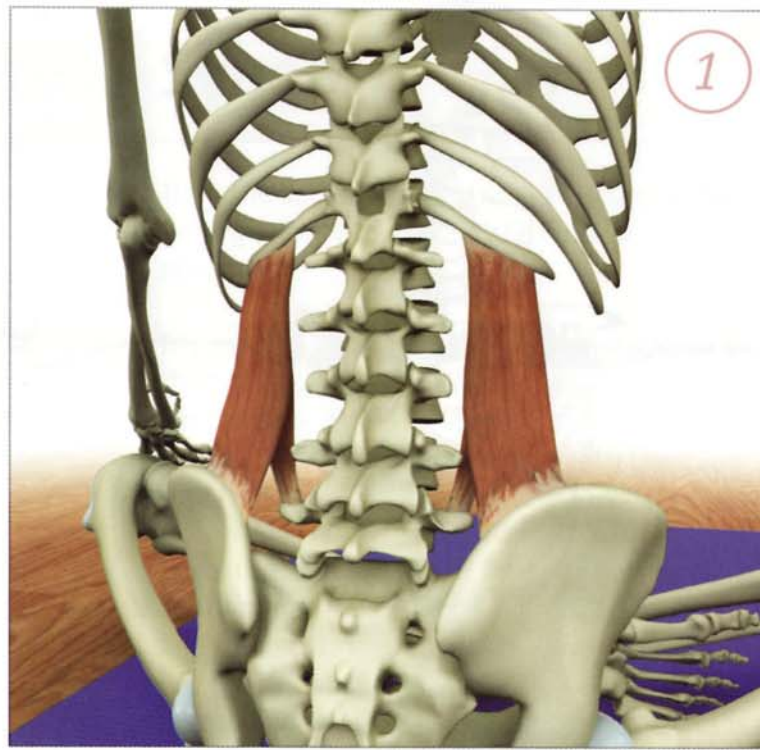
1) Straighten the lower back by contracting the erector spinae and quadratus lumborum. This draws the lower posterior ribcage downward.

2) Balance this action by gently contracting the rectus abdominus. This draws the lower anterior ribcage downward and compresses the abdominal organs against the diaphragm, dynamizing its contraction and strengthening it.

3) Draw the shoulder blades together by contracting the rhomboids. This opens the front of the chest.

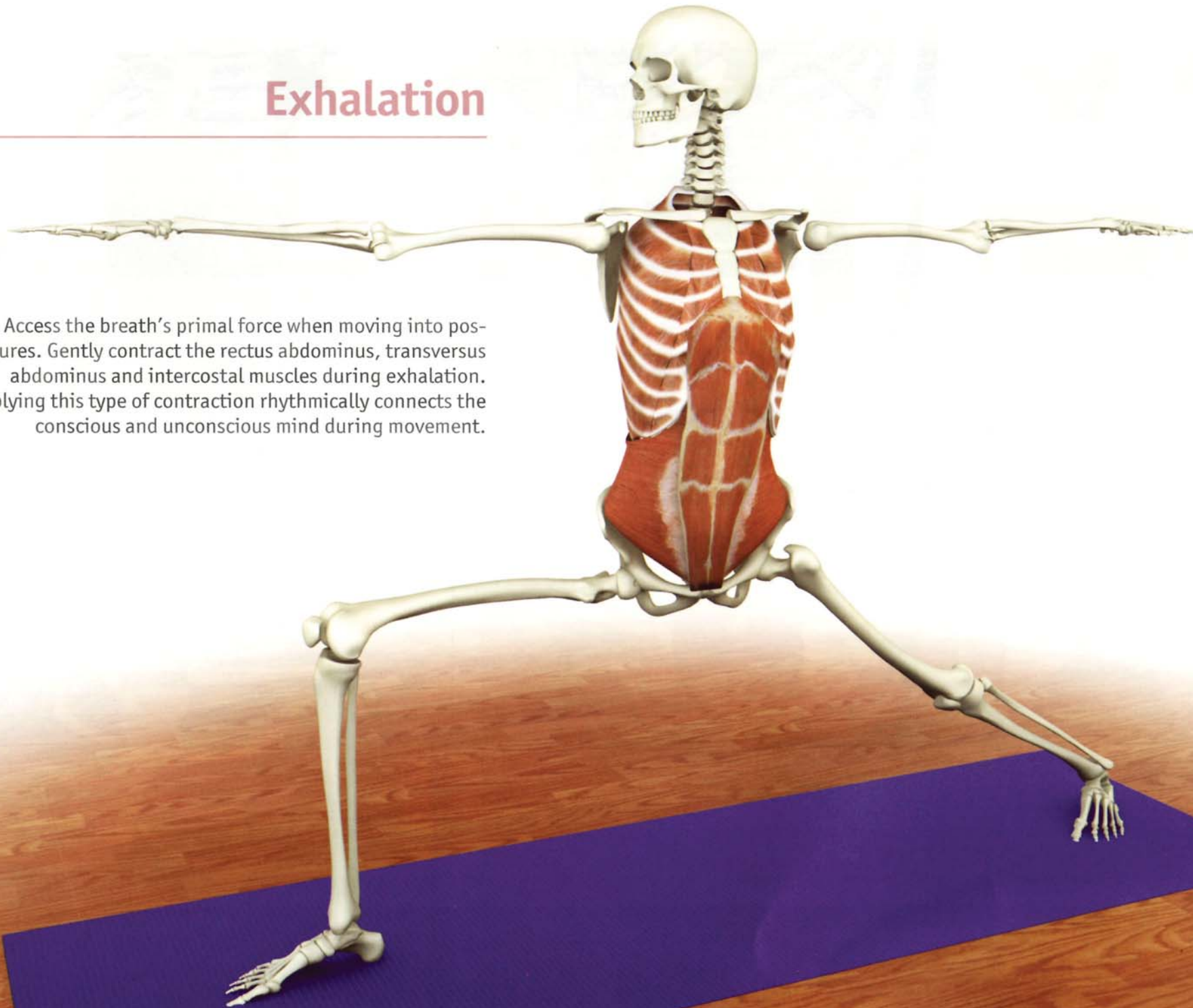
4) Maintain the contraction of the rhomboids and simultaneously contract the pectoralis minor and sternocleidomastoid. This lifts and opens the ribcage like a bellows.

Complete this process by pressing the hands down on the knees to fully open the chest (by contracting the latissimus dorsi).



Exhalation

Access the breath's primal force when moving into postures. Gently contract the rectus abdominus, transversus abdominus and intercostal muscles during exhalation. Applying this type of contraction rhythmically connects the conscious and unconscious mind during movement.



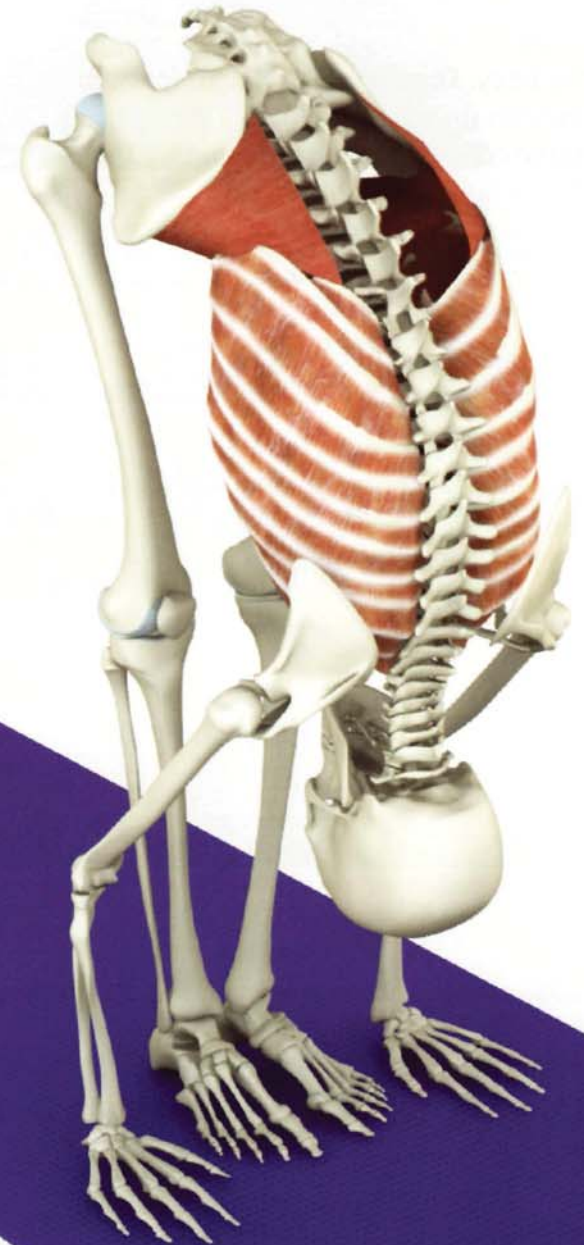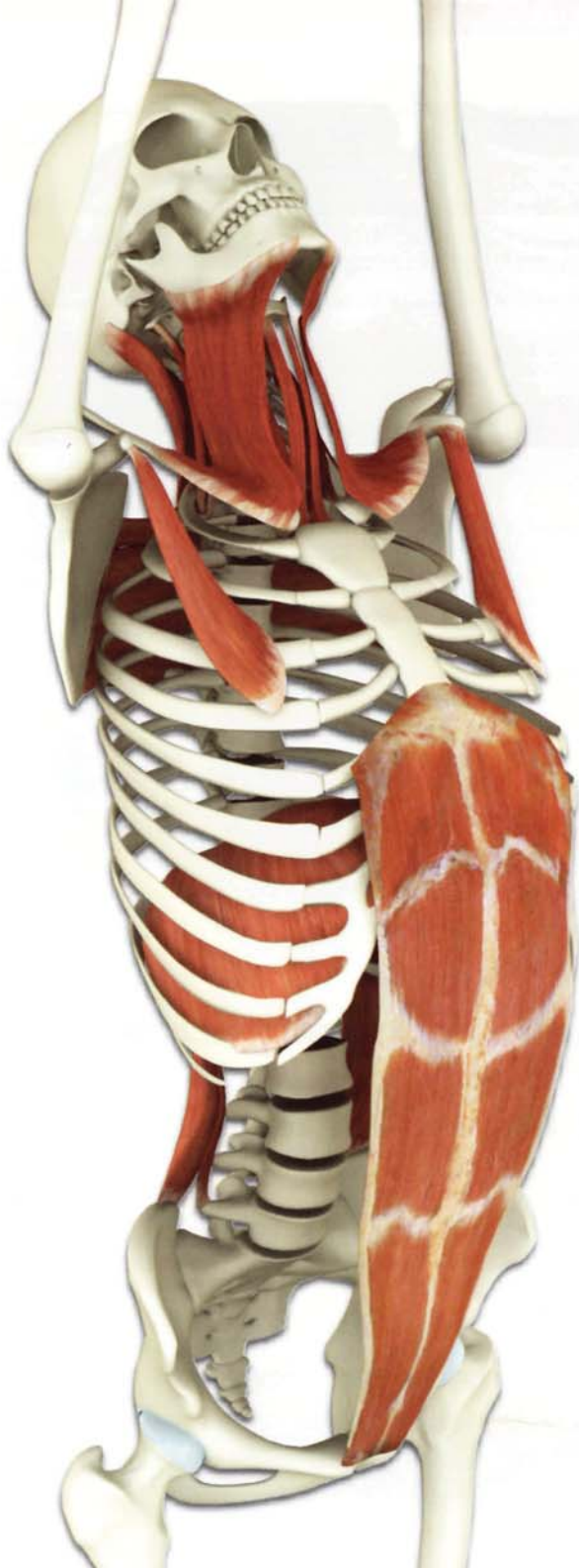Synergy

Train the accessory breathing muscles so that they work synergistically to expand and contract the thorax during movement.

Increase the lung volume during inhalation by contracting the accessory breathing muscles in various combinations. For example, combine the rhomboids with the pectoralis minor, or the rectus abdominus with the quadratus lumborum (illustrated here in tadasana).

Expel the residual air in the lungs during exhalation by contracting the rectus abdominus, transversus abdominus and intercostal muscles.

Awakening the accessory breathing muscles is an extremely powerful technique. Begin with very gentle contraction and progress slowly and with great care. Never force any yoga technique, especially breathing. Always proceed with caution under the guidance of an instructor.



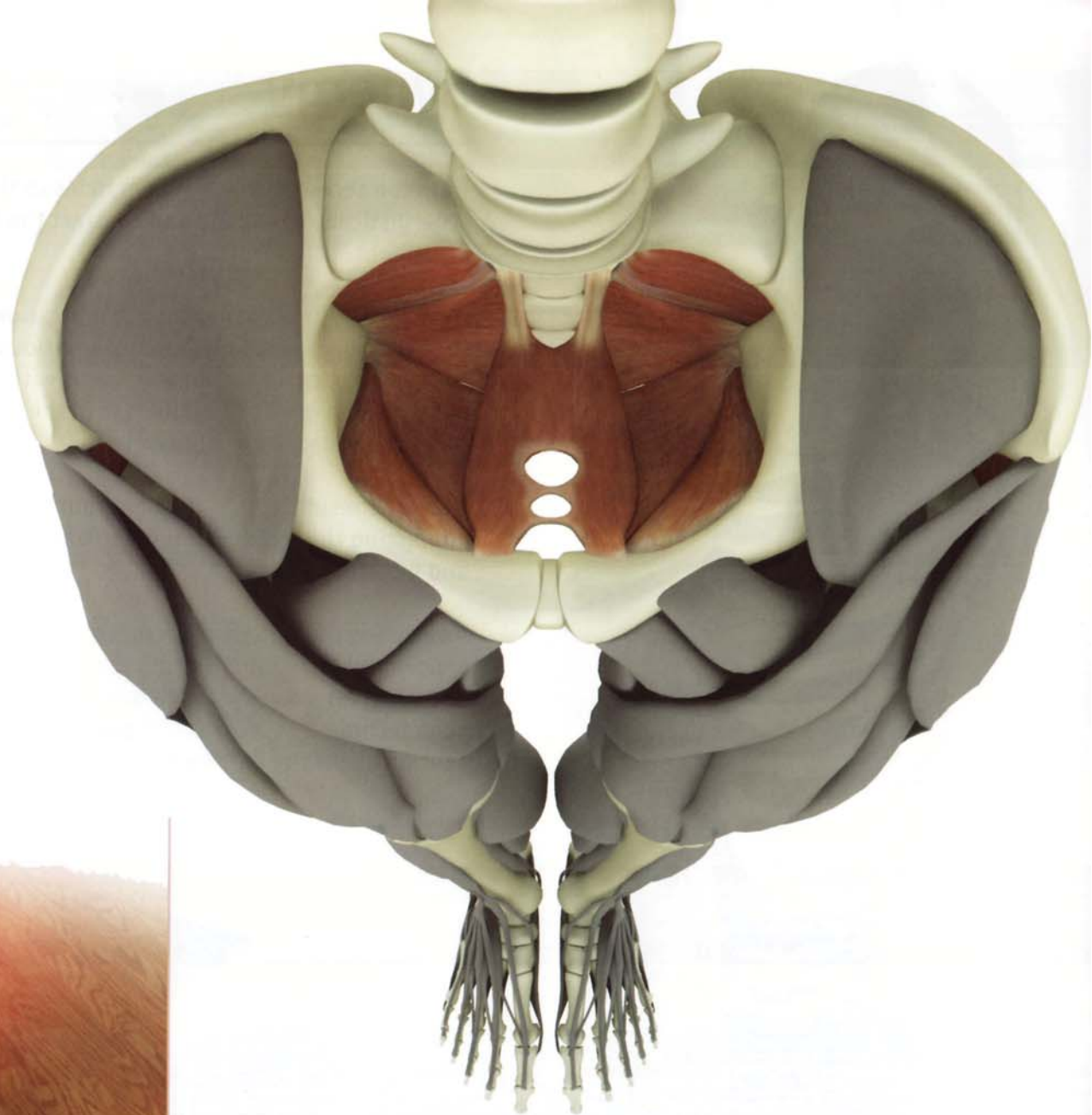
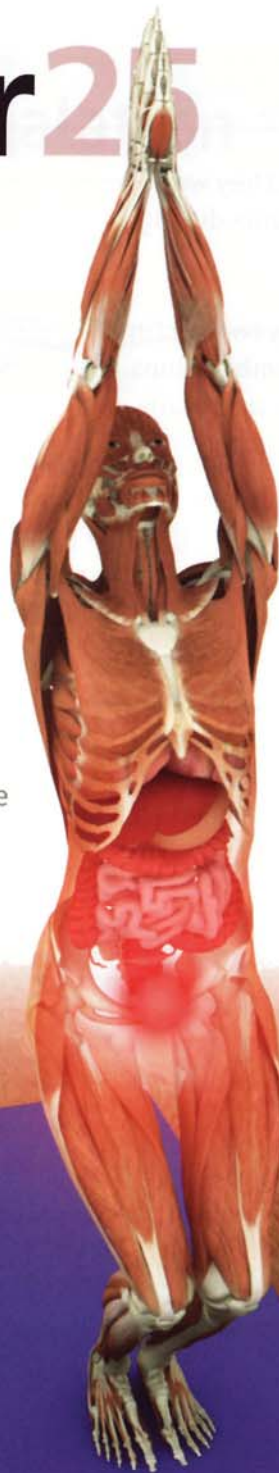Chapter 25

Bandhas

Bandhas are “locks” occurring throughout the body. The combination of opposing muscles forms these “locks”, stimulating nerve conduction and illuminating the chakras.

Moola bandha

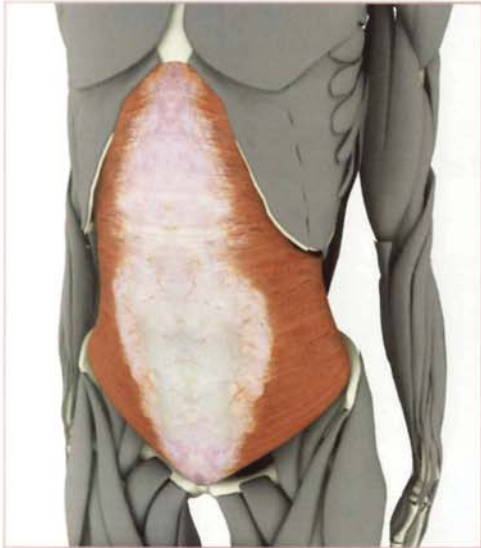Moola bandha contracts the muscles of the pelvic floor lifting and toning the organs of the pelvis including the bladder and genitalia. The pelvic floor muscles are recruited and awakened by contracting associated muscles such as the iliopsoas. This focuses the mind on the first chakra.



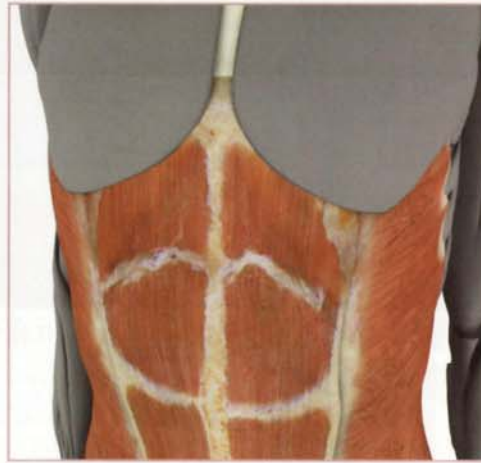Simultaneously contracting other muscle groups accentuates moola bandha. For example, gently squeezing the knees together (by contracting the adductors) increases contraction of the pelvic floor muscles. Pressing the hands together has the same effect. This phenomenon is known as “recruitment.”

Udyana bandha

Udyana bandha contracts the upper abdominals in the region approximately two inches below the solar plexus and focuses the mind on the third chakra.



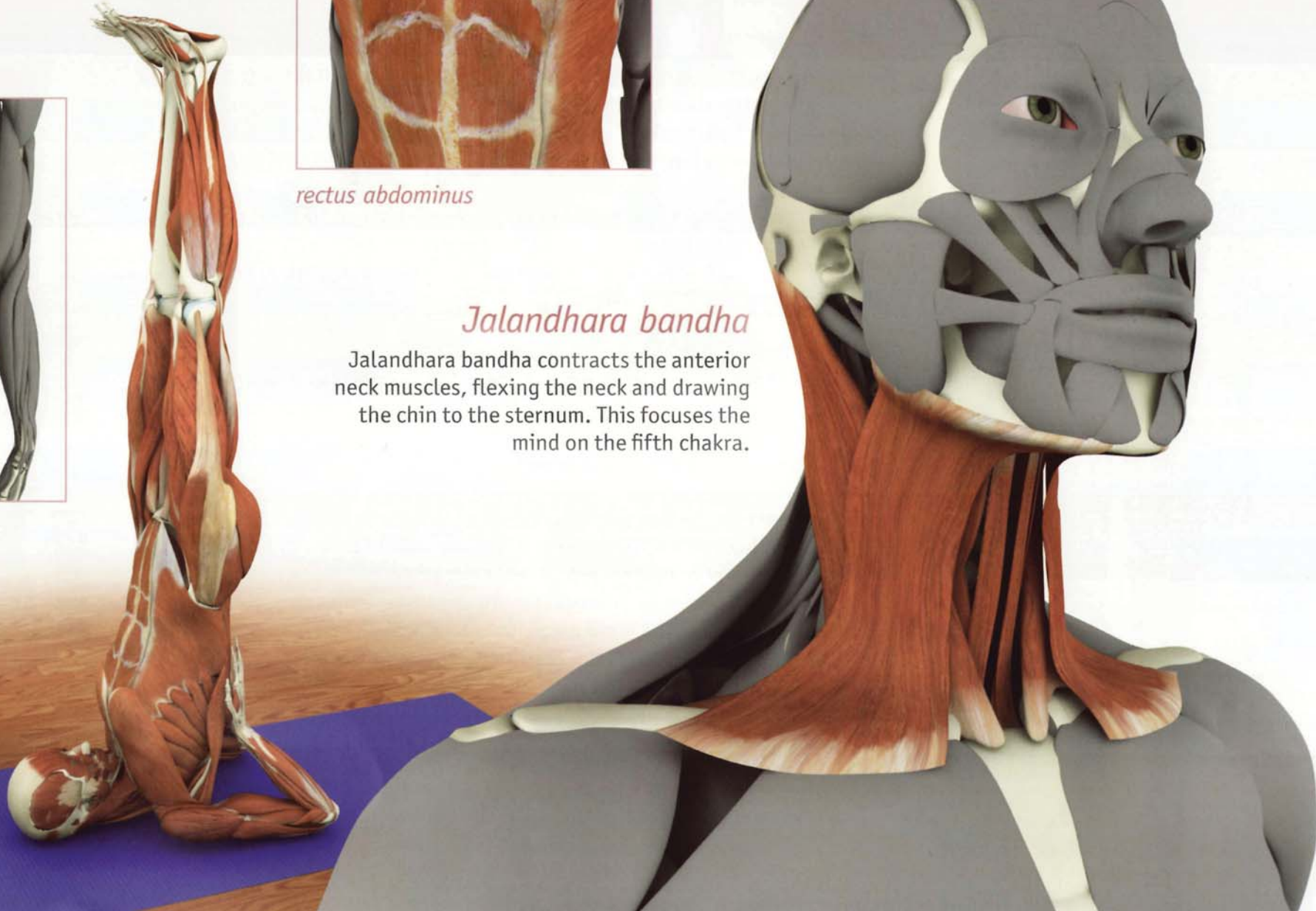
transversus abdominus



rectus abdominus

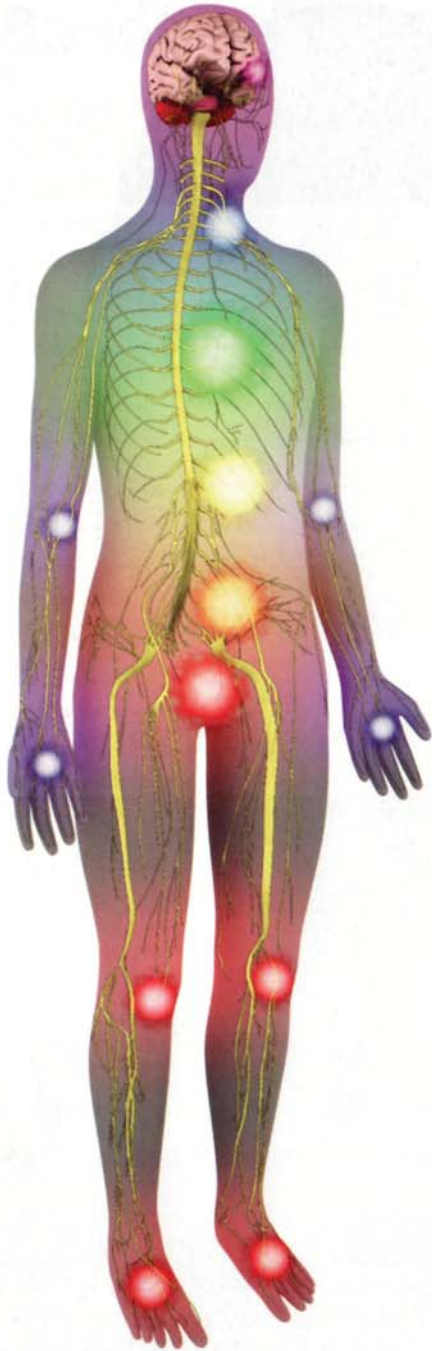
Jalandhara bandha

Jalandhara bandha contracts the anterior neck muscles, flexing the neck and drawing the chin to the sternum. This focuses the mind on the fifth chakra.



Chapter 26

Chakras



The chakras are the subtle energy centers of the body. Like pinwheels, the chakras spin at the speed of light, emanating the colors of the spectrum, each resonating with a particular frequency. These colors combine to form the auras that surround each of us, connecting us with each other and with the cosmos.

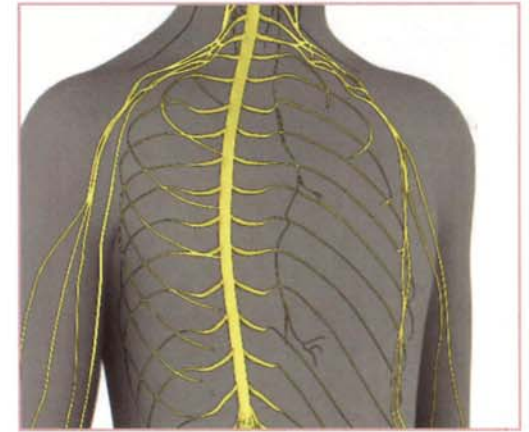
There are seven to eight major and numerous minor chakras in the body. Their locations correspond to regions of the body where nerves collect and electrical activity is high, such as the brachial and sacral plexi (major chakras) and the elbows and knees (minor chakras).

The flow of energy in the chakras can become blocked by life events through the activity of the autonomic nervous system. For example, when we habitually assume a defensive posture in response to negative stimuli, we block the flow of energy in the chakras. Hatha Yoga counteracts this and re-illuminates the chakras, stimulating them to spin freely.

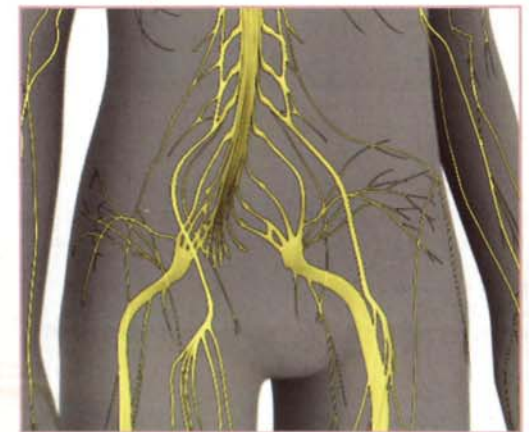Kundalini awakening refers to the “unblocking” of the flow of energy through and between the chakras. This process can occur instantaneously from contact with a master (inner or outer) who awakens the student’s awareness of his or her potential. Classically, this occurs through a touch but can occur with a glance or even through the mere presence of the master. This is known as Shaktipata (the transmission of psycho-spiritual energy). As human consciousness transitions from the Piscean to the Aquarian Age, more and more people are spontaneously experiencing varying degrees of Kundalini awakening.

Kundalini awakening is akin to tapping into a high voltage line and requires careful preparation. Hatha Yoga prepares the practitioner and awakens the Kundalini at the same time.

brachial plexus



sacral plexus

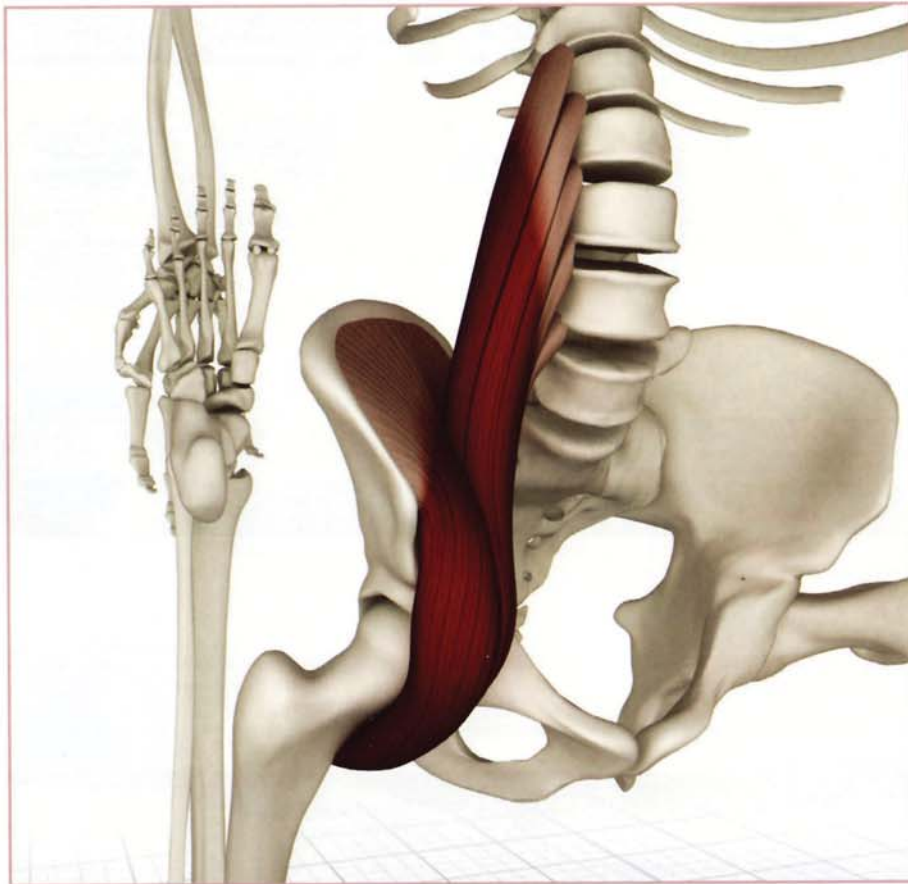


Putting it all together

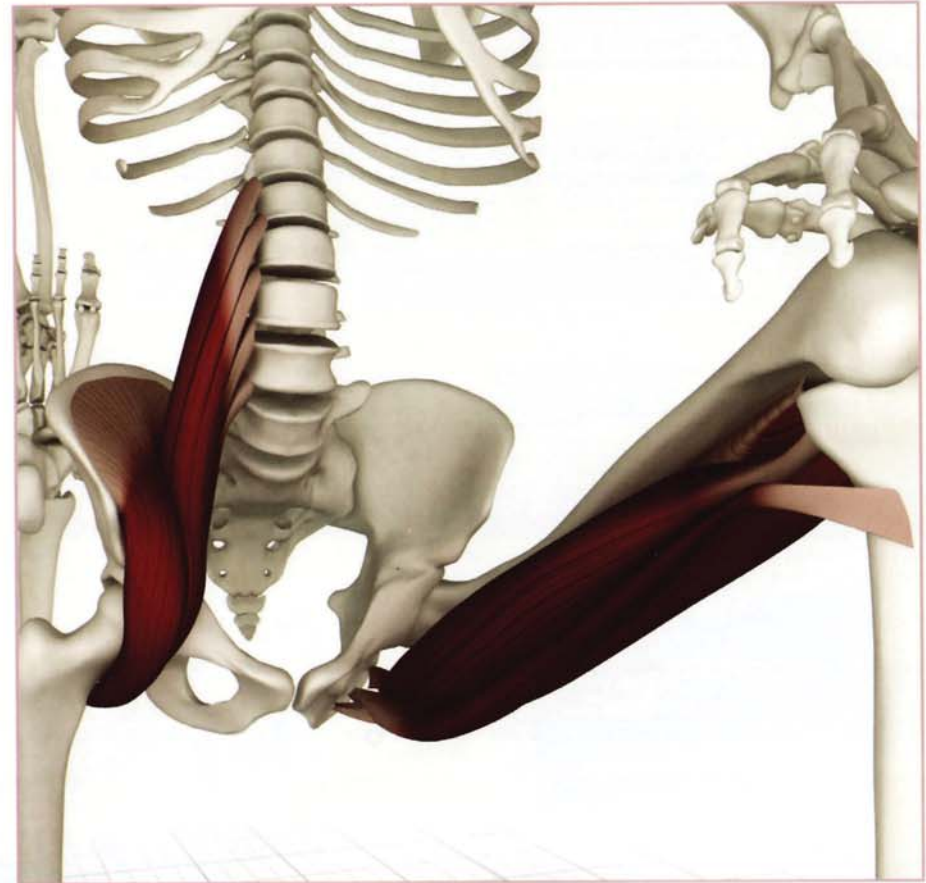
Balance all of the forces acting throughout the musculoskeletal system. Contract, relax and stretch the appropriate muscles and the bones will align themselves automatically. Synergistically combine the asanas to complete the process. (Discussed in Scientific Keys, Volume II).

This sequence illustrates the process of combining muscles sequentially in the lunge pose:

1. Position the body in lunge to begin stretching the iliopsoas.

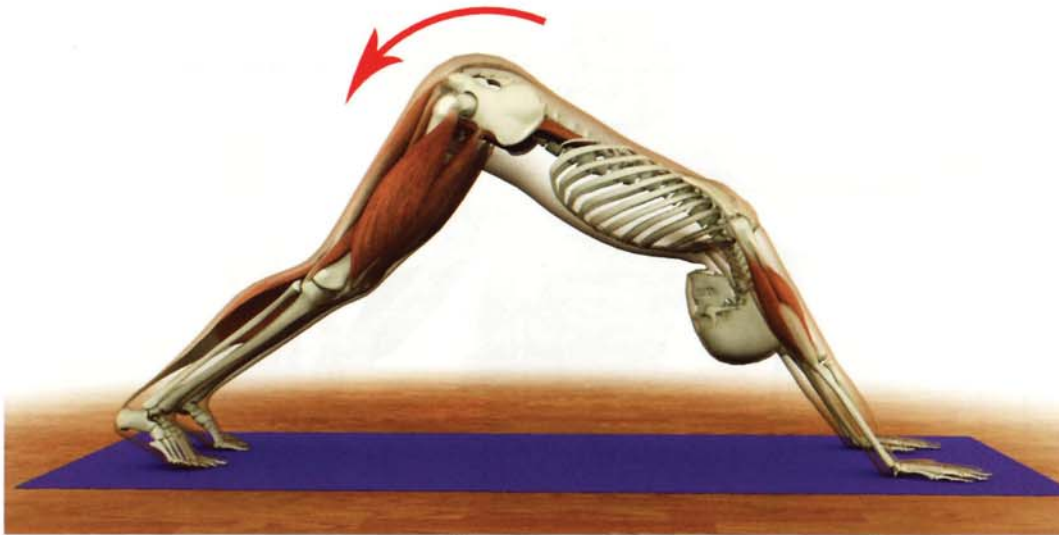


2. Contract the front leg hamstrings, drawing the body deeper into lunge, accentuating the iliopsoas stretch.

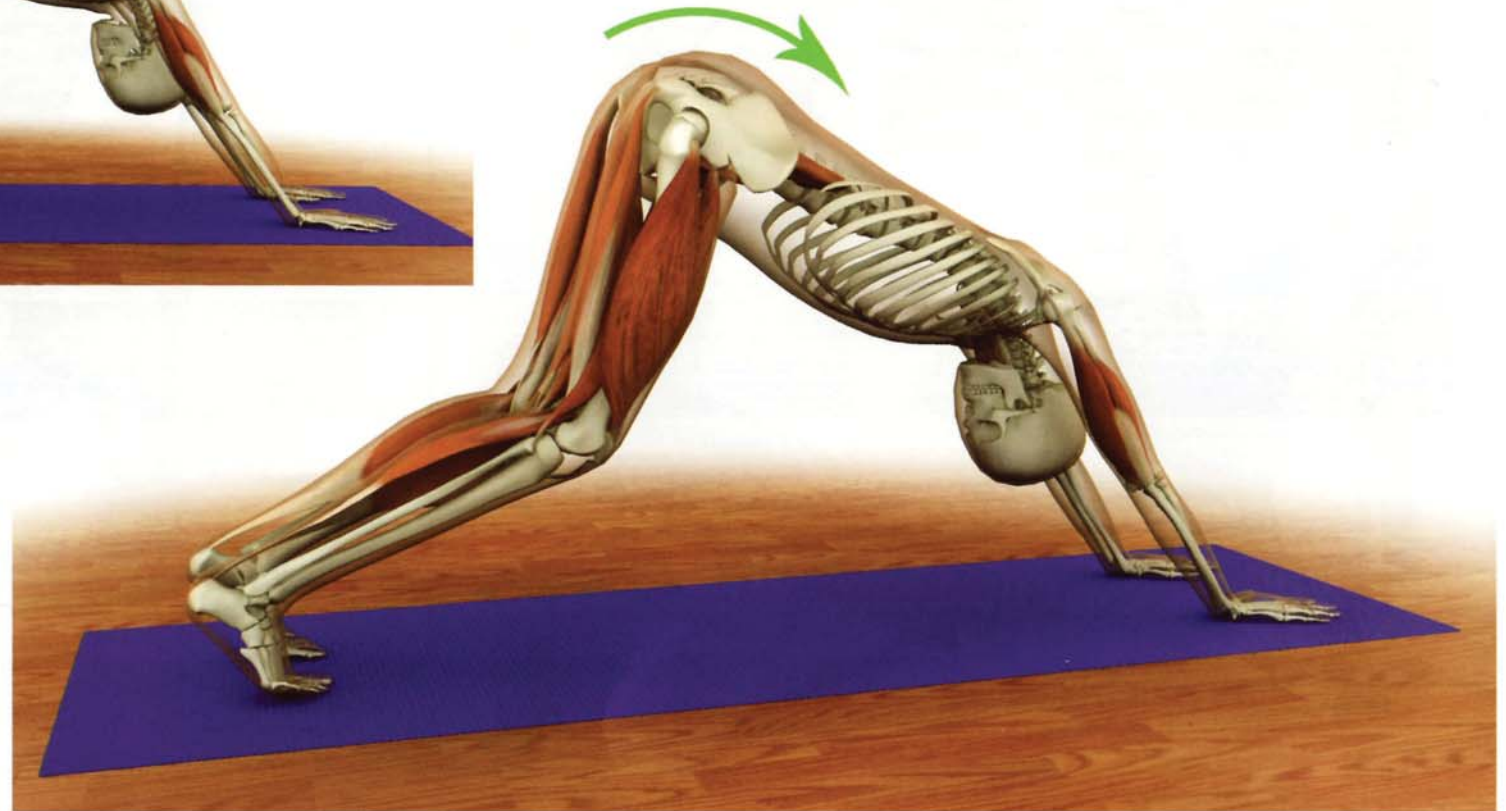


Easing into Downward Dog

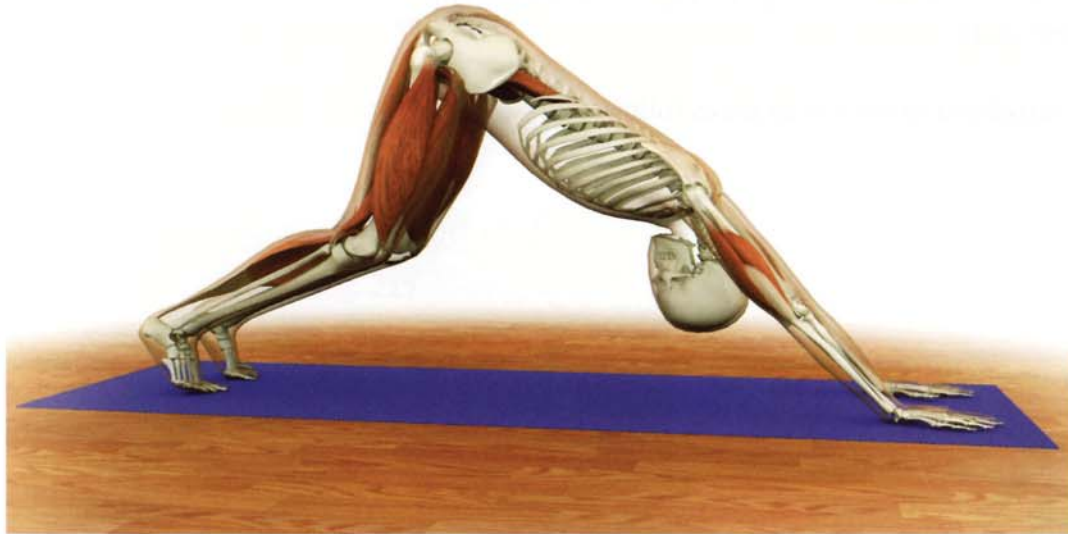1) This image illustrates downward facing dog pose with tight hamstrings. Note how the pull of the hamstrings tilts the pelvis backwards (retroversion). This pulls the lumbosacral fascia and back muscles so that the lower back loses some of its natural arch.




2) Bend the knees to release the hamstrings and free the lower back. Contract the iliopsoas to tilt the pelvis forward (anteversion). This action brings back the natural arch of the lower back and draws the trunk towards the thighs.



3) Contract the triceps to extend the elbows, straightening the arms.



4) Maintain the contraction of the iliopsoas to fix the pelvis in anteversion. Then contract the quadriceps to straighten the knees and draw the hamstrings out to full stretch completing the pose.

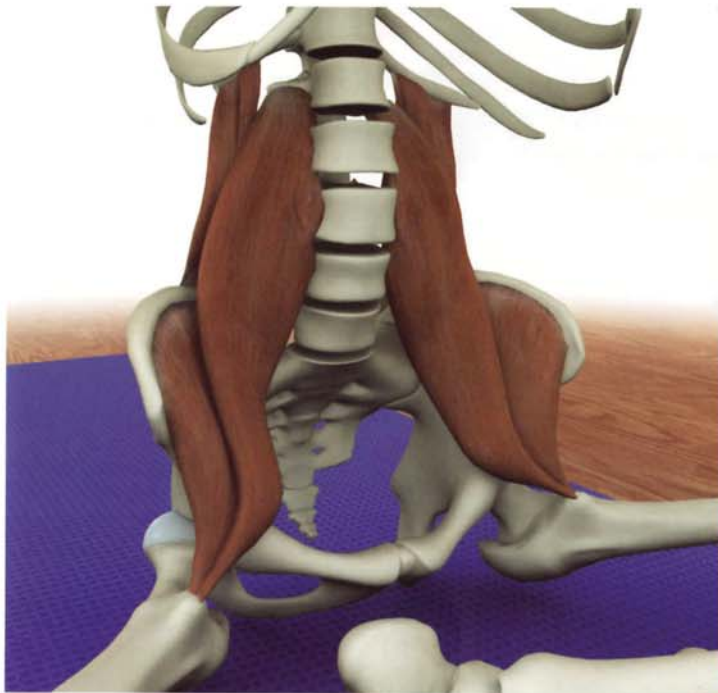


Optimizing Siddhasana Dog

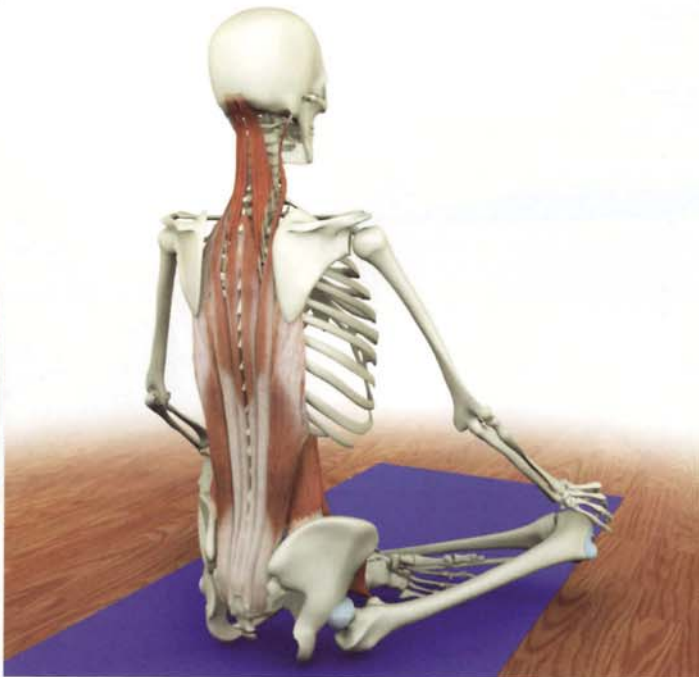


The ancient Chinese oracle the I-Ching contains fundamental instruction for the practice of yoga in the hexagram "Keeping Still" (52 Kên). This hexagram resembles a vertebral unit of the spine. The text contains instruction for achieving stillness by stabilizing the spine from the sacrum to the skull.

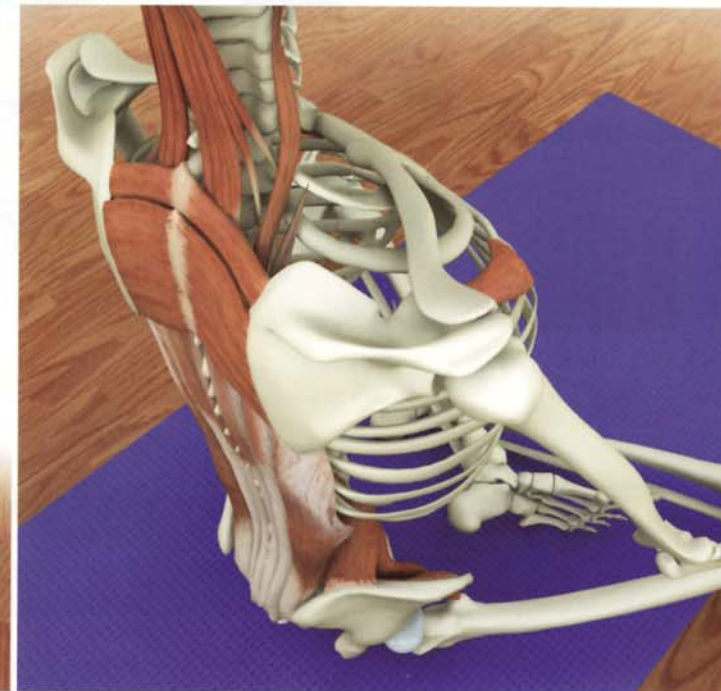
This section shows how to optimize siddhasana by sequentially activating various muscles as follows:



1) Contract the psoas and quadratus lumborum to stabilize the lumbar spine and ground the pelvis.

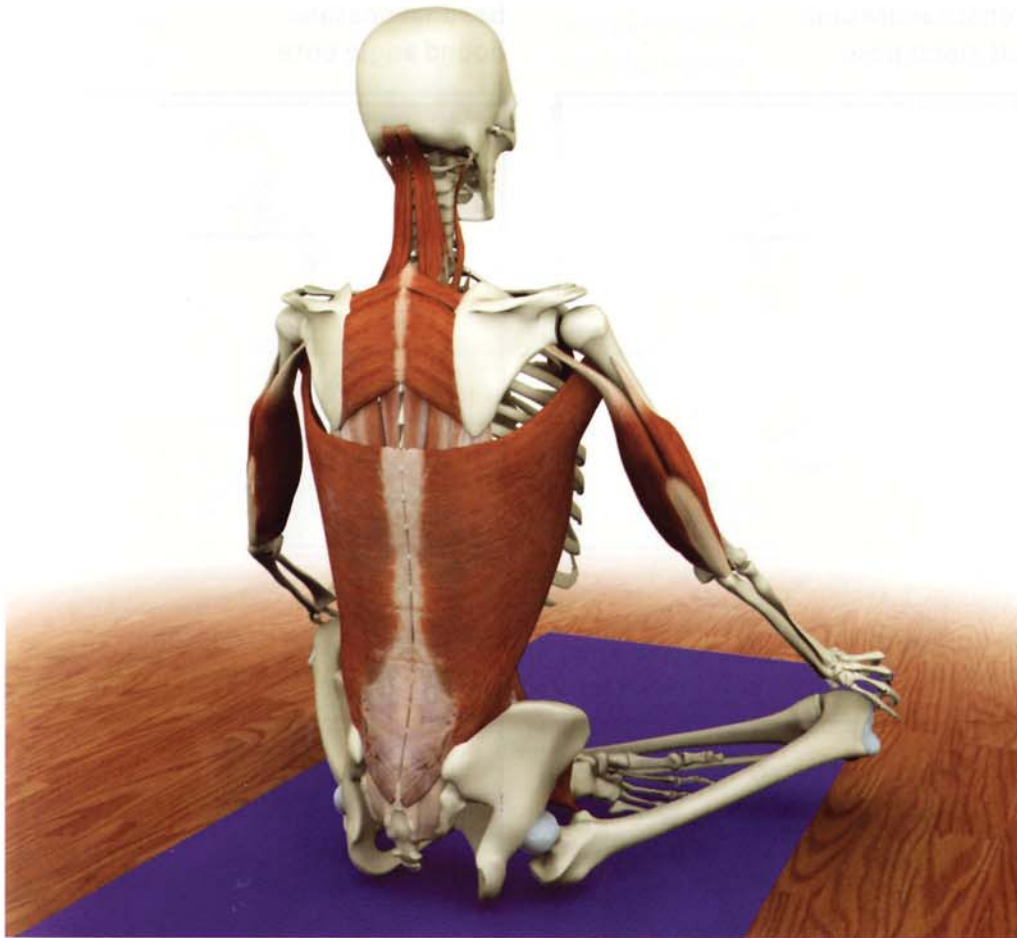


2) Contract the erector spinae to straighten the spine and move energy upward.

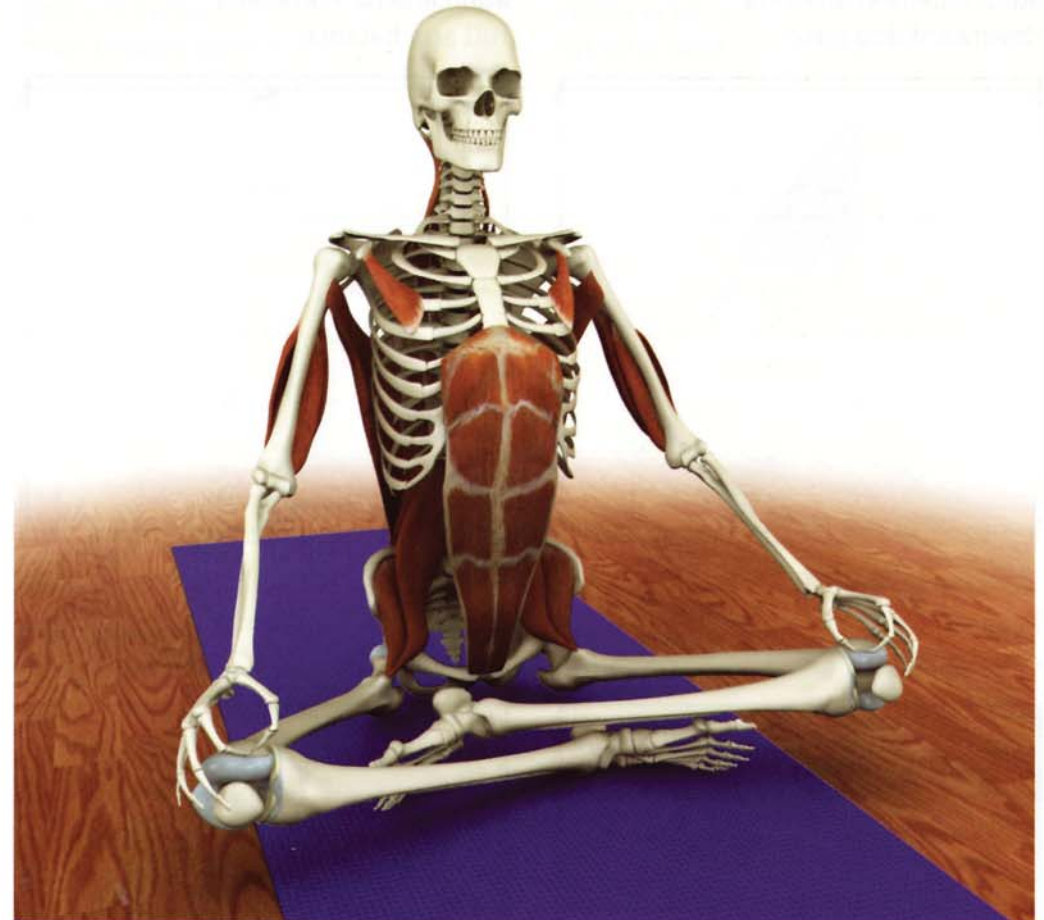


3) Draw the scapulae towards the midline by contracting the rhomboids. This action opens the chest. Balance this by closed chain contraction of the pectoralis minor to lift the ribcage.

Optimizing Siddhasana



4) Contract the latissimus dorsi to further open the chest. Lift the spine by gently contracting the triceps, pressing the hands into the knees.



5) Complete and balance the pose by adding the rectus abdominus to activate udyana bandha.


Appendix of Asanas

Optimizing 2DibbArbna

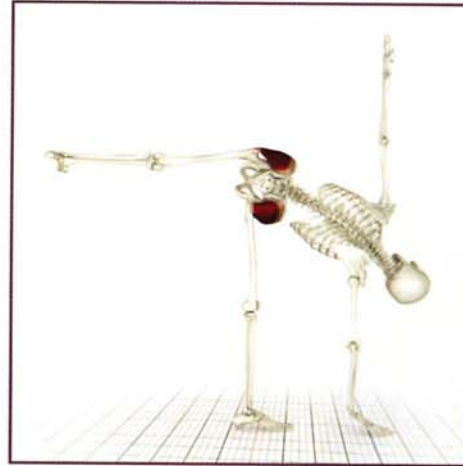
adho mukha svanasana
downward dog pose



adho mukha vrksasana
full arm balance



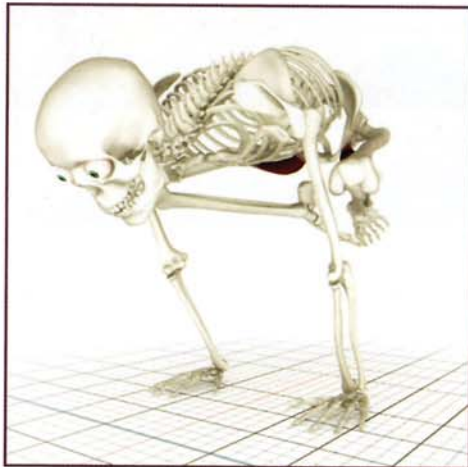
ardhachandrasana
half moon pose



baddhakonasana
bound angle pose




bakasana
crane pose




chaturanga dandasana
four limb staff pose



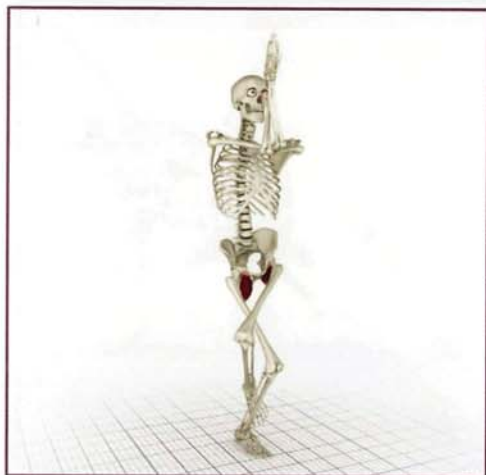dhanurasana
bow pose



eka pada viparita dandasana
one legged inverted staff pose



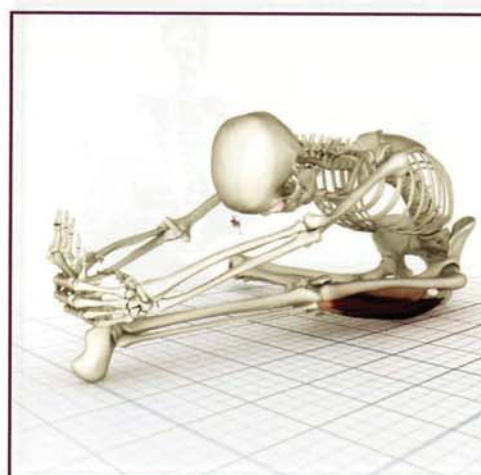
garudasana
eagle pose




gomukhasana B
cows face pose




janu sirsasana
head to knee pose



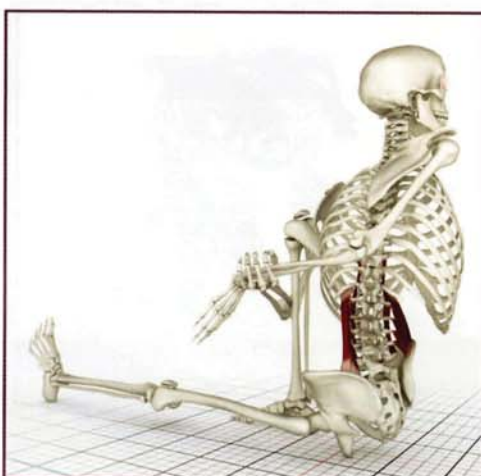kurmasana
tortoise pose



marichyasana I
sage pose



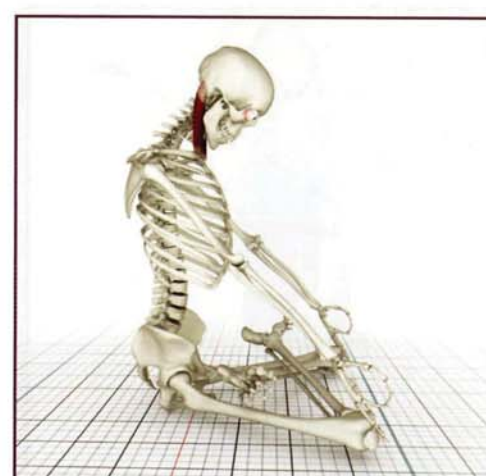
marichyasana III
sage pose



navasana
boat pose

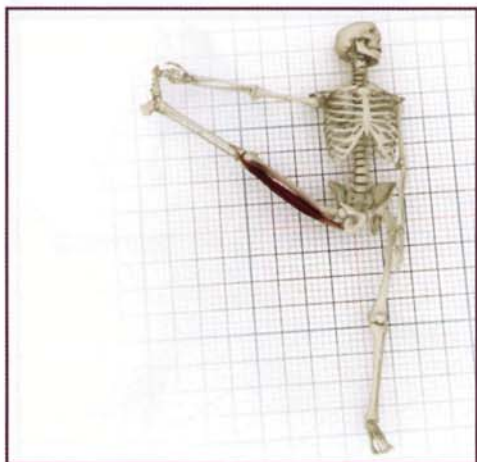


padmasana
lotus pose

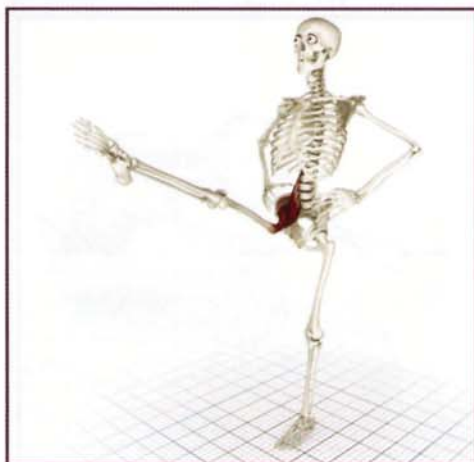

Appendix of Asanas

padangustasana
sleeping great toe in hand pose



padangustasana
great toe pose



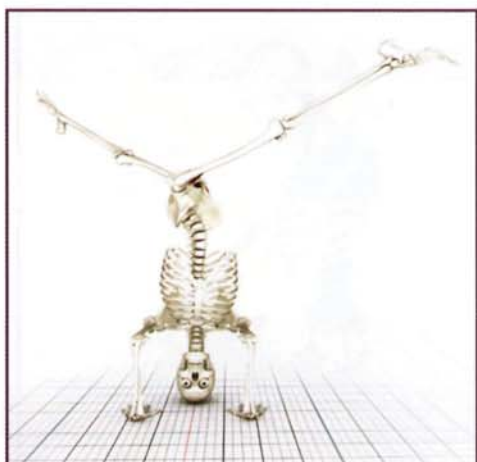parivrtta trikonasana
revolved triangle pose



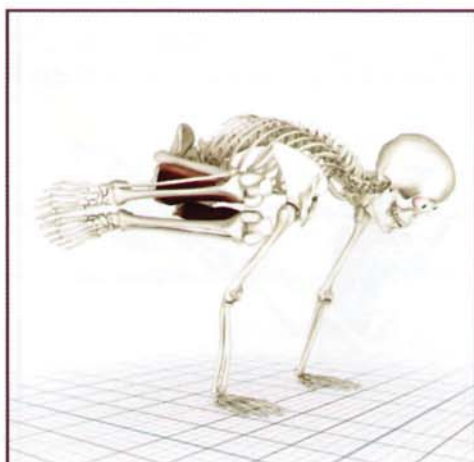
parivrtta parsvokonasana
revolved side angled pose



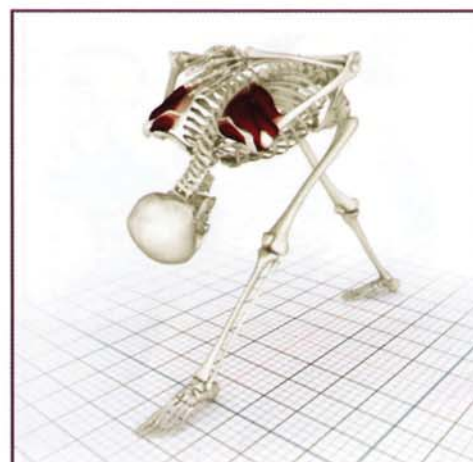parivrttaikapada sirasana
revolved head stand pose



parsva bakasana
revolved crane pose



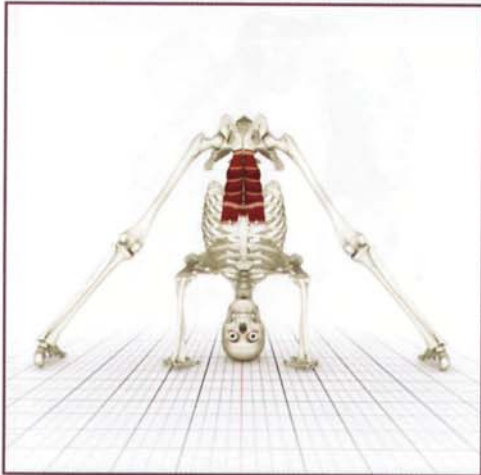
parsvottanasana
intense side stretch pose



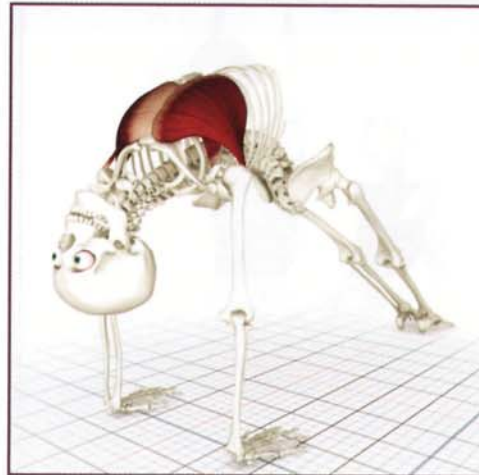paschimottanasana
intense stretch to the west pose




prasarita padottanasana
wide feet intense stretch pose



purvottanasana
intense stretch to the east pose



salabhasana
locust



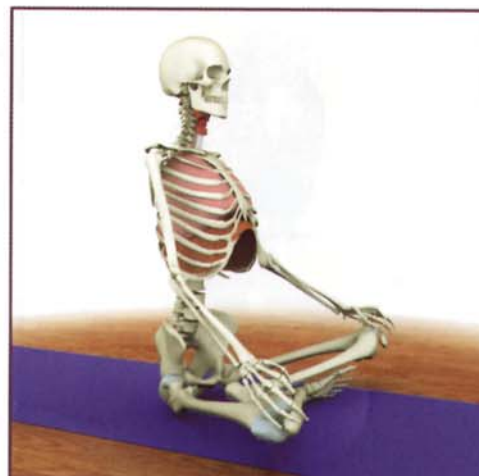
sarvangasana
shoulder stand



setubandha
bridge pose



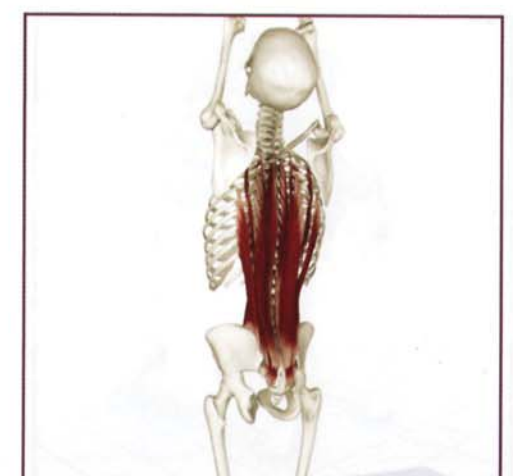siddhasana
the seer pose



supta padangusthasana B
lying great toe in hand pose

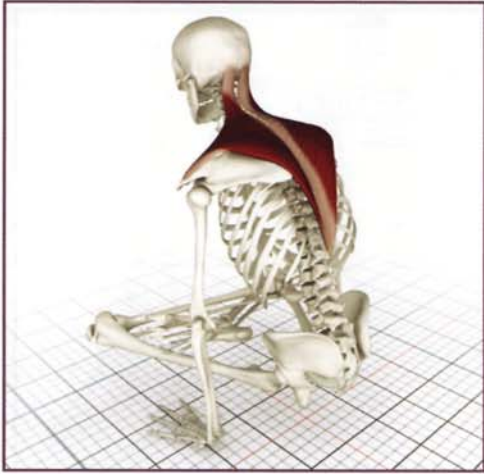

tadasana
mountain pose

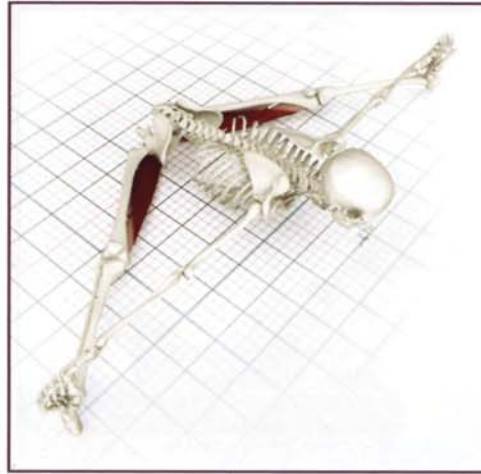


Appendix of Asanas

tolasana
scale pose



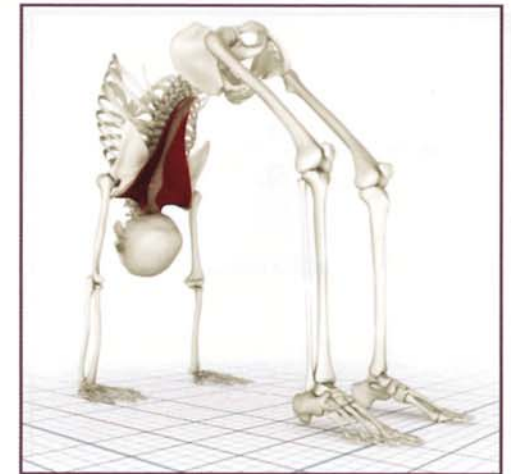
upavistha konasana
front splits



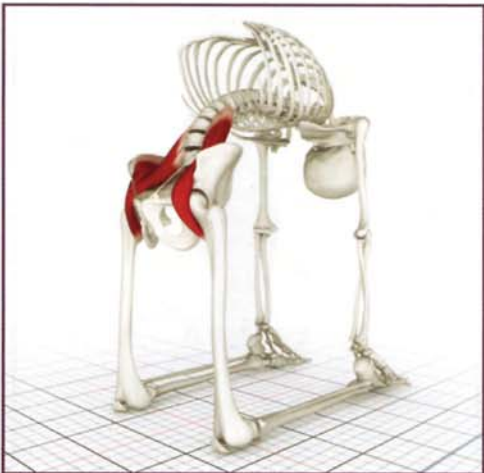
urdhva mukha svanasana
upward facing dog pose




urdhvadhanurasana
backbend



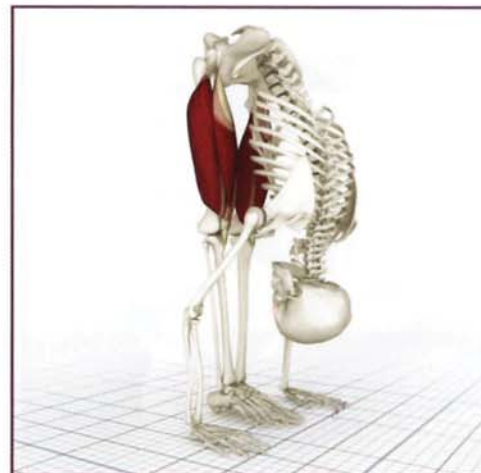ushtrasana
camel pose



utkatasana
fierce pose



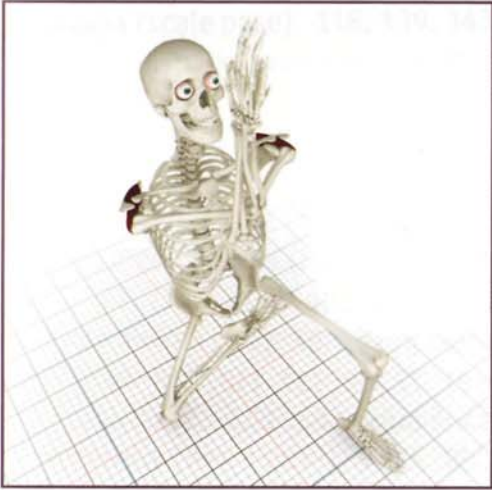utthanasana
standing forward bend



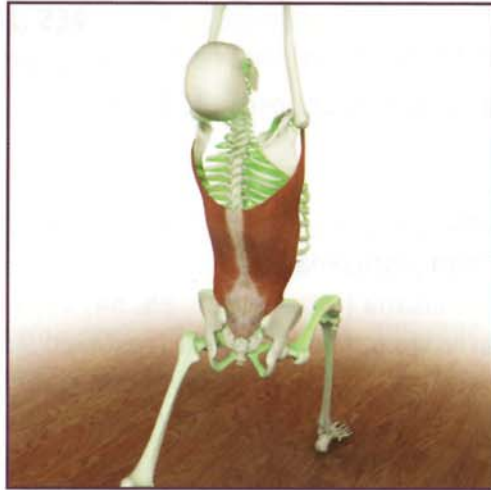utthita trikonasana
triangle pose



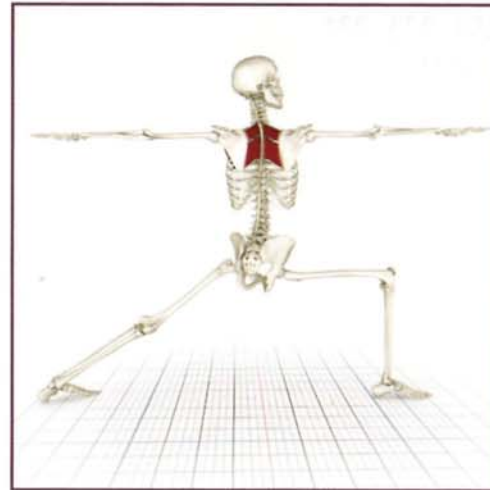
vatayanasana
horse face pose



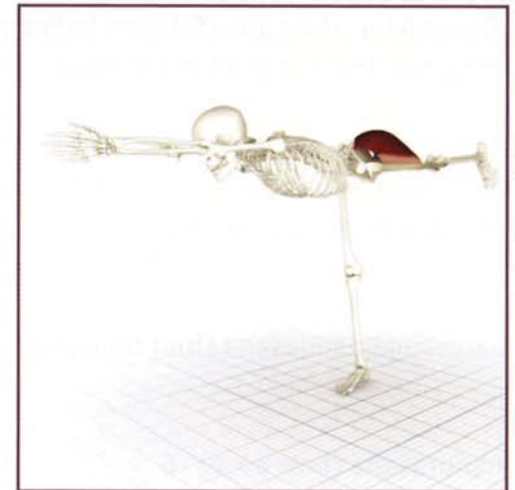virabhadrasana I
warrior I



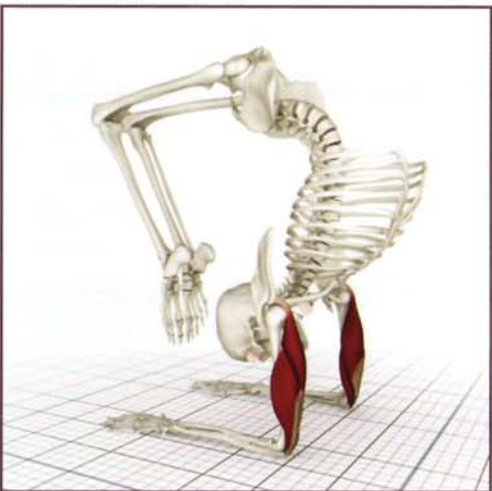
virabhadrasana II
warrior II




virabhadrasana III
warrior III



vrishchikasana
scorpion pose



vrksasana
tree pose



Index of Asanas

A

adho mukha svanasana (downward facing dog pose) 9, 107, 135, 138, 144, 175, 190, 226, 227, 231

adho mukha vrksasana (full arm balance) 154, 173, 231

ardhachandrasana (half moon pose) 72, 78, 231

B

baddhakonasana (bound angle pose) 79, 82, 83, 87, 90, 94, 231

bakasana (crane pose) 83, 84, 231

C

chaturanga dandasana (four limb staff pose) 144, 148, 153, 162, 165, 231

D

dhanurasana (bow pose) 6

E

eka pada viparita dandasana (one legged inverted staff pose) 18, 61

G

garudasana (eagle pose) 54, 56, 157, 167, 175, 231

gomukhasana B (cows face pose) 79, 139, 144, 149, 156, 181, 193, 231

J

janu sirsasana (head to knee pose) 72, 102, 232

K

krounchasana (heron pose) 109

kurmasana (tortoise pose) 128, 232

M

marichyasana (sage pose) 18, 20,

marichyasana I (sage pose) 108, 110, 111, 160, 232

marichyasana III (sage pose) 53, 95, 103, 107, 111, 132, 232

marichyasana IV (sage pose) 72

N

navasana (boat pose) 123, 232

P

padangustasana (great toe pose) 67, 232

padangustasana D 62

padmasana (lotus pose) 25, 54, 69, 74, 78, 94, 102, 200, 232

parivrtta parsvokonasana (revolved side angled pose) 87, 233

parivrtta trikonasana (revolved triangle pose) 72, 82, 117, 119, 233

parivrttaikapada sirasana (revolved head stand pose) 82, 233

parsva bakasana (revolved crane pose) 87, 88, 233

parsvottonasana (intense side stretch pose) 77, 82, 156, 174, 175, 233

paschimottanasana (intense stretch to the west pose) 42, 116, 188, 205, 233

pincha mayurasana (feather pose) 193

prasarita padottanasana (wide feet intense stretch pose) 123, 127, 233

purvottanasana (intense stretch to the east pose) 68, 118, 133, 148, 155, 167, 172, 185, 188, 197, 201, 204, 233

S

salabhasana (locust) 21

sarvangasana (shoulder stand) 185, 189, 204, 234

setubandha (bridge pose) 42

siddhasana (the seer pose) 12, 90, 102, 126, 215, 216, 228, 229

supta padangusthasana B (lying great toe in hand pose) 53, 95, 108, 234

T
tadasana (mountain pose) 9, 19, 128, 132, 155, 215, 219, 234
tolasana (scale pose) 118, 139, 143, 154, 234
trianga mukhaikapada paschimottanasana (three limbed face to extended leg pose) 21, 100

U
upavistha konasana (front splits) 87, 88, 234
urdhavadhanurasana (backbend) 55, 73, 77, 84, 99, 116, 118, 128, 135, 143, 144, 167, 174, 175, 194, 234
urdhva mukha svanasana (upward facing dog pose) 135, 138, 144, 175, 194, 211, 234
ushtrasana (camel pose) 63, 67, 234
utkatasana (fierce pose) 9, 27, 112, 220
utthanasana (standing forward bend) 12, 27, 55, 64, 68, 100, 118, 128, 215, 235
utthita hasta padangusthasana (extended hand to big toe pose) 52
utthita trikonasana (triangle pose) 46, 63, 99, 117, 124, 128, 161, 166, 197, 201, 204, 235

V
vatayanasana (horse face pose) 73, 156, 173, 182, 235
virabhadrasana I (warrior I) 135, 136, 167
virabhadrasana II (warrior II) 11, 45, 47, 60, 62, 67, 153, 155, 160, 172, 175, 182, 215, 235
virabhadrasana III (warrior III) 67, 103, 235
vrishchikasana (scorpion pose) 52, 193, 235
vrksasana (tree pose) 39, 102, 139

Index of Muscles

A
abdominals (see also transversus abdominis, internal and external oblique, rectus abdominus) 118-126,
 (as antagonists) 131
 (as synergists) 122
abductor digiti minimi 202
abductor pollicis 208
adductor group (see also pectineus, adductor brevis, adductor longus, adductor magnus, gracilis) 68, 79, 84, 88, 89-90
 (as antagonist) 71, 76, 93
 (as synergist) 81, 86, 93
adductor brevis 79, 89
adductor longus...51, 79, 89
adductor magnus 84-88, 89
 (as synergist) 66, 84

B
biceps brachii 31, 38, 152, 172, 185-189, 209, 225
 (as antagonist) 42, 137, 146, 171, 192
 (as synergist) 170, 180, 185
biceps femoris 51, 103-105, 107, 111
 (as synergist) 66, 126, 127
brachialis 185, 189
 (as synergist) 185

C
capitis (see semispinalis)
cervicis (see semispinalis)
coracobrachialis 152

D
deltoids (posterior, lateral, anterior) 47, 152, 167-173, 175, 182, 183, 188
 (as antagonist) 137, 146, 167, 169, 171, 178, 179, 187, 192
 (as synergist) 127, 137, 142, 178, 179, 180, 187, 192
diaphragm 213, 217

E
erector spinae (see also spinalis, longissimus and iliocostalis) 65, 115, 128-129, 132-133, 217
 (as agonist) 135
 (as antagonist) 122, 127
extensor carpi radialis brevis 206
extensor carpi radialis longus 206
extensor digiti minimi 206, 208
extensor digitorum 206, 208
extensor digitorum longus 202
extensor hallucis longus 202
extensor pollicis longus 206, 208
external oblique 113, 118-120, 122, 124,
 (as antagonist) 122
 (as synergist) 122
external rotators 94, 95

F
flexor carpi radialis 206
flexor carpi ulnaris 206
flexor digitorum longus 203
flexor digitorum profundus 206, 208
flexor digitorum superficialis 206, 208
flexor hallucis brevis 203
flexor hallucis longus 203

G

- gamelli 91
- gamellus 50
- gastrocnemius 51, 105, 203, 205
 - (as antagonist) 98, 127
 - (as synergist) 106, 205
- gluteus maximus 43, 51, 63, 64-70, 73, 74, 84, 87, 103, 105
 - (as antagonist) 59, 60, 61, 76
 - (as synergist) 76, 106, 133
- gluteus medius...39, 43, 51, 68, 69-74, 95
 - (as antagonist) 81, 86, 93
 - (as synergist) 76, 93
- gluteus minimis 69, 70
 - (as antagonist) 81, 86, 93
 - (as synergist) 71, 93
- gracilis (see also adductor group) 51, 89, 98, 103
 - (as antagonist) 106

H

- hamstrings (see also biceps femoris, semitendinosus, semimembranosus) 42, 63, 96, 101, 103-111, 128, 188, 194, 224, 226, 227
 - (as agonist) 36
 - (as antagonist) 36, 59, 60, 61, 76, 98, 100, 127
 - (as synergist) 126, 205

I

- iliacus (see iliopsoas)
- iliocostalis 114, 128-129
- iliopsoas 38, 39, 42, 47, 51, 57-63, 64, 82, 91, 109, 123, 128, 133, 220, 224, 225, 226, 227
 - (as antagonist) 42, 66, 106
 - (as synergist) 76, 81, 98, 127

- infraspinalis 31, 151, 152, 174, 175, 176-177, 179, 181, 184
 - (as antagonist) 146, 174, 178
- intercostals 113, 218, 219
- internal oblique 113, 118-120, 122, 124,
 - (as antagonist) 122
 - (as synergist) 122

L

- latissimus dorsi 38, 115, 135-138, 173, 217
 - (as antagonist) 141, 169, 170, 179, 180
 - (as synergist) 126, 131, 142, 146, 147, 171, 178, 192
- levator scapulae 115, 152, 157
 - (as synergist) 159
- longissimus cervicis 114, 128,
- longus capitus
 - (as synergist) 199
- longus colli
 - (as synergist) 199

M

- multifidis 114

O

- obturator externis 50, 91
- obturator internis 50, 91

P

- palmar arch 208
- palmaris longus 208
- pectineus 51, 79-83, 89
 - (as antagonist) 66
 - (as synergist) 59, 60, 61

Index of Muscles

pectoralis major 113, 133, 138, 144-149, 172, 173, 182
(as antagonist) 137, 141, 159, 169, 170, 171, 179, 180
(as synergist) 137, 142, 164, 169, 178, 187
pectoralis minor 113, 144-149, 157, 185, 216, 217, 219
(as antagonist) 141
(as synergist) 142, 164
peroneus brevis 202
peroneus longus 202
piriformis 50, 91-95
(as antagonist) 81, 86
(as synergist) 71
pronator quadratus 208, 209
pronator teres 206, 208, 209
psoas, psoas major (see iliopsoas)

Q
quadratus femoris 50, 91-95
(as antagonist) 71
(as synergist) 81, 86, 91
quadratus lumborum 39, 128, 130, 132, 217, 219
(as antagonist) 122
(as synergist) 66
quadriceps (see also rectus femoris, vastus intermedius, vastus medialis, vastus lateralis) 51, 63, 96-101, 123, 225, 227
(as agonist) 36
(as antagonist) 36, 42, 106
(as synergist) 76, 127, 133

R
rectus abdominis 38, 113, 118, 119, 120, 123, 128, 133, 217, 218, 219, 221, 225
(as synergist) 127

rectus femoris (see also quadriceps) 39, 51, 63, 96, 97, 99, 100, 133
(as antagonist) 66
(as synergist) 59, 60, 61
rhomboid major 152, 157-158
(as antagonist) 141, 157, 164
(as synergist) 142, 147
rhomboid minor 152, 157-158
(as antagonist) 141, 157, 164
(as synergist) 142, 147
rhomboids 115, 144, 149, 157-161, 166, 217, 219
rotator cuff (see also subscapularis, supraspinatus, infraspinatus, teres minor, teres major) 31, 151, 172, 174-182, 184, 190

S
sartorius 39, 51, 102, 103,
(as antagonist) 98
(as synergist) 59, 60, 61, 106
semimembranosus 51, 103-105, 108, 111
(as synergist) 66
semispinalis 114
semitendonosus 38, 51, 103-105, 108, 111
(as synergist) 66
serratus anterior 148, 152, 157, 161, 162-166,
(as antagonist) 159
serratus posterior 115
spinalis 32, 128-129
splenius capitis 114
splenius cervicis 114
soleus 203
sternocleidomastoid 38, 197-201, 217
(as antagonist) 141, 147
(as synergist) 126, 142

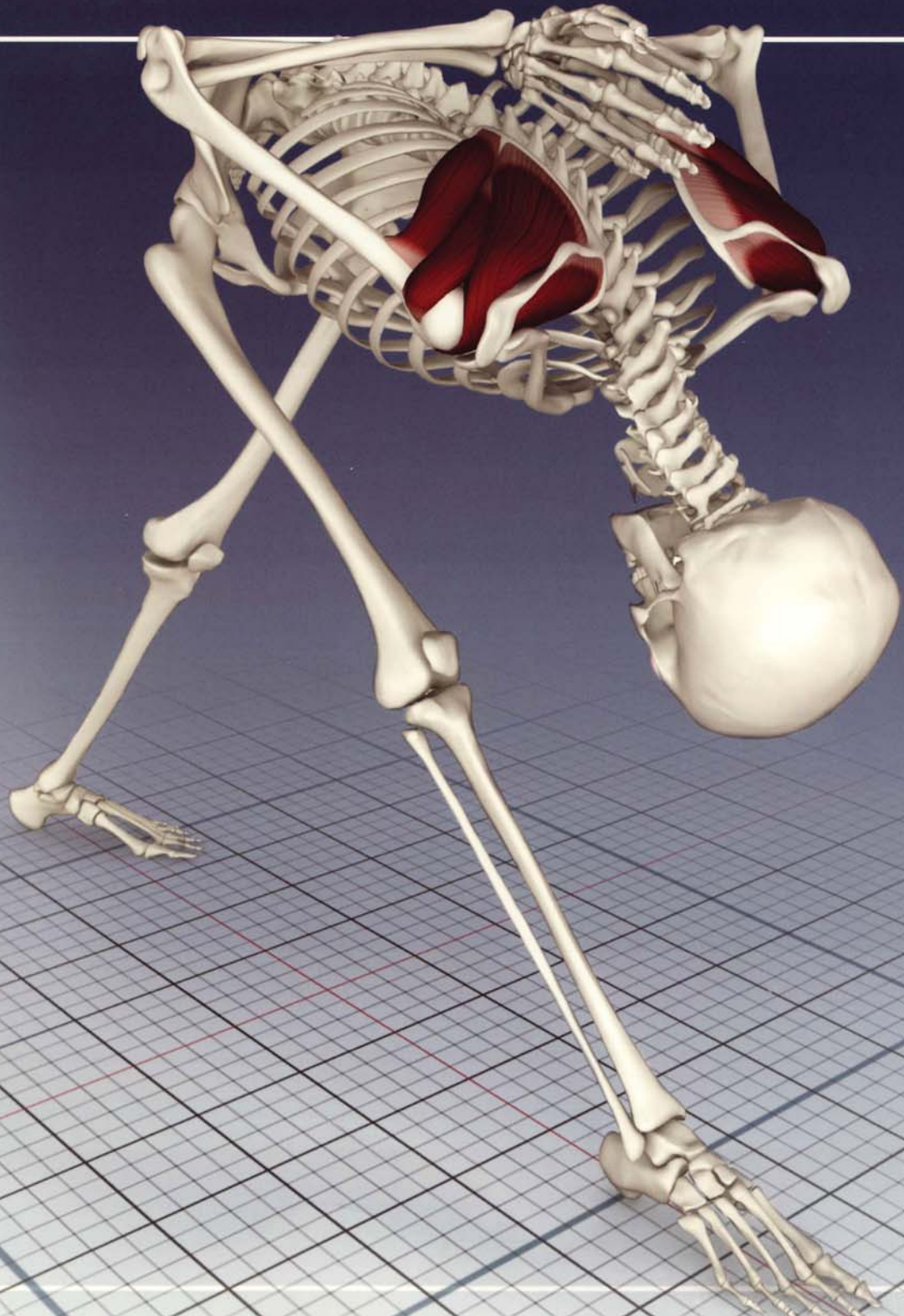subscapularis 31, 151, 152, 174-178, 181
(as antagonist) 174, 179
supinator 208, 209
supraspinatus 31, 151, 152, 172, 174-175, 177, 180, 182, 183
(as antagonist) 146
(as synergist) 170

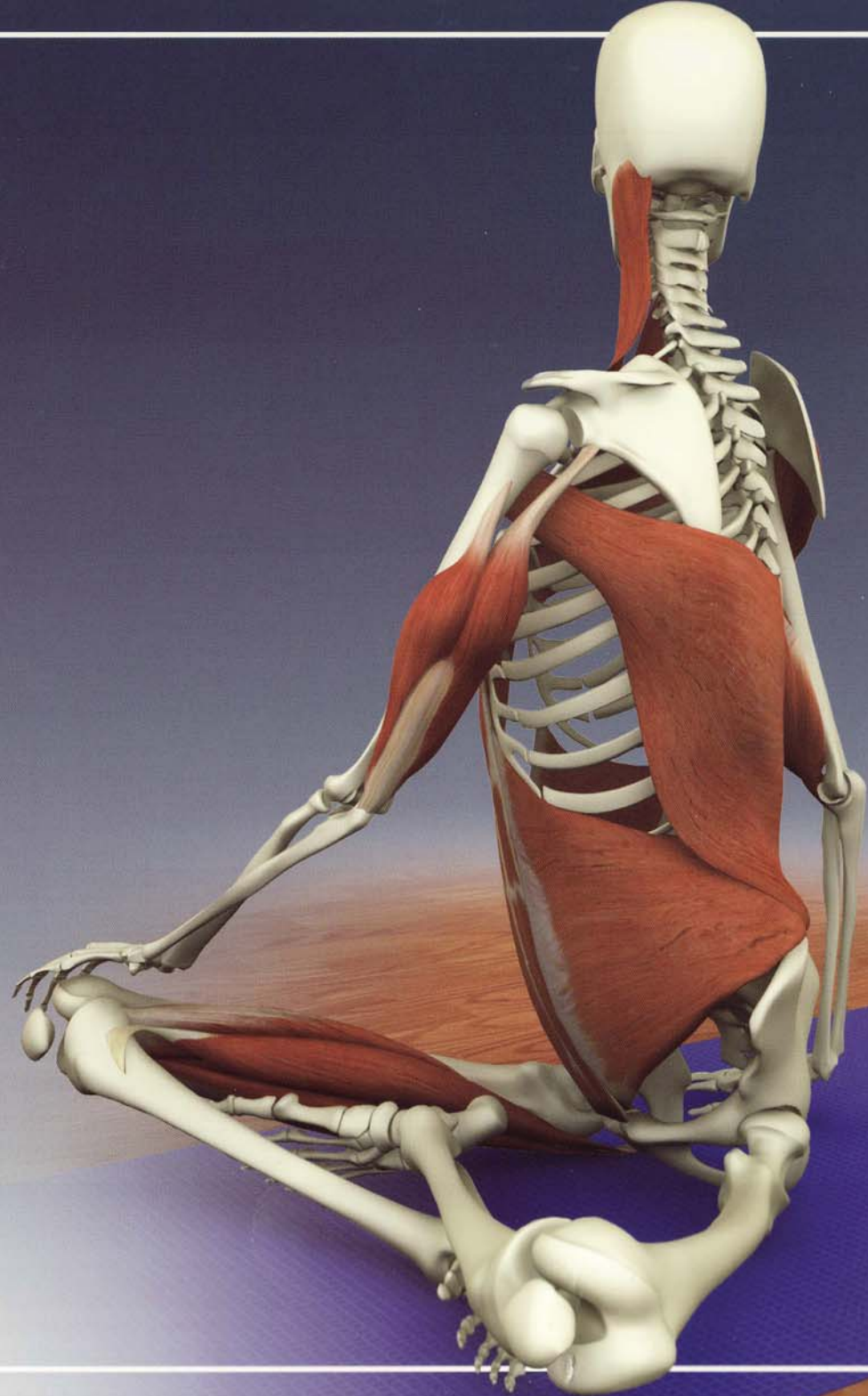
T

tensor fascia lata 43, 51, 68, 74-78, 95
(as antagonist) 81, 86, 93
(as synergist) 59, 60, 61, 71, 93, 98
teres major 151, 152
teres minor 151, 152, 174
(as antagonist) 178
(as synergist) 174, 179
thoracis (see semispinalis)
tibialis anterior 202
tibialis posterior 203
transversalis 32, 38, 129
transversus abdominis 118-119, 121, 218, 219, 221
trapezius 115, 139-143, 173, 175, 183, 201
(as antagonist) 141, 147, 159, 164, 199
(as synergist) 131, 159
triceps brachii 31, 133, 152, 184, 188, 190-194, 225, 227
(as antagonist) 170, 180, 187
(as synergist) 126, 133, 137, 146, 171

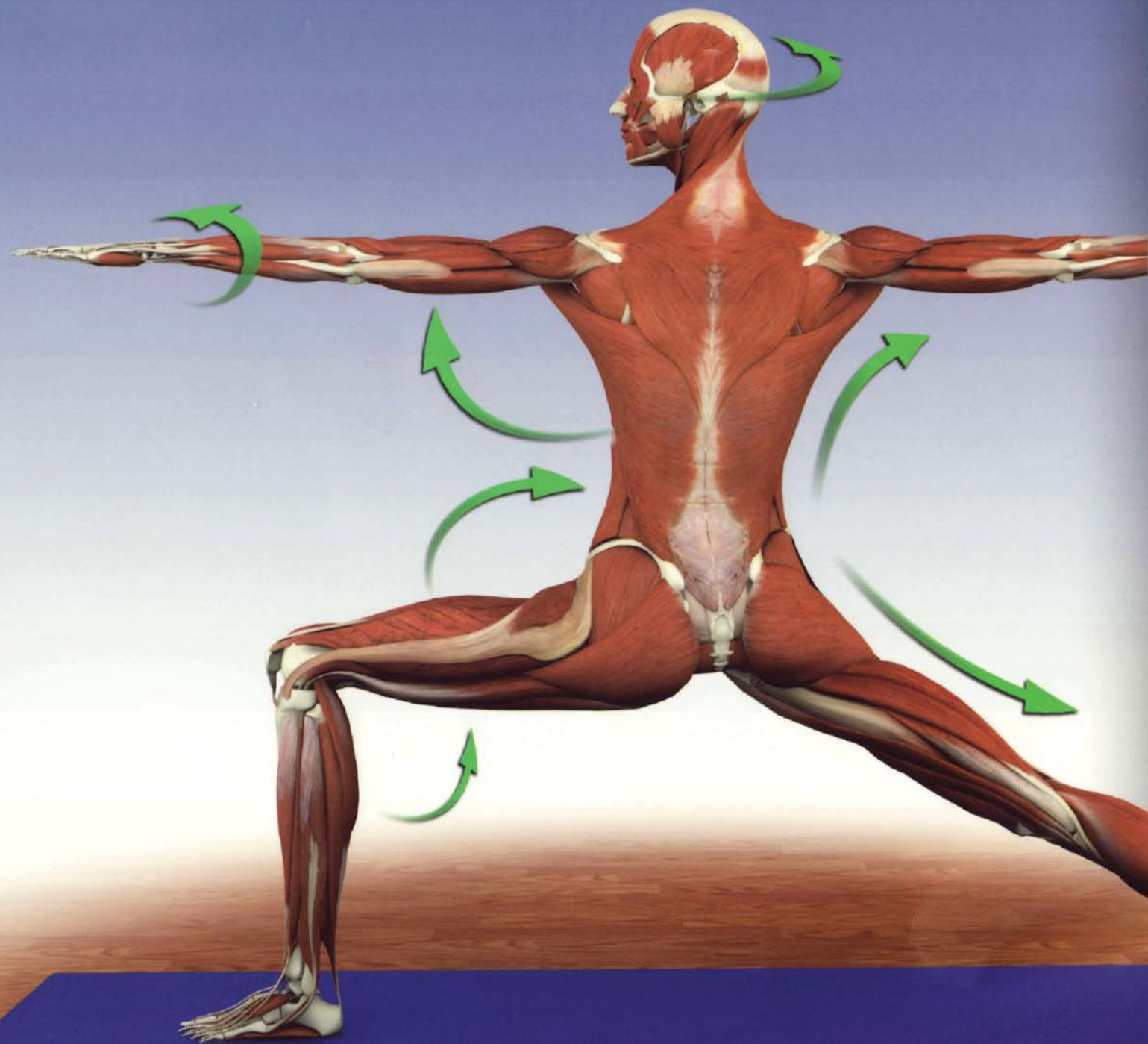
V

vastus intermedius (see also quadriceps) 96-97, 99, 100
vastus lateralis (see also quadriceps) 96-97, 99, 100
vastus medialis (see also quadriceps) 96-97, 99, 100





Scientific Keys Volume I



The Key Muscles of Hatha Yoga

Ray Long MD FRCSC

With Illustrator Chris Macivor

www.BandhaYoga.com

ISBN 0-9779614-1-9



9 780977 961412